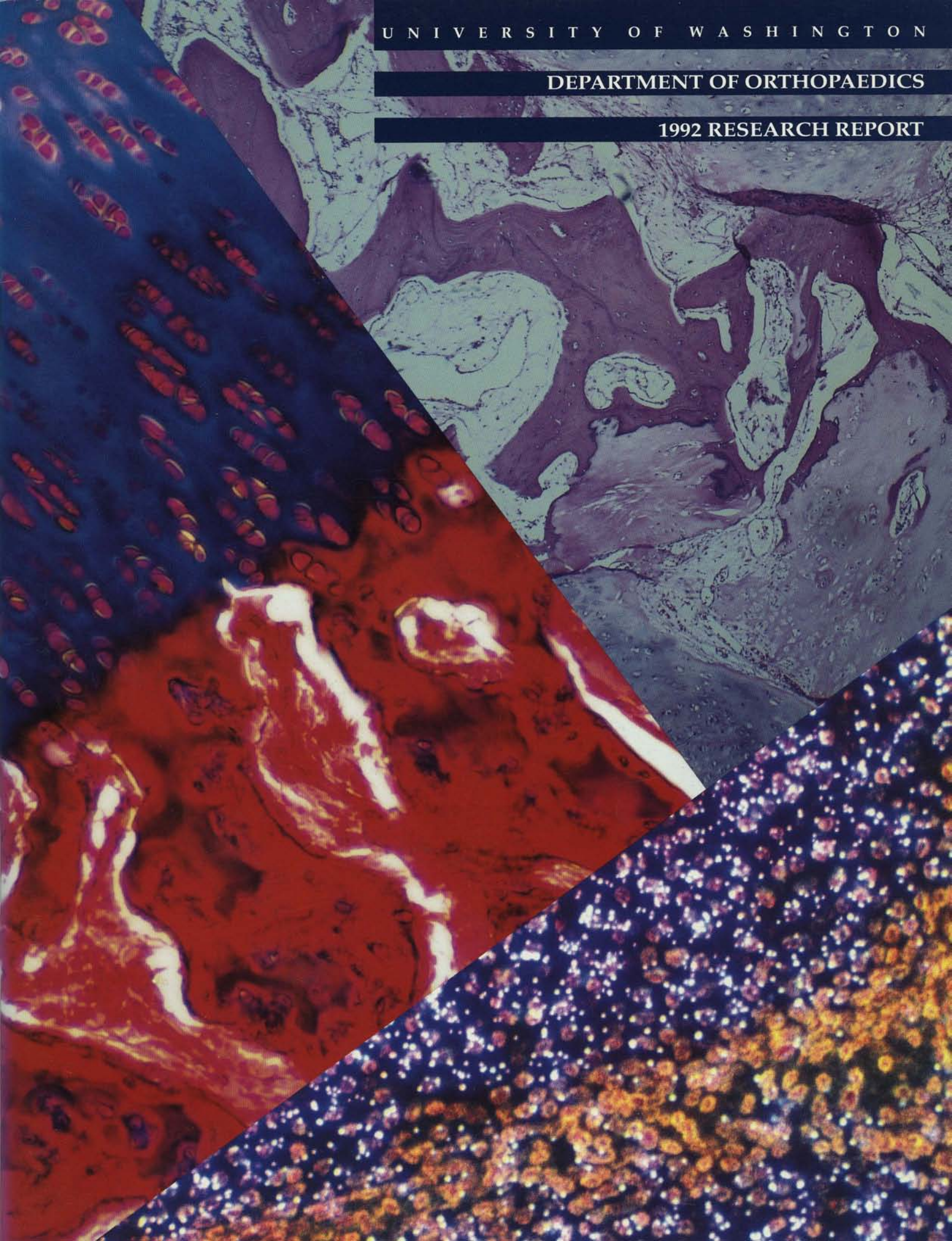


UNIVERSITY OF WASHINGTON

DEPARTMENT OF ORTHOPAEDICS

1992 RESEARCH REPORT



1992 Research Report

Department of Orthopaedics

UNIVERSITY OF WASHINGTON



**Department
of Orthopaedics**
University of Washington
Seattle, Washington 98195

Editor:	Frederick A. Matsen III, M.D.
Managing Editor:	Sandra L. Marvinney
Editorial Assistant:	Cindi Robinson
Design:	Arlys Ramsey

COVER ILLUSTRATION: The photo in the upper left by Dr. John Clark shows normal articular cartilage from the patella stained with Masson's trichrome. The upper right photo by Dr. Chappie Conrad is an example of the cartilage-bone interface of a benign exostosis. The lower right photo by Dr. Linda Sandell illustrates in situ hybridization of type IIB N-propetide mRNA from a section of human fetal hand.

Contents

Foreword	1
Study of a Collagen Gene Reveals a New Step in Musculoskeletal Development — 1992 Kappa Delta Award <i>Linda J. Sandell, Ph.D., James Sugai, M.S., Mary B. Goldring, Ph.D., James Robbins, B.S., Stephen Trippel, M.D.</i>	2
Calcaneal Neck Lengthening for Severe Abducto-Valgus (Flat) Hindfoot Deformities in Children <i>Vincent S. Mosca, M.D.</i>	5
“Metaphyseal” Cysts in Legg-Calvé-Perthes Disease <i>Scott A. Hoffinger, M.D., George T. Rab, M.D., Peter B. Salamon, M.D.</i>	8
Prognostic Factors in Infantile Tibia Vara <i>Mark C. Dales, M.D., Charles E. Johnston, M.D., Randall L. Loder, M.D.</i>	10
The Hamstrings in Cerebral Palsy Crouch Gait: Gait Laboratory Analysis <i>Scott A. Hoffinger, M.D., George T. Rab, M.D., Hassan Abou-Ghaida, M.S.</i>	12
The Role of the Shelf Procedure in Managing Acetabular Dysplasia <i>Lynn T. Staheli, M.D.</i>	14
The Investigation of Multiple Hereditary Exostoses <i>Ernest U. Conrad III, M.D., Wendy H. Raskind, M.D., Ph.D., Greg Schmalle, M.Ed.</i>	16
Stress Fractures in Professional Ballet Dancers <i>Carol C. Teitz, M.D., Nancy J. Kadel, M.D., Richard A. Kronmal, Ph.D.</i>	18
Factors Influencing Pullout Strength of Bone Screws in Porous Materials <i>Jens R. Chapman, M.D., Richard M. Harrington, M.S., Kevin Lee, M.D., Paul A. Anderson, M.D., Allan F. Tencer, Ph.D.</i>	20
New Techniques in Fracture Stabilization <i>M.L. (Chip) Routt Jr., M.D., Peter Simonian, M.D., Richard Harrington, M.S., David Senft, B.S., Allan F. Tencer, Ph.D., Keith A. Mayo, M.D.</i>	22
Intramedullary Reaming: Changes Over 25 years <i>Sigvard T. Hansen Jr., M.D.</i>	24
The Epidemiology of Seatbelt-Associated Injuries <i>Paul A. Anderson, M.D.</i>	26
Residual Motion After Glenohumeral or Scapulothoracic Arthrodesis <i>Eric David Walker, B.S., Douglas T. Harryman II, M.D.</i>	28
Glenohumeral Stability from Concavity-Compression: A Quantitative Analysis <i>Steven B. Lippitt, M.D., J. Eric Vanderhooft, M.D., Scott L. Harris, B.S., John A. Sidles, Ph.D., Douglas T. Harryman II, M.D., Frederick A. Matsen III, M.D.</i>	30

Special Reprint from Science News

- Ringling to a Single Proton's Magnetic Nudge 33
Highlighting Research of John A. Sidles, Ph.D.
-

Resident Abstracts

- Surgical Treatment of Upper Extremity Deformities in Arthrogryposis 34
Curtis W. Rodin, M.D., Allan W. Bach, M.D.
-

- Histiocytosis X: A Spectrum of Disease 34
Michael J. Sailer, M.D., Ernest U. Conrad III, M.D.
-

- Diagnostic Hip Arthrocentesis in Children: The Significance of a Dry Tap 35
John D. West, M.D., Mark C. Dales, M.D.
-

- Posterior Dislocation of the Insall Burstein Posterior Stabilized II Total Knee Prosthesis 35
Donald B. Striplin, M.D., Raymond P. Robinson, M.D.
-

- A Prospective Study Evaluating Core Decompression for Early Osteonecrosis of the Hip in a High-Risk Group of Patients 36
Elisha T. Powell IV, M.D., William L. Lanzer, M.D., Martin G. Mankey, M.D.
-

- Deep Vein Thrombosis (DVT) Prophylaxis in Orthopaedic Trauma Patients 36
Jeffrey L. Stickney, M.D.
-

Department of Orthopaedics Faculty

Inside Back Cover

Foreword

It gives me great pleasure to present the 1992 Department of Orthopaedics Research Report.

This year, our cover features three faces of cartilage. The photo in the upper left corner, courtesy of John Clark, shows the normal developing cartilage of the growth plate. The upper right photo illustrates poorly behaved cartilage in a chondrosarcoma, courtesy of Chappie Conrad. An example of Linda Sandell's *in situ* hybridization technique is illustrated in the photograph of procollagen type IIB in the lower third.

In this issue we highlight and honor the work of Dr. Sandell and her investigative team, who received the American Academy of Orthopaedic Surgeons' highest award for orthopaedic research, the Kappa Delta Award, for their study of cartilage collagen genes and musculoskeletal development.

Research such as Dr. Sandell's will help us understand what causes cartilage cells to turn on and turn off their synthesis of cartilage and to behave or misbehave. She determined that the type II procollagen gene can be differentially expressed in two isoforms generated by alternative splicing of the pre-mRNA. Her work was unique in that it combined the techniques of histochemistry and molecular biology by using hybridization of DNA molecules to cellular mRNAs *in situ*.

The quality of the Department's research program is reflected not only in Kappa Delta Awards received by Dr. Sandell and her team in 1992, and by Dr. Stan Bigos and his team in 1991, but also in the receipt of federal grant dollars. Competition for these dollars is extremely high, yet in 1991 our Department was second among all orthopaedic departments nationwide in NIH extramural awards. We owe this success to the efforts of such principal investigators as David Eyre, Linda Sandell, Stan Bigos, and Michelle Battié.

Our commitment to research also involves our medical students. Brad Henley, Scott Hoffinger, John Clark, David Eyre, Chappie Conrad, and Allan Tencer are all actively involved in the Medical Student Research Training Program, helping students with projects as diverse as analysis of walker use in children with cerebral palsy, the effects of steroid use on bone resorption, and evaluation of major histocompatibility antigens for osteochondral allografts.

Our Resident Research Program is progressing well under the supervision of Bruce Sangeorzan. This report proudly presents the abstracts of our six graduating residents. An increasing number of our residents are participating in the American Orthopaedic Association's Resident Research Conference. Lyle Sorenson, Susan Schmitt, Phil Kregor, and Eric Vanderhooft presented at this year's meeting in Ann Arbor, Michigan. In 1993 we will be honored to have the program hosted in Seattle, with Drs. Kregor and Sorenson serving as the resident coordinators.

This year, our Resident Research Days, June 12 and 13, feature Joseph Buckwalter, professor of orthopaedic surgery at the University of Iowa and past president of the

Orthopaedic Research Society. Dr. Buckwalter is just returning from England where he was the international visiting professor at the Nuffield Orthopaedic Center at Oxford University. He will critique the residents' research presentations and will deliver a guest lecture entitled "Growth: Do Plants and Animals Use the Same Mechanism?"

This 1992 report presents only a sample of the spectrum of research in progress in the Department of Orthopaedics. We have included a series of excellent papers from our pediatric orthopaedic faculty, as well as papers on trauma and adult orthopaedics. It is through these investigations that we strive to carry out one of our primary missions: "to make important contributions to the body of knowledge on which the practice of orthopaedics is based."



Frederick A. Matsen III, M.D.
Professor and Chairman

Study of a Collagen Gene Reveals a New Step in Musculoskeletal Development

Linda J. Sandell, Ph.D.
James Sugai, M.S.
Mary B. Goldring, Ph.D.
James Robbins, B.S.
Stephen Trippel, M.D.

The techniques of molecular biology provide powerful tools for exploring the mechanisms of musculoskeletal development, growth, and repair. Our laboratory has a particular interest in the molecular biology of cartilage. Using these techniques, we hope to gain insight into the basic processes of development, growth, and repair that may help us understand the normal state as well as disease processes and possible mechanisms of treatment.

Predominant macromolecules in the extracellular matrix of cartilage are type II collagen and proteoglycans. These molecules are synthesized by chondrocytes, the cells resident in cartilage. Our laboratory has concentrated its studies on the mechanisms by which chondrocytes control synthesis of cartilage matrix molecules. Since the control of synthesis occurs at the DNA (gene)

level, we have been particularly interested in the type II collagen gene, which contains the DNA that "encodes" the protein sequence for type II collagen.

Unexpectedly, in the late 1970s, it was found that the code for genes was not linear but rather was interrupted by segments of "non-coding" or intervening DNA. The intervening DNA contained vital control elements responsible for deciding how much and when to make protein from the gene, in this case the type II collagen gene. The interspersed coding and non-coding DNA allows for the inclusion or exclusion of various segments in the resulting protein by the procedure of alternate splicing of coding domains. During our studies, we found that the type II collagen gene can be expressed in two forms arising from the use of two different type II procollagen messenger RNAs (Figure 1).

We hypothesized that the differential expression of type II procollagens may be a marker for distinct populations of skeletal cells. We used the technique of in situ hybridization of DNA "probes" to messenger RNA to localize specific procollagen messenger RNAs in tissue. This technique was applied to developing cartilage, growing cartilage, and tissues thought to be responsible for repair.

An embryonic vertebral column provided a source of tissue undergoing rapid cartilage development (chondrogenesis) and allowed examination of a variety of cell types related to cartilage. In this tissue, each collagen messenger RNA had a distinct tissue distribution: type IIB procollagen was expressed in



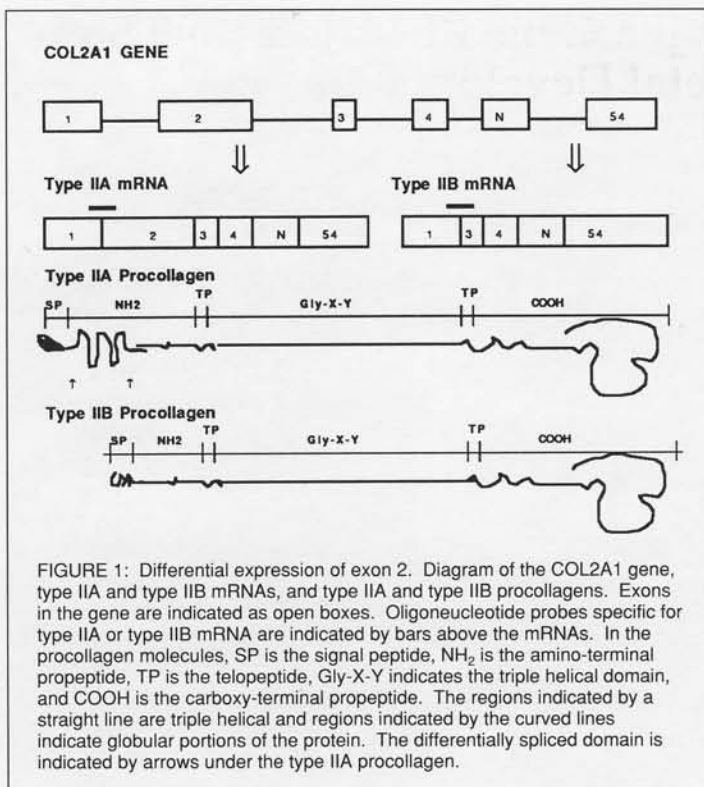
1992 Kappa Delta Award

For the second consecutive year, faculty members from our Department have won this most prestigious award in orthopaedics, presented by the American Academy of Orthopaedic Surgeons. This year the award went to Dr. Linda J. Sandell and her research team for their study of "Expression of Collagen and Aggrecan Genes During Skeletal Development and Growth: Control at Transcription and Posttranscription." Department investigators have now won the Kappa Delta Award five times.

chondrocytes and type IIA was expressed in prechondrocytes, the cells surrounding existing cartilage (Figure 2).

The morphology of the cells expressing the two collagen types was distinct: the cells expressing the type IIA are narrow, elongated, and "fibroblastic" in appearance, while the cells expressing type IIB are large and round. The expression of type IIB appears to be correlated with abundant synthesis and accumulation of cartilaginous extracellular matrix, and is spatially correlated with the high-level expression of cartilage proteoglycan. These observations established type IIB procollagen and proteoglycan as markers for the chondrocyte phenotype. These studies suggest that the conversion from the type IIA to type IIB collagen is a previously unrecognized step in the formation of cartilage: prechondrocytes make procollagen type IIA while mature chondrocytes make type IIB.

We next studied the expression of collagens during the growth of long bones to determine if the two type II collagen isoforms were present there as well. We studied



growth plate chondrocytes in situ with particular regard to the expression of type II procollagen messenger RNA as well as the expression of type I and type X collagens.

Here again, the expression of collagens was dependent on their stage of differentiation. All chondrocytes synthesized type IIB procollagen. In addition to type II procollagen, growth plate chondrocytes

initiated abundant synthesis of type X procollagen, even in the middle of the growth plate. Type X procollagen is generally considered characteristic of hypertrophic chondrocytes. After lysis of the hypertrophic chondrocytes, the cells that invaded and attached to the collagen matrix synthesized abundant type I procollagen, which is characteristic of bone. Consequently, unlike cartilage development, cartilage growth does not appear to require the expression of the two isoforms of type II procollagen in the growth plate. Instead, it requires abundant type IIB and type X collagen (Figure 3).

Finally, we examined the perichondrium and periosteum, again using hybridization to DNA probes. These tissues, which surround cartilage and bone, are thought to be important in development, growth, and repair. In these tissues, we found abundant expression of the new type IIA collagen. The expression of this collagen type provides a marker for the potential of those cells to become either cartilage or bone. This observation ties together the hypothesis that collagen type IIA is the precursor to cartilage.

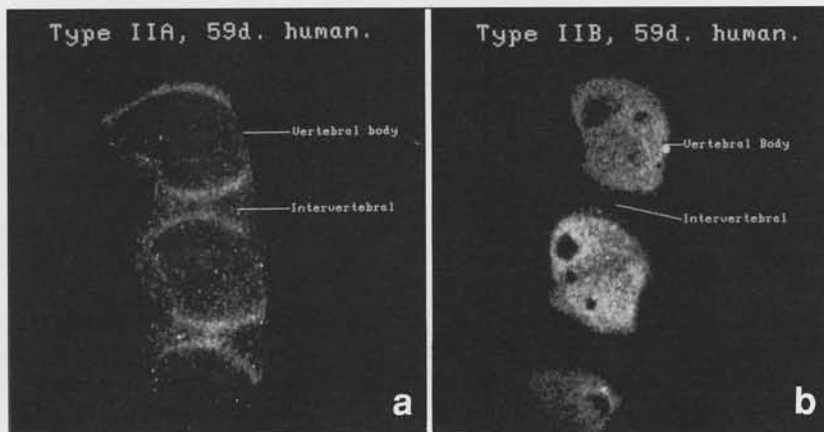


FIGURE 2: Tissue expression of type IIA and type IIB collagen mRNA in vertebral tissue observed by autoradiography of tissue sections. Mid-sagittal sections of vertebral column were hybridized with collagen-specific oligonucleotide probes: type IIA collagen (a) and type IIB (b). Autoradiographs were analyzed with the aid of an MCID Image Analysis System without contrast enhancement. Type IIA (a) surrounds the vertebral area while type IIB (b) is observed only within the centrum/vertebral body.

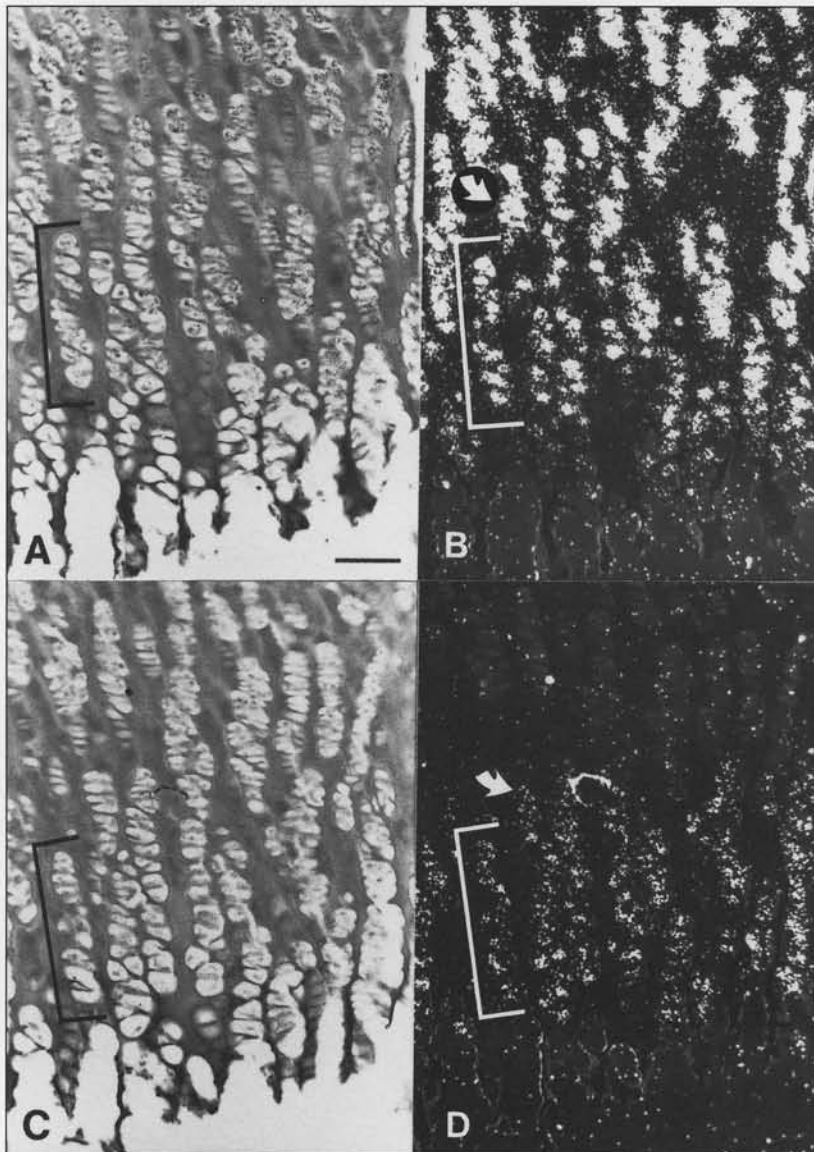


FIGURE 3: Sections of newborn epiphyseal growth plate showing cells aligned in vertical columns synthesizing high levels of mRNA. Type X mRNA (C,D) is localized in a subset of type II (A,B) collagen-synthesizing cells. Resting cartilage is located above the region shown and the chondro-osseous junction is at the bottom of the photograph. A and B are bright-field and dark-field photographs of a section hybridized to the type IIB procollagen probe. C and D are hybridized to the type X collagen mRNA probe. The same column is localized on each section (an example is indicated by the bracket). Within a column, individual cells can be resolved. The synthesis of type X collagen mRNA is initiated synchronously across the cell columns. In one column (indicated with curved arrow), the accumulation of type X mRNA can be observed in most of the lower cells, but not in the first one or two cells. Type X and type II mRNA localization continues until the terminal chondrocyte degenerates and the lacunae is empty. Bar = 45 μ m.

In summary, *in situ* hybridization to messenger RNA allows us to localize the site of synthesis of extracellular matrix macromolecules in the tissue. This technique thereby permits the analysis of cell function without disruption of cell morphology. For the first time, we can determine exactly which cells are responsible for the deposition of different matrix molecules. To

compare the processes of development, growth, and repair, we examined the expression of collagen messenger RNAs during vertebral column chondrogenesis and chondrocyte differentiation within the growth plate. We found that one type of collagen (IIB) occurs where cartilage currently exists and that another (IIA) occurs where cartilage will be formed in the future.

Clinically, the discovery of type IIA procollagen and its expression in non-cartilaginous and precartilaginous tissues may provide the key to understanding the question of how and where skeletal elements are induced in the growing embryo. These sites will include those where bones and joints will eventually be formed. A similar process will help elucidate the basis for the ability of bones and cartilage to be repaired. We now have the tools for studying not only when and where cartilage may develop, but also for exploring the possibility of turning on and off the growth and repair mechanisms.

Supported by the National Institutes of Health and the Department of Veterans Affairs

Recommended Reading

Ryan MC, Sandell LJ: Differential expression of a cysteine-rich domain in the amino terminal propeptide of type II procollagen by alternative splicing of mRNA. *J Biol Chem* 265:10334-10339, 1990.

Sandell LJ, Morris N, Robbins JR, Goldring MB: Alternatively spliced forms of type II collagen mRNA define distinct populations of cells during vertebral development: Differential expression of the amino-propeptide. *J Cell Biol* 115:1307-1319, 1991.

Sandell LJ, Goldring MB, Zamparo O, Wu J, Yamin R: Molecular biology of type II collagen: New information in the gene. In: *Articular Cartilage and Osteoarthritis*, KE Kuettner, R Schleyerback, JG Peyron, VC Hascall (eds). New York: Raven Press, 1992, pp 81-94.

Calcaneal Neck Lengthening for Severe Abducto-Valgus (Flat) Hindfoot Deformities In Children

Vincent S. Mosca, M.D.

The flatfoot is a poorly understood condition. The idiopathic form has been a source of interest, investigation, and controversy for decades. Controversy surrounds the exact clinical and radiographic definitions of a flatfoot, the implications of satisfying those definitions, and the indications for observational, nonoperative, and operative management.

Flatfeet can be defined as abducto-valgus hindfoot deformities, thereby describing the talonavicular joint abduction and the talocalcaneal (subtalar) joint valgus. Another important component is plantar-flexion of the talus, which creates a second plane of deformity at the talonavicular joint, namely dorsal subluxation of the navicular. The overall effect is a foot in which the medial longitudinal arch is depressed and, in fact, inverted. The head of the talus is exposed plantar-medially, covered only by skin and a thin layer of fat inadequate for weight-bearing. This arrangement forces the head of the talus to become a major weight-bearing portion of the foot and, therefore, a potential source of disability due to pain, calluses, and ulceration.

Although controversies of definition and management persist for the idiopathic form, it is clear that pathologic forms cause disability and warrant treatment. No reliably successful surgical technique has evolved when conservative management fails.

Arthrodesis of one or more of the hind- or midfoot joints has been the traditional management for these disabling deformities. However,

arthrodesis frequently shortens the foot, puts excessive stress on adjacent joints (leading to degenerative joint disease), eliminates the shock absorption function of the foot, and may not correct all components of the deformity. It also is inappropriate for children with significant growth remaining.

Evans described the calcaneal neck lengthening osteotomy as a way to avoid fusion when correcting severe flatfoot deformity. He felt that underlying diagnoses of cerebral palsy and spina bifida were contraindications for the technique, although he had no data to support this contention.

We conducted our study to assess the ability of Evans' technique to correct abducto-valgus hindfoot deformity in a series of patients with significant disability. Most of these patients had underlying neurological disorders.

Materials and Methods

A consecutive series of 39 patients with 55 severe and disabling abducto-valgus hindfoot deformities had calcaneal neck lengthening osteotomies between June 1988 and November 1991. To date, 31 feet in 20 patients have been followed for a minimum of two years. Inasmuch as the results in this two-year group showed no deterioration at maximum follow-up (3 years, 7 months), this report presents data on the entire series.

We performed the osteotomy in 28 feet in 18 patients with myelomeningocele when neurotrophic calluses and ulcers persisted under the head of the talus despite extensive brace modifications. This group included 19 flatfeet and nine skewfeet (identical hindfoot deformity plus severe metatarsus adductus). Fifteen distal tibial varus derota-

tional osteotomies and 12 medial cuneiform opening wedge osteotomies were performed simultaneously.

There were nine flatfeet and one skewfoot in the seven patients with cerebral palsy who underwent surgical correction, and all had short tendo-Achilles that were lengthened concurrently. Three patients with four severe, symptomatic, idiopathic skewfeet had simultaneous calcaneal neck and medial cuneiform lengthening osteotomies.

We performed the procedure in four overcorrected clubfeet in three patients with underlying syndromes and in one patient who was otherwise normal. The osteotomy helped to maintain foot length in two patients in the former group who had simultaneous talonavicular fusion.

Three feet in three patients with tarsal coalitions had calcaneal neck lengthening to correct severe deformity, two following successful resection and fat grafting of the coalition, and one without resection.

The remaining cases were three severe flexible flatfeet with short tendo-Achilles, two flatfeet caused by Guillain-Barré syndrome, and one flatfoot with hallux valgus and mild cerebral palsy. All had calluses, tenderness, and pain over the plantar medial aspect of the talar head.

We performed tendo-Achilles open Z-lengthening in all feet that lacked 10° of dorsiflexion after graft placement. We rarely used talonavicular joint capsular plication. Following patient preference, we used tricortical iliac crest autograft in eight feet and allograft bone in 47 feet.

Results were assessed clinically and radiographically. A satisfactory clinical result was characterized by elimination of the callus, redness, pain, and tenderness over the talar

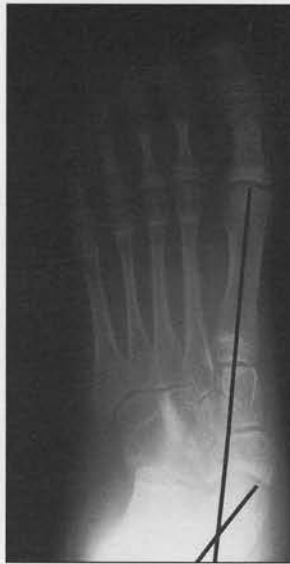

FIGURE 1

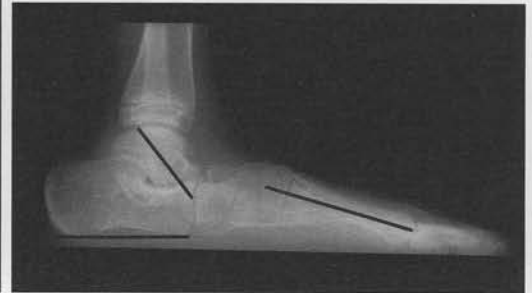

FIGURE 2

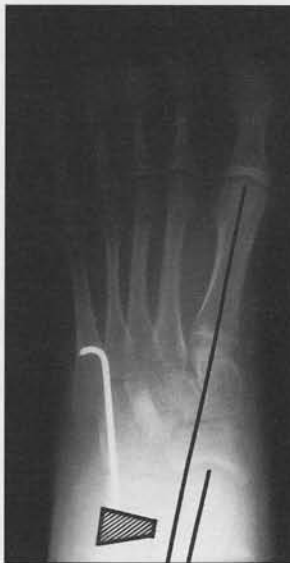

FIGURE 4

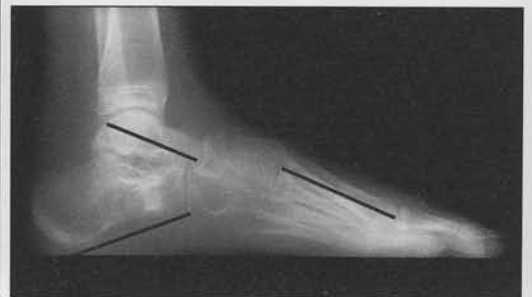

FIGURE 3

FIGURES 1-4: Painful flatfoot with callus under talar head. Figure 1: AP talo-first-metatarsal angle markedly abducted. Figure 2: Calcaneal pitch is 0° and Meary's angle is 35°. Figure 3: Trapezoid-shaped tricortical iliac crest graft is inserted 1-1.5 cm proximal to calcaneocuboid joint. Figure 4: Calcaneal pitch corrected to 21° and Meary's angle to 0°.

head, and improvement in brace tolerance and shoe wear. The visible presence of a longitudinal arch was considered desirable, but not necessary. Radiographic assessment was particularly difficult because many of the neurogenic flatfeet had mild metatarsus adductus that made the anteroposterior (AP) talo-first-metatarsal angle somewhat unreliable. Although it was possible to group these feet with the severe skewfeet, they were so mild that forefoot correction was not deemed necessary. The normal, laterally eccentric ossification of the navicular in the younger children also made

assessment of talonavicular alignment difficult. The most reliable radiographic values seemed to be the calcaneal pitch and Meary's lateral talo-first-metatarsal angle.

Results

Calluses, redness, tenderness, and pain were eliminated in all but three feet. In one, the graft slipped in the postoperative cast and was malunited. In two others, Meary's angle was greater than 50° before surgery (normal average 0°) and only corrected to 30° despite placement of the largest graft possible. These feet were, nevertheless, improved.

Although subtalar motion is difficult to assess accurately, subtalar joint motion was clearly preserved in all feet that did not undergo simultaneous fusion.

Grouped statistical analysis of radiographic data is inappropriate because of the varied deformities and patient ages. All measurements showed marked improvement in all patients. Calcaneal pitch and Meary's angle were corrected to the normal range in all except the three feet discussed above. The AP talo-first-metatarsal angle corrected to the normal range in all except the foot in which the graft slipped. All grafts incorporated within two months.

Some feet showed a tendency for dorsal subluxation of the distal calcaneal fragment at the calcaneocuboid joint during graft placement. This problem was controlled with a longitudinal wire that crossed the joint from distal to proximal and then continued through the graft into the proximal calcaneus.

Discussion

There is no consensus on what constitutes strict clinical and radiographic criteria for defining a foot as flat or as needing treatment. It is clear, however, that many children with neuromuscular disorders have feet that satisfy the loose anatomic criteria, and many of these cause disability.

Children with spastic diplegia and quadriplegia have short and spastic gastrocnemius/soleus complexes associated with their flatfeet. This forces the head of the talus into even more rigid plantarflexion and shifts the unyielding terminal ankle dorsiflexion to the more supple talonavicular joint. Large, tender, and painful calluses develop over the plantar medial aspect of the head of the talus.

Flatfeet also are frequently seen in children with myelomeningocele. Although they rarely have short tendo-Achilles, their insensate pedal skin contributes to neurotrophic ulceration over the talar head. Ankle joint valgus, which is an anatomic variation in almost all children with myelomeningocele, adds to the stress placed on the medial aspect of the foot and, in particular, the head of the talus.

Severe and disabling abducto-valgus hindfoot deformity also is seen in other paralytic conditions as well as in skewfeet (whether idiopathic, iatrogenic, or paralytic) and overcorrected clubfeet.

When conservative management fails to relieve the disabilities caused by severe abducto-valgus (flat) hindfoot deformities, surgical treatment is indicated. Calcaneal neck lengthening offers a solution that obviates the many short- and long-term disadvantages and disabilities of arthrodesis. It is simple, reliable, effective, and appropriate for children as young as four years and for those with neuromuscular disorders. Long-term follow-up is needed to determine if restoration of normal joint alignment with preservation of subtalar motion by this method will give good lasting results.

Recommended Reading

Crego CH, Ford LT: An end-result study of various operative procedures for correcting flat feet in children. *J Bone Joint Surg* 34A:183-195, 1952.

Evans D: Calcaneo-valgus deformity. *J Bone Joint Surg* 57B:270-278, 1975.

Phillips GE: A review of elongation of os calcis for flat feet. *J Bone Joint Surg* 65B:15-18, 1983.

Seymour N: The late results of naviculo-cuneiform fusion. *J Bone Joint Surg* 49B:558-559, 1967.

Vanderwilde R, Staheli LT, Chew DE, Malagon PV: Measurements on radiographics of the foot in normal infants and children. *J Bone Joint Surg* 70A:407-415, 1988.

"Metaphyseal" Cysts in Legg-Calvé-Perthes Disease

Scott A. Hoffinger, M.D.
George T. Rab, M.D.
Peter B. Salamon, M.D.

Metaphyseal changes in the proximal femur in Legg-Calvé-Perthes (LCP) disease have been the subject of several investigations, but remain poorly understood. Many investigators have confirmed the prognostic significance of these so-called "cysts," yet their etiology and location remain unclear. The presence of these changes on both the anteroposterior and lateral plain radiographs makes it appear that they are located within the metaphysis. However, the "sagging rope" sign calls this into question.

In 1981 Apley and Weintraub described the sagging rope sign as "a thin opaque line in the upper femoral metaphysis," which they felt was "related to the extent of the metaphyseal response (to ischemic damage)." However, during a hip exploration two years later, Clarke and colleagues showed this sagging rope to be no more than the "anterolateral edge of a very deformed femoral head." Therefore, any changes proximal to the sagging rope may be epiphyseal despite a metaphyseal appearance on radiographs.

As we have found no metaphyseal lucencies distal to the sagging rope, we hypothesized that these so-called "cysts" might represent epiphyseal or physeal changes radiographically superimposed on the metaphysis. We conducted our study to test whether routine hip radiographs could project purely epiphyseal changes onto the upper femoral metaphysis.

Materials and Methods

The lower portion of a skeletally immature left proximal femur was potted in methylmethacrylate. Radio-opaque barium sulfate paste was used to mark the physis and to make epiphyseal "lesions" by painting barium on the anterior and anterolateral portions of the epiphysis. Anteroposterior and lateral radiographs were then taken with different sized "lesions."

A proximal femoral hemisection from a patient with Perthes disease was obtained from a necropsy specimen. This specimen allowed excellent identification of the physeal line and was used to perform similar radiographic studies on a more deformed epiphysis.

Results

Radiographs of the normal femur were taken to locate the physeal line. Due to the convex nature and orientation of the physis, peripherally placed markings projected onto the proximal metaphysis (Figure 1). Markings similar to Catterall 2 and Catterall 3 Perthes disease were made. The anteroposterior (AP) radiograph of the Catterall 2 lesion projected these markings onto the metaphysis while the lateral radiograph showed the markings to be epiphyseal. The Catterall 3 lesion projected onto the metaphysis in both the AP and lateral views (Figure 2).

The mild flattening in the head with Perthes distorted the epiphysis enough to make even the physeal line markings project well into the metaphysis. A lesion was made laterally on the deformed epiphysis, and the AP radiograph clearly shows the lesion to appear deep within the metaphysis (Figure 3).

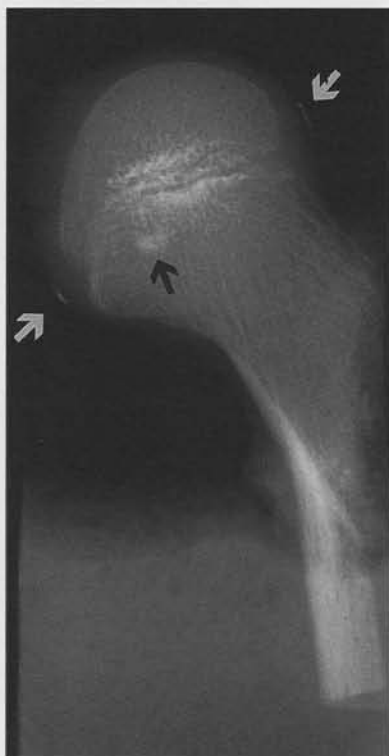

FIGURE 1: AP radiograph of the normal proximal femur with physeal markings. The peripheral physeal marking can be seen (white arrows), but the opposite view shows that one projects onto the metaphysis (black arrow).

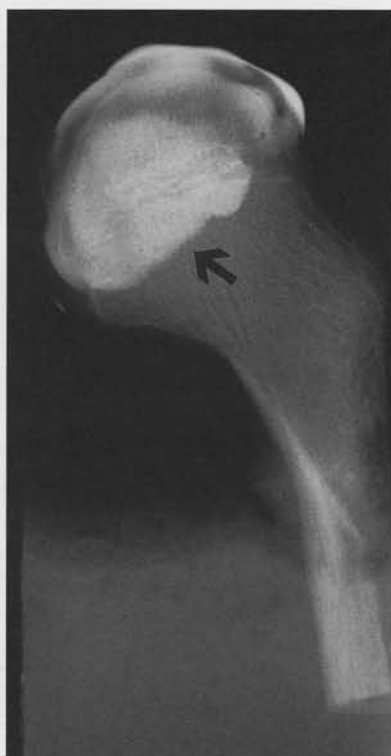

FIGURE 2: A larger epiphyseal lesion, again, proximal to the physeal line. The radiograph shows the lesion to project onto the metaphysis (arrows), as it does on the lateral view as well. This occurs because a different portion of the epiphysis overhangs the metaphysis on each projection. A lesion that involves enough of the epiphysis will project onto the metaphysis in multiple views.

Discussion

It has always been assumed that radiographic changes projected on the metaphyseal area on both AP and lateral views are truly metaphyseal. Histologic data on this subject are sparse. Ponseti, in 1956, biopsied two patients with Perthes and found "tongues of fibrillated cartilage ... [extending] deep into the femoral neck." He postulated that where disruption of ordered enchondral ossification occurred, growth retardation would leave rests of physeal cartilage in the metaphysis. However, Katz refuted Ponseti's theory of cartilage rests by noting that the depth of these lesions would require an extraordinarily large amount of growth in a short period, more growth than could be expected. Also, such lesions should start at the physis and progress distally over time, which has not been observed.

Despite study of several specimens, researchers have yet to biopsy a metaphyseal cyst. In view of Clarke's findings that the sagging rope is not within the metaphysis but is the edge of the femoral head, and our findings of epiphyseal projection artifact, it seems likely that an epiphyseal or physeal process may be responsible for these "metaphyseal" cysts. We believe these "metaphyseal" changes in Perthes disease are the result of projection artifact exacerbated by deformity and three-dimensional distortion of the proximal femur.

Our next project involves an MRI study of patients both with and without "metaphyseal" changes on plain radiographs. A pilot study has shown that MRI is an extremely sensitive tool able to detect changes where none exist on plain radiographs. Most lesions appear to be physeal or epiphyseal rather than truly metaphyseal.

Recommended Reading

Apley AG, Weintraub S: The sagging rope sign in Perthes disease and allied disorders. *J Bone Joint Surg* 63B:43-47, 1981.

Catterall A, Pringle J, Byers PD, et al: A review of the morphology of Perthes disease. *J Bone Joint Surg* 64B:269-275, 1982.

Clarke NMP, Harrison MHM, Keret D: The sagging rope sign: A critical appraisal. *J Bone Joint Surg* 65B:285-287, 1983.

Katz JF, Siffert RS: Capital necrosis, metaphyseal cysts and subluxation in coxa plana. *Clin Orthop Rel Res* 106:75-85, 1975.

Ponseti IV: Legg-Perthes disease: Observations on pathological changes in two cases. *J Bone Joint Surg* 38A:739-750, 1956.

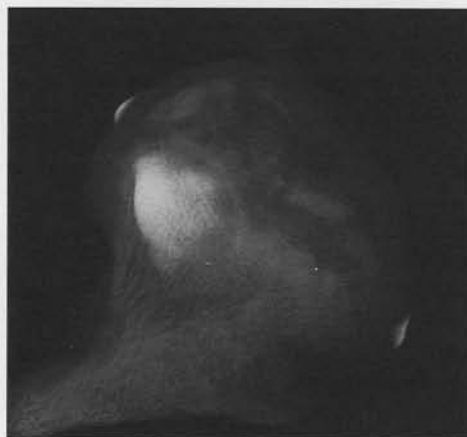

FIGURE 3: An epiphyseal lesion in the Legg-Calvé-Perthes (LCP) specimen projects well into the metaphysis. This is due to the flattening and distortion created by the LCP.

Prognostic Factors in Infantile Tibia Vara

Mark C. Dales, M.D.
Charles E. Johnston, M.D.
Randall L. Loder, M.D.

Infantile tibia vara, often referred to as "Blount's disease," is one of several conditions (along with physiologic bowing, rickets, and osteochondrodystrophies) that may present as "bowlegs" in the toddler or child. Blount described tibia vara in 1937. Investigators have since found that the pathologic changes are a disturbance in growth of the medial physis and metaphysis producing progressive genu varum with growth.

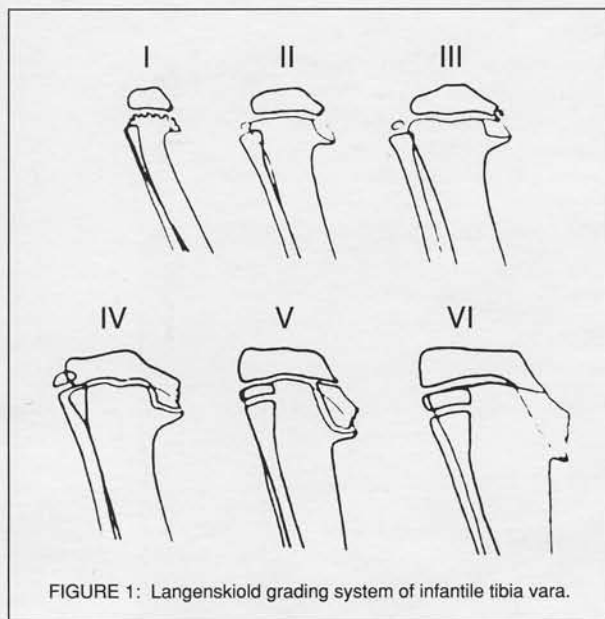


FIGURE 1: Langenskiold grading system of infantile tibia vara.

Physiologic bowlegs are normal in the toddler and spontaneously resolve to the normal 7° to 9° valgus by three years of age. By contrast, infantile tibia vara is a pathologic process that, if untreated, will progress with physeal irregularity and eventual damage leading to permanent angular deformity.

Separating infantile tibia vara from physiologic bowing can be difficult, especially at less than 18 months of age. Levine and Drennan suggested using the tibial metaphyseal-diaphyseal angle to differentiate the two prior to the appearance of the radiographic changes indicating Blount's disease, but this approach has not been duplicated by other investigators or in our own experience. After the diagnostic radiographic changes appear, the physician must determine optimal timing and method of treatment.

Early reports suggested that infantile tibia vara could be treated successfully up to the age of eight. Traditionally, changes up to Langenskiold's stage IV (Figure 1) were felt to be reversible and curable. More recent series, however, have suggested a poorer prognosis and have recommended earlier intervention. The usual treatment is bracing or corrective osteotomy. A perplexing aspect of infantile tibia vara is the variable nature of the disease, with seemingly similar clinical and radiographic appearances having quite different outcomes despite similar treatment (Figure 2). To attempt to identify patients at risk for a poor result, we posed the following questions:

1. Is bracing effective, and when is it appropriate?
2. Can the Langenskiold grading system accurately be used to predict prognosis or the timing of surgery?
3. Are there other indices that could be used to predict prognosis?

We reviewed the results of treatment in 54 knees in 33 patients and attempted to identify the early clinical and radiographic indices to develop prognostic factors for the treatment of Blount's disease. Patients with less than two years' follow-up, older than eight years at

initial visit, and without definite radiographic evidence of infantile tibia vara were excluded. Follow-up averaged 6.2 years. Langenskiold staging and four radiographic measurements (Figure 3) were made for each initial radiograph. The final results were graded clinically and radiographically (Table 1).

Inter- and intra-observer variance was assessed for applying the Langenskiold stage and its correlation with prognosis. Significant variance was found between graders, especially for stage II to IV lesions, suggesting that the Langenskiold scale be used cautiously as an indicator of extent of disease, treatment timing, or prognosis.

None of the radiographic measurements were useful in predicting outcome, either overall or within each Langenskiold stage. There was no statistically significant differentiation for the group in which orthotics had been successful and those that required osteotomy. Finally, the radiographic measurements did not predict which patients would achieve a satisfactory result with a single osteotomy versus those that required multiple osteotomies.

The only factor that correlated with success of the first osteotomy was age. Of 11 patients under four years old, eight had a satisfactory final result, defined as a good or fair clinical and radiographic outcome accomplished with a single osteotomy. Two of the three unsatisfactory results were in patients with

TABLE 1: Grading for Final Results

Good:	Mechanical axis 0 Shortening <1 cm Congruent joint Pain free
Fair:	<7° varus Occasional pain Congruent joint
Poor:	>7° varus >2.5 cm short Incongruent joint Pain

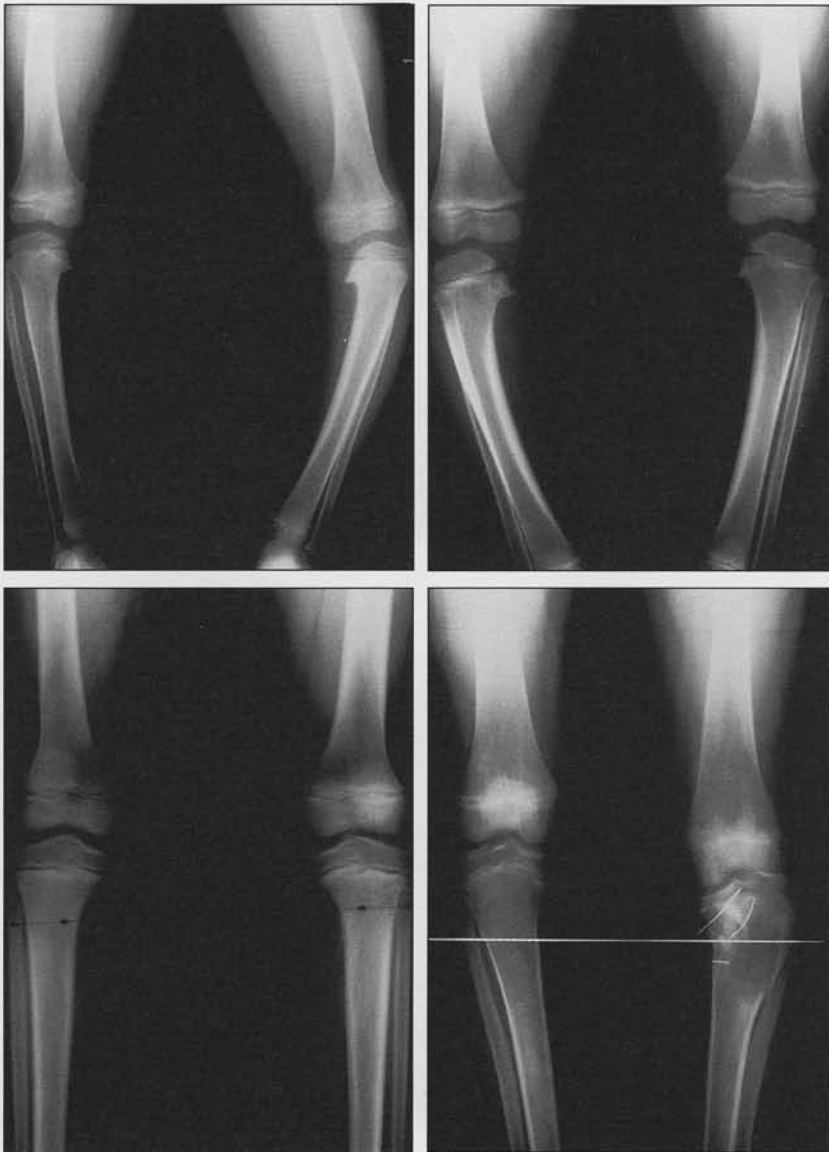

FIGURE 2: The variable nature of infantile tibia vara is shown in these two patients with early Blount's disease. The patient on the left had a satisfactory result with bracing. The patient on the right progressed despite bracing, required multiple procedures, and still had significant deformity.

good final clinical results but who required a second osteotomy. Only one of the 11 had a poor result. In contrast, only 11 of 27 patients who had osteotomies after age four had a good or fair final result, and only nine were from a single osteotomy.

The results for stage III or IV lesions were disappointing. This moderate degree of involvement has been considered curable in past reports, but we found one good, three fair, and four poor results in the stage III lesions, and no good, three fair, and three poor results in the stage IV. Only five of the 14

patients had a satisfactory result with a single osteotomy.

In patients with early disease (stage I or II), bracing improved clinical alignment and reversed the radiographic changes in 46%. However, too many different types of braces and methods were used over the review period to provide statistical support for any one type of bracing protocol. These results are encouraging, however, and a prospective study using a specific bracing protocol is under way.

Our study suggests that bracing may be beneficial for early (stage I

and II) Blount's disease. We currently recommend that knee-ankle-foot or hip-knee-ankle-foot orthoses be worn during the day when the child is weight-bearing. Braces should only be used by patients with documented radiographic changes, since "deformity" also may be due to physiologic bowing, which has a natural history of resolution. Braces should be worn until the lesion resolves, but not past four years of age, since our data support the recommendation to operate prior to age four. For this reason it also is not reasonable to begin bracing after three years of age.

Although the Langenskiold classification correlates fairly well with prognosis at either end of the scale (Table 2, page 32), there is significant variability of results in the middle stages (II to IV). For this reason, as well as the intraobserver variance noted, we do not recommend the classification be used as the sole determinant of treatment. As no other reliable prognostic indicator has been found, we recommend corrective osteotomy if deformity and radiographic changes are present by four years of age.

The best results are obtained if surgery is performed prior to four years of age. Even then, 20% in our series required a second procedure. We found no radiographic or clinical parameter to identify those patients with a poor prognosis, nor could

(continued on page 32)

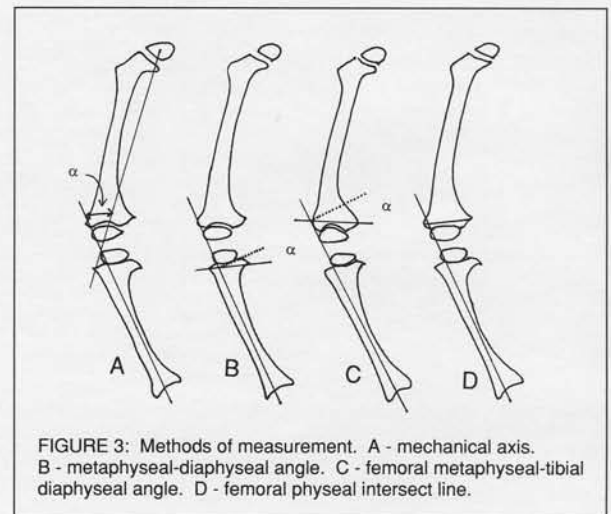


FIGURE 3: Methods of measurement. A - mechanical axis. B - metaphyseal-diaphyseal angle. C - femoral metaphyseal-tibial diaphyseal angle. D - femoral physal intersect line.

The Hamstrings in Cerebral Palsy Crouch Gait

Gait Laboratory Analysis

Scott A. Hoffinger, M.D.
George T. Rab, M.D.
Hassan Abou-Ghaida, M.S.

Crouch gait is a common walking pattern in children with cerebral palsy. Tight triceps surae and hamstrings often are implicated as the cause of crouch gait and, as a result, frequently are lengthened surgically.

It has been shown, however, that the hamstrings account for approximately one-third of the hip extensor torque in normal persons. The hamstrings exert their effect over two joints (hip and knee). The length of the hamstrings affects, and is affected by, the position of both joints. The relative contribution of each joint's position to the length of the hamstrings depends on the perpendicular distance from the muscle origin to the hip joint center and from the muscle insertion to the knee joint center (Figure 1). This lever arm has been calculated to be three times as great at the hip as at the knee.

After observing some patients with excessive hip flexion following hamstring lengthening, we became concerned that the hamstrings are important hip extensors in patients with crouch gait. We studied the motion of the hip and electrical activity of the medial hamstrings with three-dimensional gait analysis and dynamic electromyography (EMG) to determine if the hamstrings were contributing to hip extension in these patients.

Materials and Methods

We studied 16 patients with the clinical diagnosis of crouch gait. Many of these patients demonstrated increased muscle tone during the dynamic state (when walking) as compared to a static physical exam. All patients therefore underwent a thorough physical exam and complete gait analysis. We used a Motion Analysis Expert Vision System with four channels of dynamic, surface EMG data in each lower extremity.

We determined hamstring length by calculating the distance between muscle origin and insertion along the path of that muscle. The length is reported relative to the anatomic resting length (1.0), defined as the distance between origin and insertion in the anatomic position (Figure 2). We specifically looked for medial hamstrings that showed abnormally prolonged electrical activity and concentric contraction as this defines "positive work" according to Winter. Clinical hamstring tightness was measured by the "popliteal angle," which is more reproducible in the cerebral palsy population. This is the angle of the popliteal fossa when the patient is supine, the hip is held at 90°, and the knee is extended maximally.

Results

The average age of our patients was 10 years 6 months. Their popliteal angles averaged 78° on the right and 80° on the left, indicating a significant degree of hamstring tightness. Dynamically, on gait analysis, the minimum hip flexion (best extension) during stance was 20° on the right and 27° on the left. The minimum dynamic knee flexion during stance phase averaged 22° on the right and 31° on the left. The EMG activity in the medial hamstrings during stance was greater than normal ($\geq 33\%$ of stance) in 13 of the 16 patients and significantly prolonged ($\geq 67\%$ of stance) in 12 of these 13 patients.

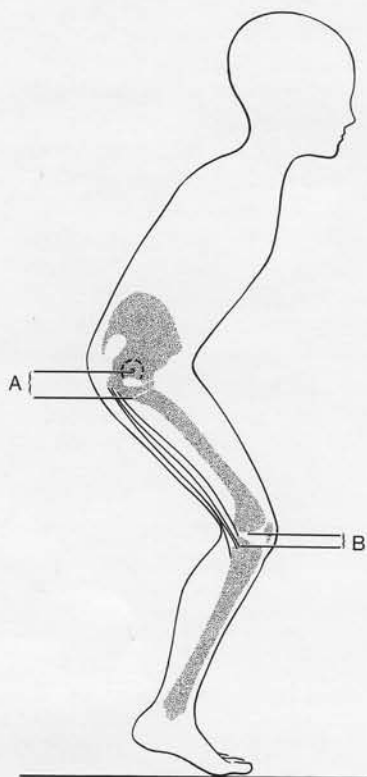


FIGURE 1: The relative contribution of each joint's position to the length of the hamstrings depends on the perpendicular distance from the origin to the hip joint center and from the insertion to the knee joint center.

Evaluation of calculated dynamic hamstring length revealed that in all but four patients both right and left medial hamstrings were longer than resting length during stance phase (Figure 2). In these other four patients, one side was shorter than resting length while the other was longer than or equal to resting. Considering the hamstrings independently, 28 of 32 hamstrings were longer than resting length during stance phase.

The slope of the hamstring muscle length plot was compared to the EMG data for those patients who showed significantly prolonged stance phase activity ($\geq 67\%$) to determine which muscles were contracting concentrically. Of the 32 hamstrings in our 16 patients, 18 were found to be contracting concentrically and were thus aiding hip extension.

Discussion

Crouch gait, while easily recognized clinically, is poorly defined biomechanically. Sutherland, in one study of crouch gait, included only patients with $\geq 30^\circ$ of knee flexion throughout stance, but all had "exaggerated ankle dorsiflexion" as well.

All descriptions of crouch gait include increased knee flexion during stance. The other deformities frequently mentioned as accompanying knee flexion in crouch gait (i.e., equinus, calcaneus, and hip flexion) can be secondary to knee flexion. To remain upright, primary knee flexion obligates the patient to flex the hips and either assume a calcaneus posture or rise up on the toes. We thus considered persistent knee flexion during stance phase both a necessary and sufficient criterion for the diagnosis of crouch gait.

Our study population consisted of ambulatory cerebral palsy patients with crouch gait, defined as persistent, dynamic knee flexion during stance. Their popliteal angles averaged 78° to 80° , indicating clinically "tight" hamstrings. Yet, when these patients were studied using the muscle length program, the hamstrings were found to be

longer than resting length. Although this seems unusual as one expects the hamstrings to be short due to their clinical tightness, the effect of hip position on hamstring length must be considered.

The fact that the hamstrings in our patients are "long" rather than "short" is due to the hip flexion contracture. This contracture has a profoundly greater influence on hamstring length than does the knee flexion contracture.

Conclusion

The significance of these findings has affected the way we deal with tight hamstrings in ambulatory diplegic patients. Tight hamstrings do not necessarily mean short hamstrings, but may be an indicator of hip flexion contracture and should direct attention there. Should these patients come to surgical treatment, we carefully examine the gait analysis to determine if the hip shows dynamic contracture and if the hamstrings have prolonged electrical activity during stance. If so, we are especially careful to avoid hamstring over-lengthening to prevent an increase in hip flexion, and will strongly consider lengthening the iliopsoas at the pelvic brim to counteract the decreased hip extensor force. Crouch gait in cerebral

palsy may indeed be due to tight hamstrings, which may itself be due, in part, to hip flexion contracture. We are continuing our investigation by attempting to determine how much dynamic knee flexion contracture can be alleviated through iliopsoas lengthening alone.

Recommended Reading

Crowninshield RD, Johnston RC, Andrews JG, Brand RA: A biomechanical investigation of the human hip. *J Biomech* 11:75-85, 1978.

Dostal WF, Andrews JG: A three-dimensional biomechanical model of hip musculature. *J Biomech* 14:803-812, 1981.

Sutherland DH, Cooper L: The pathomechanics of progressive crouch gait in spastic diplegia. *Orthop Clin North Am* 9:143-154, 1978.

Waters RL, Perry J, McDaniels JM, House K: The relative strength of the hamstrings during hip extension. *J Bone Joint Surg* 56A:1592-1597, 1974.

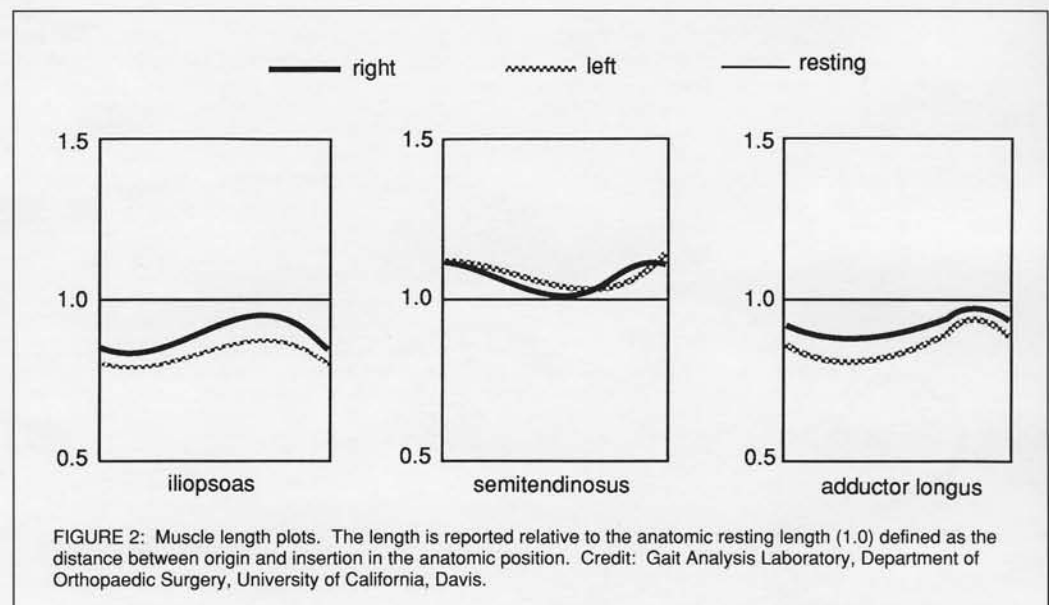


FIGURE 2: Muscle length plots. The length is reported relative to the anatomic resting length (1.0) defined as the distance between origin and insertion in the anatomic position. Credit: Gait Analysis Laboratory, Department of Orthopaedic Surgery, University of California, Davis.

The Role of the Shelf Procedure in Managing Acetabular Dysplasia

Lynn T. Staheli, M.D.

Acetabular dysplasia usually leads to degenerative arthritis of the hip. The human hip joint is inherently susceptible to degenerative changes as demonstrated by the frequency of degenerative arthritis of the joint. This inherent vulnerability of the hip joint is due to its tenuous vascularity, the hip's marginal load-bearing area (presumably related to our upright posture), and the accumulated wear on the joint in the aging population. At special risk are dysplastic hips or shallow sockets at the end of the spectrum of normal anatomic variability. As we have become more aware of the poor prognosis for the hip in the child or adolescent with a dysplastic acetabulum, and as our operative techniques to correct dysplasia become more refined, the practice of correcting acetabular dysplasia in childhood has become a more accepted practice.

Imaging

In the child, acetabular dysplasia is often clinically silent but is readily demonstrated by conventional radiography. The most valuable measures are those for which normative values are available for comparison. These measures include the acetabular index (AI), most useful in the infant and young child, and the center-edge (CE) angle, a reliable measure in the older child, adolescent, and adult. With advancing age the AI gradually declines. Values in excess of 40° in early infancy, and beyond 25° in the two-year-old, are abnormal. An abnormally high AI, and a failure of the AI to decline over a period of observation, constitutes an indication for operative correction of acetabular dysplasia in the infant and young child. In the adolescent and adult, a CE angle less than 20° is abnormal. Additional features of dysplasia include an abnormal shape of the acetabulum and upper femur, subluxation of the joint, and malposition of the hip socket relative to the pelvis.

Selection of Procedure

The selection of the operative procedure to correct acetabular dysplasia should be tailored to correct the problems most effectively. The patient's age, the severity of dysplasia, and the shape of the acetabulum and upper femur are important concerns. In the infant and child, dysplasia usually is best corrected by pelvic osteotomies such as the Salter or Pemberton procedures, which reposition hyaline cartilage over the femoral head. For severe acetabular dysplasia, especially in the older child or adolescent, acetabular augmentation — the "shelf" procedure — is often useful.

Shelf Procedure

The shelf operation, the oldest of acetabular procedures, was first performed a century ago by Konig. The shelf procedure is a capsular arthroplasty designed to enlarge the acetabulum by placing a bony graft over the joint capsule to extend the load-bearing area of the joint. Many shelf operations have been devised, but a common problem was the difficulty in creating congruity

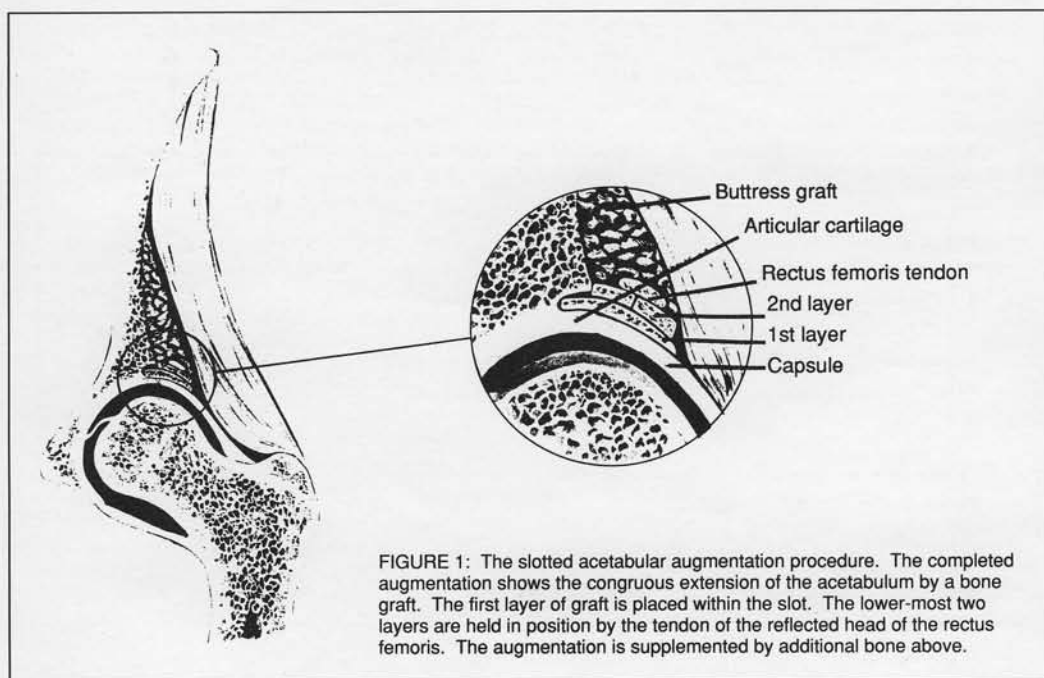


FIGURE 1: The slotted acetabular augmentation procedure. The completed augmentation shows the congruous extension of the acetabulum by a bone graft. The first layer of graft is placed within the slot. The lower-most two layers are held in position by the tendon of the reflected head of the rectus femoris. The augmentation is supplemented by additional bone above.

between the graft and the acetabulum. If the augmentation was placed too high, the shelf would remain unloaded and undergo resorption. If placed too low, the graft would impinge on the femoral head and accelerate the rate of degenerative change. Proper positioning of the graft has been improved by the "slotted acetabular augmentation" technique (Figure 1). The graft is placed in a slot in the ilium exactly at the acetabular margin. This precisely controlled placement has improved results (Figure 2).

Indications

A shelf procedure is considered in a child, adolescent, or young adult with acetabular dysplasia when a redirection pelvic osteotomy is contraindicated because of joint incongruity, severity, or for technical reasons. The shelf procedure is best performed in the older child or adolescent with severe dysplasia. The procedure is ideal in cases of bilateral dysplasia as both acetabulae can be augmented during the same procedure. As no internal fixation is required, a second procedure is not needed.

Technique

The procedure is performed through a "bikini" incision and an iliofemoral approach. The hip joint is exposed and the reflected head of the rectus femoris isolated. The tendon is incised anteriorly and dissected from the underlying capsule. Its posterior attachment is preserved. A slot is created at the acetabular margin with articular cartilage of the acetabulum on its floor. Iliac bone is taken from the crest and placed within the slot and extended over the capsule. The extent of the graft is measured to create a CE angle of about 45°. Care is taken to avoid excessive anterior extension of the augmentation that might block flexion. Two or three layers of bone are placed. The medial portion of the graft is secured in the acetabular slot and the lateral aspect is secured by repositioning the tendon of the reflected head over the graft and suturing the anterior end of the tendon onto the capsule. Abundant

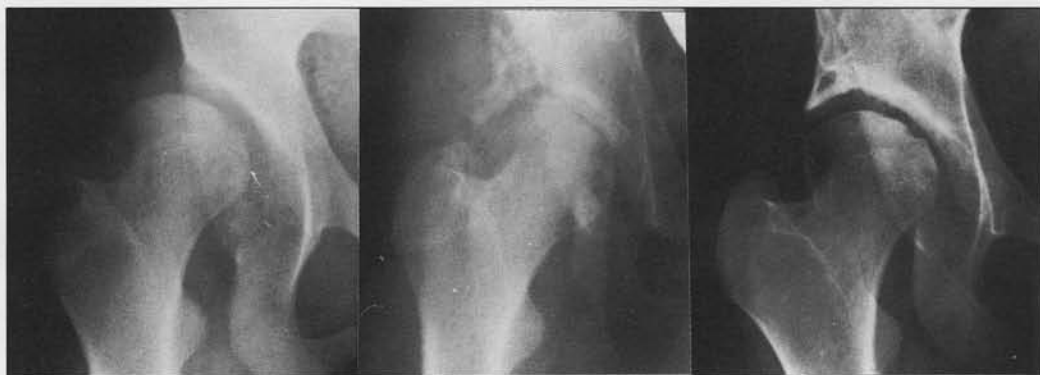


FIGURE 2: Acetabular augmentation in a 13-year-old girl with developmental hip dysplasia who has persisting acetabular dysplasia, joint subluxation, and residual femoral head deformity. (L to R) The preoperative, initial, and two-year postoperative radiographs are shown.

additional graft is placed above the augmentation, encompassing the tendon of the reflected head, to increase the thickness of the augmentation. The postoperative management includes immobilization in a spica cast for six weeks and the use of crutches for an additional two to three months to protect the graft until it solidifies.

Results

Our study included 157 hips in 140 patients between two and 21 years (mean 12 years). The indications for the procedure included pain in 71 hips, progressive subluxation in 52, and acetabular dysplasia in 34 hips. The common causes of dysplasia were developmental dysplasia in 55% and cerebral palsy in 35%. The augmentation frequently was combined with other procedures such as femoral or pelvic osteotomies. The most common complications were excessive anterior extension of the augmentation necessitating "trimming" of the graft and insufficient thickness of the augmentation. In 108 hips with a follow-up of more than 24 months (mean 60 months), 83% were rated as good or excellent, based on criteria which included both radiographic and clinical features.

Future Role of the Shelf Procedure

The shelf operation has a clear role in managing acetabular dysplasia because of its versatility, safety, and effectiveness. A new application is in the early treatment of Perthes disease. The augmentation is

performed early to provide containment and prevent extrusion of the avascular femoral head to maintain sphericity of the femoral head. The results appear promising.

Recommended Reading

Konig F: Osteoplastische Behandlung der Kongenitalen Hüftgelenksluxation (mit Demonstration eines Pareparates). *Verh Dtsch Ges Chir* 20:75-80, 1891.

Staheli LT: Slotted acetabular augmentation. *J Pediatr Orthop* 1:321-327, 1981.

Zucherman JD, Staheli LT, McLaughlin JF: Acetabular augmentation for progressive hip subluxation in cerebral palsy. *J Pediatr Orthop* 4:436-442, 1984.

Kruse RW, Guille JT, Bowen JR: Shelf arthroplasty in patients who have Legg-Calvé-Perthes disease. *J Bone Joint Surg* 73A:1338-1347, 1991.

The Investigation of Multiple Hereditary Exostoses

Ernest U. Conrad III, M.D.,
Wendy Raskind, M.D., Ph.D.
Greg Schmalle, M.Ed.

Multiple hereditary exostoses (MHE) is a benign, familial dysplasia of skeletal bone that typically produces significant orthopaedic deformity in the majority of persons affected. It has been classically described as a familial disease of autosomal dominant inheritance, and shows wide variation in the reported rates of incidence and of malignant degeneration.

The cellular events that initiate formation of an exostosis are unknown. Early studies by Muller and Keith suggested that defects in the perichondral ring and enchondral ossification are involved in the pathogenesis of the disease. Although the natural history of MHE is not fully characterized, its genetic basis and association with chondrosarcomas offer a possible genetic model for the investigation of malignant transformation.

Studies of prevalence in several small populations have revealed rates ranging from one person affected in 1,000 to one in 90,000. Based on Washington's 1990 popu-

lation of 4,866,692, and the ascertainment of 68 affected Washington residents, we calculated an "in state" prevalence of one in 70,000. This estimate is likely to be low, as persons with mild or subclinical disease may not have been diagnosed. The sex distribution for these cases was 56% male to 44% female.

We have established a comprehensive multiple hereditary exostosis project as a collaborative effort between the Department of Orthopaedics and the Division of Medical Genetics at the University of Washington and Children's Hospital and Medical Center. The objectives are:

1. To identify the prevalence and expression of MHE in our region.
2. To identify the incidence of malignant degeneration.
3. To identify the penetrance of the MHE gene.
4. To carry out gene mapping on involved families.

We reviewed medical charts at Children's Hospital and the University of Washington Medical Center to establish a registry of patients and involved families. We also sent letters to local orthopaedists to identify additional cases. The registry now includes 43 families with 98 affected members, not all of whom are Washington residents. This study population is larger than any reported in the medical literature.



FIGURE 1: Thickened cartilage cap of an active exostosis.

For all families we obtained initial medical histories through telephone interviews and then conducted follow-up physical exams to assess the clinical manifestations of hereditary exostoses and complete the family histories. Peripheral blood was drawn on affected and unaffected family members to determine karyotypes and extract DNA for genetic markers. Statistical analysis was carried out by a Simlink pedigree analysis system donated by the University of Michigan.

We used a clinical staging system to assess severity of MHE. Review of the clinical data and pedigrees suggests that 15% of the cases (12 of 78) appeared to be new occurrences arising from genetic mutation. The mean age at diagnosis was 4.3 years \pm 0.9 years (range 16 months to 55 years) with the majority of the cases detected by the age of 12.

One patient with severe MHE developed multiple chondrosarcomas and is in the terminal phase with metastatic disease. Seventy-two percent of the patients had moderate or severe disease defined by multiple exostoses with either functional limitation or severe deformity. Thus, even without malignant degeneration, this disease confers significant morbidity.

Treatment in this patient population most commonly involved multiple excisions of the exostoses (Figures 1 and 2). Angular deformities of the long bones accounted for most of the morbidity. Severe involvement also was associated with leg or arm length discrepancies. Efforts to minimize deformities through more timely surgical

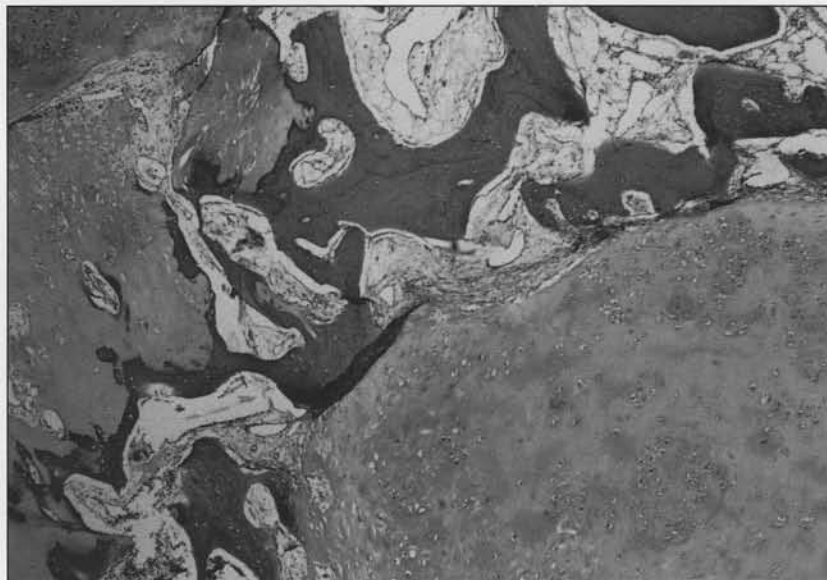


FIGURE 2: Cartilage-bone interface of a benign exostosis.

intervention (growth arrest versus lengthening procedures) will be a focus of future evaluations. Many patients in this cohort had multiple procedures that might have been possible to perform during one surgery.

We plan genetic studies to map the location of the MHE gene in the affected families. We also will investigate the possible roles of oncogenes, collagen genes, and suppressor genes in the development of exostoses and chondrosarcoma. This hereditary tendency toward tumor development provides a unique opportunity for defining factors predisposing to neoplasia.

Supported by the Department of Orthopaedics, Children's Hospital and Medical Center, and the Medical Genetics Laboratory

Recommended Reading

Crandall BF, et al: Hereditary multiple exostoses: Report of a family. *Clin Orthop Rel Res* 190:217-219, 1984.

Johnston C, Sklar F: Multiple hereditary exostoses with spinal cord compression. *J Pediatr Orthop* 2(8):1213-1216, 1988.

Pazzaglia UE, et al: Radiographic findings in hereditary multiple exostoses and a new theory of the pathogenesis of exostoses. *Pediatr Radiol* 20:594-597, 1990.

Soloman L: Hereditary multiple exostoses. *J Bone Joint Surg* 45B(2):292-304, 1963.

Voutsinas S, Wynn-Davies R: The infrequency of malignant disease in diaphysal aclasis. *J Med Genet* 20:345-349, 1983.

Gordan S, et al: Hereditary multiple exostoses: Report of a kindred. *J Med Genet* 18:428-430, 1981.

Solomon L: Hereditary multiple exostoses. *Am J Hum Genet* 16(3):351-363, 1964.

Fogel G, et al: Management of deformities of the forearm in multiple hereditary osteochondromas. *J Bone Joint Surg* 66A:670-680, 1984.

Stress Fractures in Professional Ballet Dancers

Carol C. Teitz, M.D.
Nancy J. Kadel, M.D.
Richard A. Kronmal, Ph.D.

Stress fractures are a common and disabling problem in female athletes and ballet dancers. Overuse generally is considered the primary cause of stress fractures. The higher incidence of stress fractures in female than in male athletes has led investigators to look for additional etiologic factors.

Menstrual irregularity and poor nutrition have been implicated in causing stress fractures in gymnasts and runners. High incidences of delayed menarche (beginning of menstruation), primary amenorrhea (never menstruating), and secondary amenorrhea (normal cycles initially, but less than six cycles per year subsequently) have been reported in ballet dancers and athletes who train intensively.

Several studies have noted a significantly higher incidence of stress fractures in amenorrheic runners and dancers than in their normally menstruating peers. However, duration of the amenorrheic interval as a risk factor has not been examined. Drinkwater and others have found that amenorrheic athletes lose bone mineral, making them effectively osteoporotic long before menopause.

Female ballet dancers train intensively, often from the age of six. In addition to hours spent rehearsing and performing, a professional dancer takes classes four to six hours per day, five to six days per week. Technical standards and current aesthetic ideals mandate that today's professional dancer be not only a precise technician, but also conform to an ultra-lean body image.

Anorexia nervosa, bulimia, and other eating disturbances are prevalent among young ballet dancers. The combination of nutritional deficiencies, menstrual abnormalities, and strenuous training schedules may leave the ballet dancer at risk for skeletal injuries. Our study was designed to determine if menstrual history, hours of training, calcium intake, and other factors differed significantly between dancers with and without stress fractures.

We surveyed 54 female dancers in two nationally recognized professional ballet companies. We collected company-specific data including dance technique, floor surface, season length, number of performances during the season, tour length, vacation time, and size of the company to ensure that the companies were indeed comparable. Dancers reported their consumption of a specific list of calcium-rich foods during the prior one-week period. Each dancer also completed a questionnaire on age, height, weight, dance training history, age of menarche, menstrual history, oral contraceptive use, and stress fracture history.

Stress fractures were diagnosed by a physician and were confirmed by either radiograph or bone scan. A total of 27 fractures were reported in 17 dancers. Fractures of the metatarsal were the most common (63%), followed by fractures of the tibia (22%) and spine (7%).

Only six of the 54 dancers menstruated normally. Fifty-six percent of the dancers in the fracture group were amenorrheic, compared to only 17% of the non-fracture group. Dancers in the fracture group also had a significantly longer duration of amenorrhea than those in the non-fracture group. Only one dancer in the non-fracture group had been amenorrheic for longer than six

months; in the fracture group all of the amenorrheic dancers had been so longer than six months.


Dancers who danced more than five hours per day were significantly more likely to have a stress fracture than those dancing less than five hours per day. Hours danced per day and duration of amenorrhea were found to contribute independently to the risk of stress fracture. Four dancers had both risk factors (i.e., they danced more than five hours per day and were amenorrheic longer than six months) and all four sustained stress fractures. Similarly, of the 17 dancers with stress fractures, only one had neither risk factor.

No significant difference was found between the stress fracture and non-fracture group for other variables examined. There were too few dancers taking oral contraceptives to determine whether they might protect the amenorrheic dancer from bone mineral loss.

Although the mean weekly calcium intake was 4,788 mg, well below the minimum recommended dietary allowance of 8,400 mg per week, there was no difference between the stress fracture group and non-fracture group; 76% in each group had weekly calcium intakes below the RDA.

We found no significant difference in fracture incidence as a function of age at menarche or of age at the time of study. Age might be considered to be a risk factor because the older dancer would have had more "opportunities" to fracture and to be amenorrheic. We did not find this to be the case.

Our data suggest that both excessive training and duration of amenorrhea are associated with increased stress fractures and that they contribute independently to the risk of fracture. Duration of amenorrhea was defined as the longest



single period of time without menstruating. A woman with short intervals of amenorrhea might be able to regain bone lost during that brief time, whereas a woman with a prolonged interval of amenorrhea might not. In our study, with one exception, all dancers who were amenorrheic longer than six months sustained at least one stress fracture. Obviously the risk in these dancers is extremely high, approaching 100%.

To best protect their bones from stress fractures or premature osteoporosis, we recommend that female dancers and athletes adjust their training schedules to avoid overuse and meet the RDA guidelines for calcium intake for postmenopausal women (1,500 mg/day). Moderation in training and sound nutritional habits may prevent long intervals of amenorrhea and premature bone loss. A randomized trial investigating the role of oral contraceptives and fracture frequency is needed before recommending oral contraceptives for amenorrheic athletes.

This completed study will appear in the *American Journal of Sports Medicine*.

Supported by the University of Washington Department of Orthopaedics

Recommended Reading

Barrow GW, Saha S: Menstrual irregularity and stress fractures in collegiate female distance runners. *Am J Sports Med* 16:209-216, 1988.

Drinkwater BL, Bruemner G, Chesnut CH III: Menstrual history as a determinant of current bone density in young athletes. *JAMA* 263:545-548, 1990.

Factors Influencing Pullout Strength of Bone Screws in Porous Materials

Jens R. Chapman, M.D.
Richard M. Harrington, M.S.
Kevin Lee, M.D.
Paul A. Anderson, M.D.
Allan F. Tencer, Ph.D.

Many orthopaedic procedures employ bone screws. In several anatomic regions, such as the sacroiliac joints, the vertebral body and the femoral neck, cortical bone is not available for secure screw fixation. Although investigators have studied the mechanical properties of screws anchored in cortical bone or solid substances, only limited data exist on the pullout strength of screws anchored in cancellous bone.

Recently, screws with a cannulated shank have become available. These screws allow for initial placement of a small guide wire over which drilling, tapping, and screw insertion can be performed. Possible advantages of such a system include increased precision of screw insertion while maintaining reduction, and less bone destruction compared to that caused by standard drill bits should a change in orientation of the initial guide wire become necessary. These screws have a smaller thread volume because of the requirement for a larger shank diameter. The

effect of this diminished thread volume on pullout strength has not been well studied.

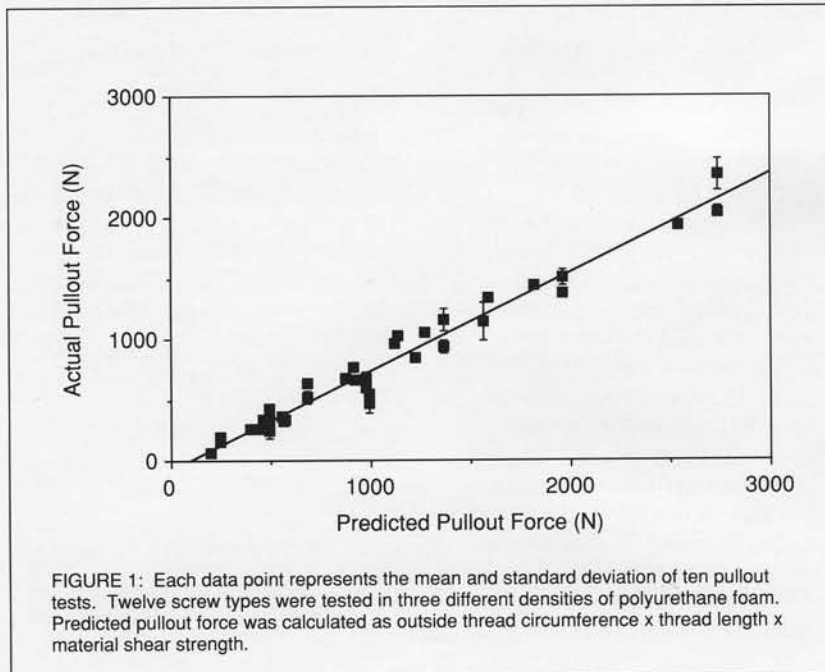
Our biomechanical study compared the pullout strength of cannulated versus standard bone screws. We also explored the effect of tapping the hole prior to screw insertion into various porous materials.

Materials and Methods

We tested 13 different cannulated and standard screw systems. Pullout strength was predicted using the formula $P = C \times L \times S$ where C = outside thread circumference (mm), L = thread length (mm), and S = shear strength (MPa) of the material in which the screw is inserted.

Comparison of screws: To standardize comparisons, we did pullout testing of all screws in polyurethane foam of three different densities in the range of human cancellous bone. A mechanical testing machine (Model 1022, Instron Corporation, Canton, MA) was used to pull ten screws of each type, each 60 mm in length and inserted to a depth of 35 mm. In addition, we compared the pullout strength of AO 6.5-mm screws with 16-mm and 32-mm thread lengths after pretapped and nontapped insertion. The shear strengths of the foam materials of different densities were assessed independently: low (L) density = 0.19 g/cm³ shear strength = 1.41 MPa; medium (M) 0.23 g/cm³ 2.78 MPa; high (H) 0.29 g/cm³ 3.89 MPa.

Screw performance in bone: Paired, thawed, fresh-frozen human cadaver specimens (two tibial plateaus, three calcanei) were decorticated and instrumented with nine of each of the following screws: AO 7.0-mm diameter, 16-mm long cannulated; AO 6.5-mm diameter, 16-mm long tapped; and AO 6.5-mm diameter, 16-mm long nontapped. We obtained the pullout data by comparing one screw type against another for exactly matching screw holes in comparable sites of the bone specimen.



Effect of tapping: The volume of material removed during preparation of tapped versus nontapped 6.5-mm screws was determined using alloy castings of the prepared holes. Tests were done with foam of three densities from human cadavers and femoral condyles and calcanei. Alloy castings standardized for length were then weighed to reflect the volume of the hole.

Results

Pullout strength was proportional to thread length and outer thread circumference. This correlation could be verified in foam of all three densities tested (Figure 1).

Cannulated and standard cancellous screws showed similar pullout characteristics in dense foam. However, contrary to our prediction, cannulated screws had significantly less pullout resistance than standard screws in low-density foam ($p=.005$, Figures 2 and 3). Similarly, AO 7.0-mm cannulated screws had a significantly decreased pullout resistance in cadaveric bone compared with AO 6.5-mm tapped ($p=0.0022$) and AO 6.5-mm nontapped ($p=0.0277$) screws.

Pullout testing of tapped versus nontapped screws did not show significant differences in high-density foam. However, tapping in low-density foam significantly reduced the pullout force required for 6.5-mm screws, compared to the nontapped comparison group. Paired testing in human cadaveric bone confirmed these findings ($p=0.0166$). The alloy casting method showed the screw holes to be significantly enlarged by tapping in all three foam densities, by 18% in low-density foam and by 34% in high-density foam ($p=0.005$). Tapping enlarged the screw holes in cadaveric bone by 16% ($p=0.0005$).

Conclusion

Overall, screw pullout correlates directly with the outer thread diameter, thread length, and material shear strength. However, cannulated screws showed reduced pullout strength compared with standard screws in low density polyure-

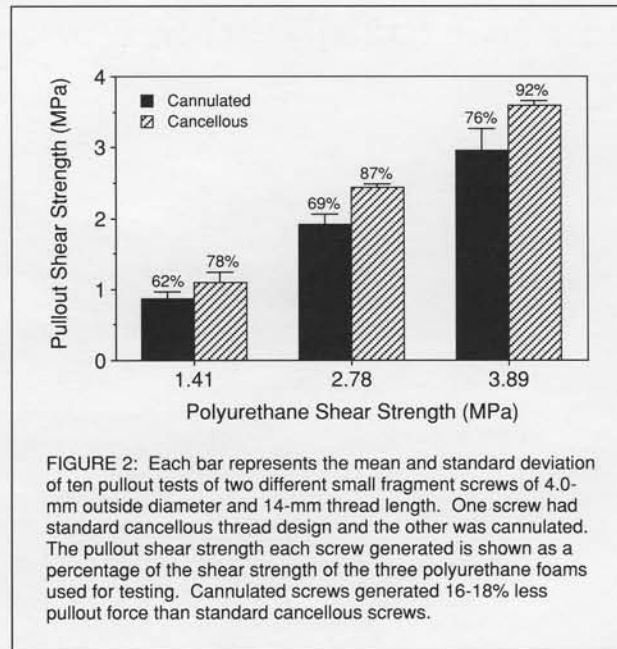


FIGURE 2: Each bar represents the mean and standard deviation of ten pullout tests of two different small fragment screws of 4.0-mm outside diameter and 14-mm thread length. One screw had standard cancellous thread design and the other was cannulated. The pullout shear strength each screw generated is shown as a percentage of the shear strength of the three polyurethane foams used for testing. Cannulated screws generated 16-18% less pullout force than standard cancellous screws.

thane and cancellous bone. This may have been related to diminished thread volume, which is determined not only by the outside thread radius but also by the shank radius.

Tapping appeared to lower pullout strength in lower density foam by increasing the screw hole volume. We conclude that maximum purchase in lower density cancellous bone is achieved without tapping and with noncannulated screws.

Supported by the University of Washington Department of Orthopaedics

Recommended Reading

Finlay J, et al: *Clin Orthop Rel Res* 247:220, 1989.

Wittenberg RH, et al: *Spine* 16:647-652, 1991.

ASTM Standard #D732-90. American Society for Testing and Materials, Philadelphia, PA.

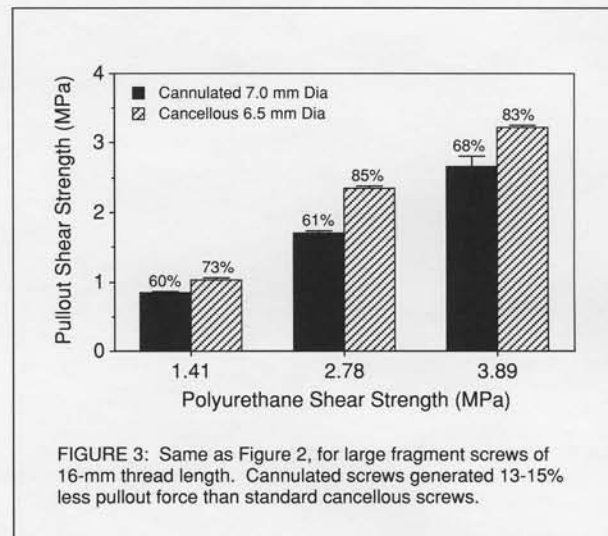


FIGURE 3: Same as Figure 2, for large fragment screws of 16-mm thread length. Cannulated screws generated 13-15% less pullout force than standard cancellous screws.

New Techniques in Fracture Stabilization

M.L. (Chip) Routt Jr., M.D.
Peter Simonian, M.D.
Richard M. Harrington, M.S.
David Senft, B.S.
Allan F. Tencer, Ph.D.
Keith A. Mayo, M.D.

Pelvic fractures continue to challenge the orthopaedic surgeon. Hemorrhage and associated injuries are responsible for most deaths, and mortality rates remain approximately 10% despite aggressive management. When the patient survives, malunion of the posterior pelvic ring may result in disabling pain.

Anatomical restoration of the pelvic ring improves functional outcome, according to Slatis and Huittinen. Hesp reported that early operative stabilization of pelvic fractures and dislocations improves patient survival. Many fixation techniques are used, yet none are without complication. Extensive surgical dissection through zones of traumatized tissues often results in wound necrosis and infection. According to Kellam, posterior pelvic exposures have infection rates as high as 25%. Simpson noted that anterior surgical approaches have fewer wound complications but safely access only the symphysis pubis and sacroiliac joint.

Controversy continues regarding the best methods and implants for treating pelvic ring fractures. Clinical attempts at closed reduction and percutaneous screw fixation of posterior pelvic ring disruptions under fluoroscopic control have been promising. Our interest is evaluating the biomechanical differences of various surgical implants used to treat symphysis pubis and sacroiliac joint disruptions; specifically, which implants are necessary and, of those, which provide the most rigid fixation.

Materials and Methods

We harvested seven fresh-frozen, unembalmed cadaveric pelvises, along with the intact lumbar

vertebrae to L4 and the proximal femora. The donors had no known skeletal disease. The stabilizing pelvic ligament complexes were preserved. For each specimen, both femora were secured with a potting compound and the pelvis was anchored with cables simulating the muscular forces that normally maintain the proper pelvic orientation. The fourth lumbar vertebra was potted to facilitate loading in the material testing machine.

Previous reports quantify physiological loads on the lumbar spine and the pelvis. Liquid metal strain gauges measured gap opening perpendicular to the sacroiliac joint and symphysis pubis. Inclinoimeters parallel to the sacroiliac joints measured flexion or extension of the sacrum with loading. Loads simulating compression, forward flexion, lateral bending, and rotation were sequentially applied to each pelvis. Testing was carried out in the intact pelvis, after disruption of stability and after different fixation methods. The sequence of testing was:

1. Intact pelvis
2. Symphysis pubis disruption
3. Unilateral anterior sacroiliac joint disruption
4. Ipsilateral sacrospinous and sacrotuberous ligaments division
5. Symphysis pubis fixation with a 4.5-mm DC plate, according to the technique of Lange and Hansen
6. Plate fixation of the sacroiliac joint, according to the technique of Simpson, along with pubis plating
7. Lag screw fixation of the sacroiliac joint, according to the technique of Matta, along with pubis plating
8. Plate fixation of the sacroiliac joint, without pubis plating
9. Lag screw fixation of the sacroiliac joint, without pubis plating.

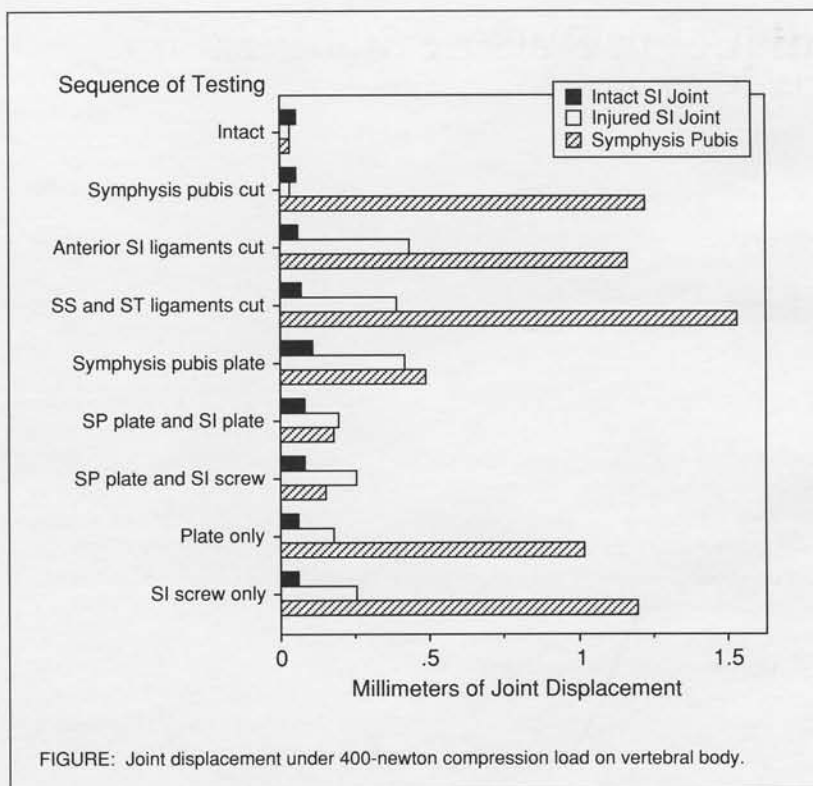
Results

The intact pelvic specimens demonstrated minimal changes with loading. Significant symphyseal displacements occurred with compression loading after symphysis pubis disruptions. In these specimens, the intact sacroiliac joint remained normal. With additional division of the anterior sacroiliac joint ligaments, both the joint and symphysis pubis demonstrated significant instabilities. Further disruption of the ipsilateral sacrotuberous and sacrospinous ligament complex produced some additional instability to compression loading (Figure).

Plate fixation of the symphysis pubis alone stabilized the symphysis pubis, but the motion at the disrupted sacroiliac joint was not decreased. The addition of either a plate or a lag screw across the disrupted joint significantly stabilized both the pubis and joint. There was no gross difference in stability achieved with the plate or lag screw as long as the symphysis remained fixed with the plate. Removal of the symphyseal plate and fixation of the sacroiliac joint using either a plate or lag screw destabilized the symphysis significantly while the joint remained stable to compression loading. The contralateral normal sacroiliac joint demonstrated no changes during all phases of compression testing.

Discussion

Operative reduction and fixation of a displaced pelvic fracture provides pain relief, allows patient mobilization, and improves both survivability and outcome. Various methods of fixation are advocated, yet none is ideal. Symphyseal plating contributes to the overall pelvic stability. Plate or screw fixation of the dis-



rupted sacroiliac joint adds stability. Biomechanically these two implants demonstrate no significant differences. In a clinical setting, the sacroiliac plate requires an anterior surgical exposure, and the lag screw can be placed percutaneously. We conclude that both anterior and posterior pelvic ring fixation should be used to maximally stabilize the pelvis against compression loading when the symphysis pubis and sacroiliac joint are disrupted.

Supported by the University of Washington Department of Orthopaedics

Recommended Reading

Kellam JF, et al: *Orthop Clin North Am* 18:25-41, 1987.

Lange RH and Hansen ST Jr: *Clin Orthop Rel Res* 201:130-137, 1985.

Matta J, Bray T: *Orthopaedic Knowledge Update* 3:477-493, 1990.

Simpson LA et al: *J Trauma* 27:1332-1339, 1987.

Slatys P and Huitennnen VM: *Acta Chir Scand* 138:799-807, 1972.

Intramedullary Reaming: Changes Over 25 Years

Sigvard T. Hansen Jr., M.D.

Intramedullary nailing of long bones, particularly of the femur and tibia, has steadily gained popularity among traumatologists worldwide over the last ten years. However, reaming the medullary canal is accompanied by serious risks from local complications in tibial fractures, and from systemic complications, including death, in femoral fractures.

The Tibia

It has long been recognized that reaming is poorly tolerated by the tibia. The medullary anatomy of the tibia can vary in shape from a long, uniform cylinder to an hourglass. Dense cortical bone in the mid-diaphysis is vulnerable to mechanical and thermal damage from reaming. If the tibia has a particularly small canal and a long, cylindrical shape, the reamer begins to bite into cortical bone proximally and becomes very hot as it moves into the distal tibia due to continued contact with hard, cortical bone.

The tibia has relatively poor muscle coverage throughout its course. In the distal tibia, the posterior lateral muscle compartments get thinner and thinner, and the amount of heat "sink," or the ability of the soft tissues to dissipate the heat, becomes progressively less. In severe tibial

fractures, surrounding soft tissues are stripped from the bone, further lessening their ability to dissipate heat.

The use of a tourniquet during reaming further restricts the intramedullary circulation and eliminates its cooling effect. Therefore, the combination of a severe tibial fracture with a small canal and insufficient soft-tissue coverage predisposes to risks of serious thermal damage, slow union, necrosis, and sequestration of the shaft.

These difficulties with tibial reaming are so severe that the trend is now to avoid tibial reaming altogether in acute, high-energy fractures. The prereamed nail is replaced with a small, solid or thick-walled intramedullary nail that can be inserted without reaming. This device can be locked to resist torsional forces, facilitating the maintenance of anatomical length and rotation.

The Femur

The femur is less vulnerable to local complications from reaming. Although a limited amount of necrosis occurs in the areas of the bone contacted by the reamer, it is apparently well tolerated. Unlike the situation of the tibia, clinically significant, full-thickness bony sequestration of the femur is rare.

In patients with compromised pulmonary function, femoral nailing of an unstable femoral fracture often is indicated to break the cycle of events that further damage pulmonary function. If traction is used and the patient immobilized and supine, the lungs are steadily showered with fat and other debris

from the unstabilized fracture. Lack of fracture immobilization, on the other hand, causes significant pain that requires successive narcotic medication, which further impacts pulmonary function. Stabilization with intramedullary nailing allows a patient to assume the upright position comfortably and minimizes the need for narcotics.

While femoral nailing is often the best way to mobilize patients with pulmonary compromise, pulmonary complications of nailing must be avoided. A preoperative arterial PO_2 reading is required in severely injured patients to ensure adequate oxygenation. The anesthesiologist needs to be aware of any intrinsic injury to the patient's lungs.

In a severely compromised patient, an unreamed nail may be preferred. In general, however, careful reaming can be carried out if certain precautions are observed. The primary problem to avoid is the production of high, intraosseous pressure, which forces fat and other debris into the venous circulation where it is embolized to the lung. This is particularly a problem in fractures to the upper third of the femur, where the reaming of the long distal segment (which may include the entire isthmus) can produce the same effect as reaming an intact femur. "Venting" the distal femur through the insertion of a suction drain in the distal medial metaphysis is helpful in avoiding this problem.

Use of a sharp reamer with deep flutes and a tapered tip connected to a smaller shaft allows efficient cutting of the bone and passage of the debris by the reamer head and up the medullary canal. The reamer needs to be advanced slowly, allowing the medullary contents to move past. When cutting resistance is encountered, the size of the cutting head should be increased by the smallest possible increment. If a pressure sensation is noted, the

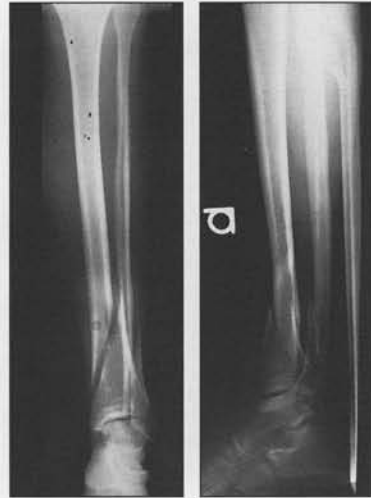flutes must be cleaned frequently and the debris removed from the distal fragment by suction during reaming. We have used these guidelines in more than 1,000 femoral nailings and have rarely encountered problems with pulmonary complications.

In summary, intramedullary stabilizations of the femur and tibia have proven to be excellent adjuncts to the care of multiply injured patients. Local complications due to reaming of the tibia are avoided by using unreamed nails. The systemic complications of femoral reaming are avoided by using sharp, properly designed reamers and appropriate technique with decompression of long distal segments. Attention to these details can provide the benefits of medullary fixation, while avoiding the potential risks.

Supported by the University of Washington Department of Orthopaedics

A Case Study

A 40-year-old nurse, a small Caucasian woman, sustained a low-energy fracture with rotation while skiing.



FIGURES 1A & B: AP and lateral radiographs show the fracture is quite distal for nailing and, more importantly, the bone has a very long, narrow, cylindrical medullary canal that is a maximum of 5 to 7 mm wide and 12 to 15 cm long.

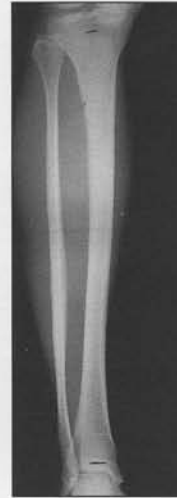
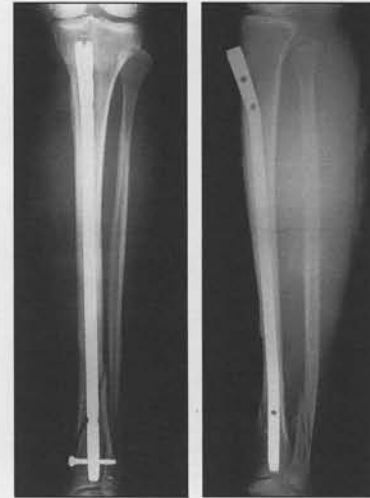
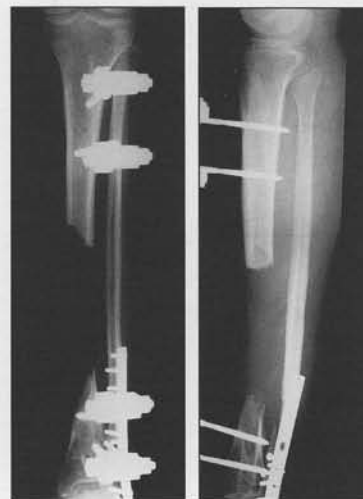
FIGURE 2: A radiograph of the opposite leg confirms the unusual medullary canal in a relatively small tibial bone.



FIGURES 3A & B: Postoperative AP and lateral radiographs show a low starting point of a 10-mm nail but, more importantly, the marked thinning of the anterior cortex in the distal half of the isthmus. Reamers of 9, 9.5, 10, and 10.5 mm have been used as the smallest reamer available was the 9-mm end-cutting reamer. Using this reamer in a canal that was 2 to 3 mm smaller than its diameter meant cutting this thickness of cortical bone through a good portion of the isthmus, which was almost 15 cm long. Although the surgeon did not commit any major error, such as using dull reamers or a tourniquet, and did not note unusual heat or resistance passing this reamer, this long length of hard cortical contact with the initial reamer would have produced considerable heat by the time it reached the lower third of the tibia, just where the overlying soft tissues and potential heat sink would be the most limited.

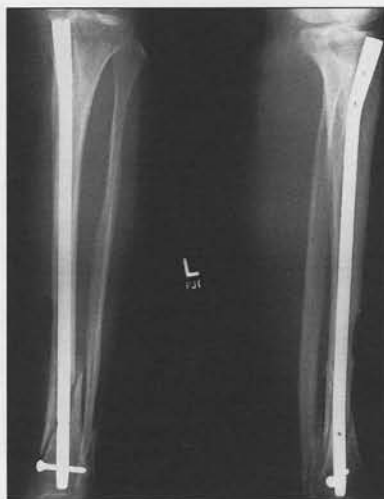

FIGURE 4: AP and lateral radiographs at three months. The patient had immediate postoperative symptoms similar to a compartment syndrome with partial paresis, hyperesthesia, pain, and swelling. Careful measurements in all compartments showed no significant abnormal pressure readings. However, on day 3 postop a blister appeared over the anterior tibia about 2 inches proximal to the fracture site. Eventually, a full-thickness, 5-cm by 2-cm slough of soft tissue occurred with apparent dead bone in its base. The lateral radiograph shows lysis of bone about 2 inches proximal to the fracture site and over the center of the lower half of the long isthmus noted on the original bone, also in the anterior surface, the site of greatest thinning.



FIGURES 5A & B: Exploratory surgery at six months revealed 10 cm of completely necrotic bone and a 1-cm circumferential sleeve of necrotic soft tissue. After debridement of all necrotic tissue, an early attempt at stabilization was made but within weeks the patient requested a BK amputation. This clearly was a problem of thermal necrosis due to the long, narrow medullary canal. The maximum reaming in any area should be less than one-half of the cortical thickness. The other obvious treatment option, without this risk, would have been a simple plating of the tibia and fibula. A careful analysis of bony anatomy and a full range of well-designed reamers and proper technique are required for selection of pre-reamed tibial nails as an acute treatment.

The Epidemiology of Seatbelt-Associated Injuries

Paul A. Anderson, M.D.

The last decade has witnessed several important developments in motor vehicle occupant protection. Federal motor vehicle safety standards now require all passenger cars to be equipped with lap/shoulder harness systems for front seat passengers and lap belts for rear seat passengers. Thirty-four states have laws requiring front seat occupants and/or all passengers to use seatbelts. Consequently, seatbelt use in the United States has increased dramatically in the last three years and is now approximately 42% nationally.

Currently available restraint systems significantly decrease the risk of injury in collisions, particularly frontal collisions. Seat restraints have been estimated to decrease fatalities in collisions by 40% to 45% overall, and to decrease fatalities in rear seats by approximately 18%. Among non-fatal crash

victims, restrained occupants have less severe injuries than nonrestrained occupants and lower costs for care. Seat restraints do not eliminate the risk of injury completely, however. Lap belt use has been associated with an apparent increased risk of certain types of injuries, including bowel and mesenteric injuries and lumbar spine injuries. Lap/shoulder harness-type restraints have been associated with aortic, pancreatic, and cardiac injuries.

In 1986, seatbelt use became mandatory in Washington State. Since then, we have observed an increase in Chance-type fractures and abdominal injuries. To accurately assess this observation, we performed an epidemiologic study that examined the association of spine and abdominal injuries with restraint use among all patients admitted to Harborview Medical Center for the care of motor vehicle trauma. In addition, we assessed the increase of these injuries as related to the concurrent increase in seat restraint use nationwide.

Methods

This study retrospectively examined all patients admitted to Harborview Medical Center from 1984 to 1988 for treatment of spine and/or abdominal injuries sustained by motor vehicle occupants. Abdominal injuries affected the small intestine, colon, spleen, kidney, liver, pancreas, mesentery, bladder, uterus, and any vascular structure within the abdominal cavity. Spinal fractures were classified according to the three-column theory of Denis. Seatbelt-related injuries were considered as either Chance fractures or flexion distraction injuries.

Seatbelt use data was obtained from the National Highway Traffic Safety Agency, the National Accident Sampling System, the Washington State Traffic Safety Commission, and from the review of the patients' medical records.

TABLE 1: Demographic Characteristics of Study Population

	Number 303	Percent 100
Sex		
Male	189	62.4
Female	114	7.6
Age (years)		
<14	18	5.9
15-44	233	76.9
45-65	32	10.6
>65	20	6.6
Seat Position		
Front	205	67.7
Back	39	12.9
Unknown	59	19.5
Belt Use		
None	184	60.7
Lap/shoulder	42	13.9
Lap	25	8.3
Child's restraint	1	0.3
Restrained, type unknown	13	4.3
Unknown	38	12.5

Results

The study included 303 patients with spine and/or abdominal injuries (Table 1). The male to female ratio was 1.7:1. Only 6% were children and 6.7% were 65 years of age or older. Two-thirds of patients were front seat occupants, 13% rear seat, while seat position was unknown in 19%. Drivers accounted for 83% of front seat occupants.

Sixty-one percent of patients did not use restraints. Fourteen percent used lap/shoulder harnesses and 8.3% used lap belts alone. Child restraints were used in 0.3% of cases. The use of restraints was unknown in 17% of cases.

Spinal injuries were distributed equally in cervical, thoracic, lumbar, and sacral regions (Table 2). Although the frequency of spine injury did not increase, the number of Chance-type fractures rose in the last two years of the period studied. In 1988 Chance-type fractures accounted for 15.5% of spinal injuries, compared to 6.5% in 1986 and 0% in 1984-85.

Spine injury was strongly associated with seat position (Figure 1). Patients with Chance-type fractures were eight times more likely to be rear-seated than those with cervical spine injuries, and 6.7 and 3.1 times more likely than those with thoracic and other lumbar spine injuries, respectively. The type of injury also was associated with the use and the type of restraint. Nearly 86% of patients with cervical injuries were unrestrained; in contrast, 82% of patients with Chance-type fractures were restrained. In respect to the type of restraint, no patients with cervical or thoracic spine injuries were wearing lap belts alone, compared to 62.5% of those with Chance-type fractures.

Similarly, seat position, use of restraint, and restraint type significantly affected the chance of small and large bowel injuries (Figure 1). Patients in the rear seat and restrained by lap belt alone were significantly more likely to sustain these injuries than injuries to the solid viscera.

Perhaps the most alarming results were found in children. Six of seven children with Chance-type

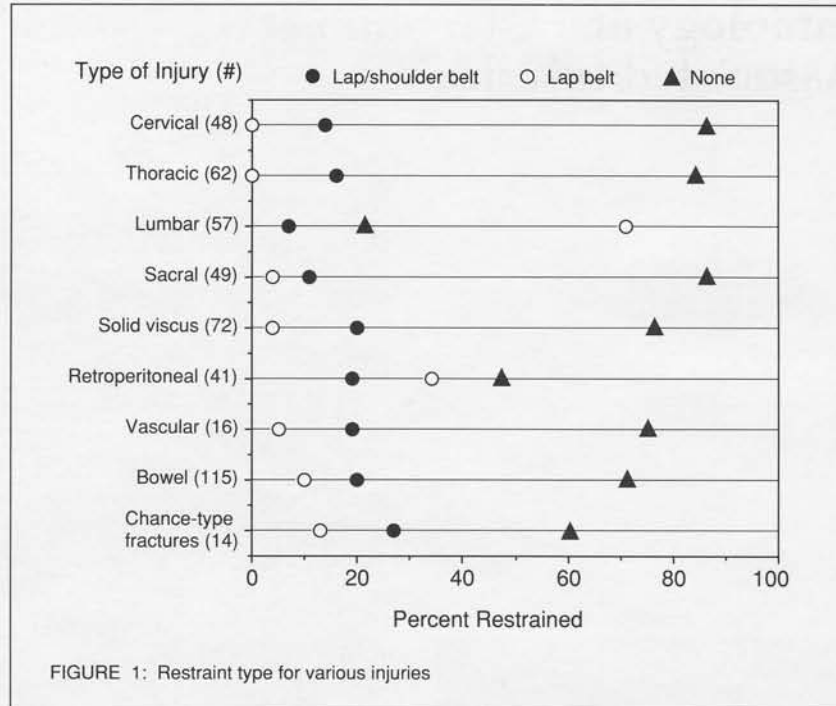


FIGURE 1: Restraint type for various injuries

fractures had concomitant bowel injury and all were rear-seated and wore only lap restraints (Figure 2).

Nationally, in Western Washington and in Seattle, seatbelt use increased dramatically from 1982 to 1988 (Figure 3, page 32). Similarly, the use of restraints as observed at accident scenes also has increased. Accident surveys showed an increase in lap belt use from 2% to 4% from 1982 to 1988. Lap/shoulder restraint use increased dramatically from 5% to 33%.

Discussion

This study confirms our suspicion that we have observed an increase in hollow viscus and Chance-type injuries with increased restraint use. The mechanism of injury is similar, accounting for these observations. Our results in Seattle were consistent with national trends that document similar increases in hollow viscus and thoracolumbar spine fractures. Occupants who wear only a lap belt restraint are at risk for seatbelt-related injuries.

Despite these observations, we continue to strongly recommend the use of restraint systems. This study should be not interpreted as implying that seatbelts are harmful. Rather, we

point out that current systems, especially rear seat lap belts alone, are inadequate. Fortunately, the federal government has mandated the installation of three-point restraints in rear seats of all automobiles produced since 1990. This still leaves
(continued on page 32)

TABLE 2:
Spinal and Abdominal Injuries

	Number
Spinal Injuries	
Cervical	59
Thoracic	71
Lumbar	70
Lumbar Chance-type	10
Sacral	64
Abdominal Injuries	
Bowel	106
Solid Viscus	87
Retroperitoneal	51

Residual Motion After Glenohumeral or Scapulothoracic Arthrodesis

Eric David Walker, B.S.
Douglas T. Harryman II, M.D.

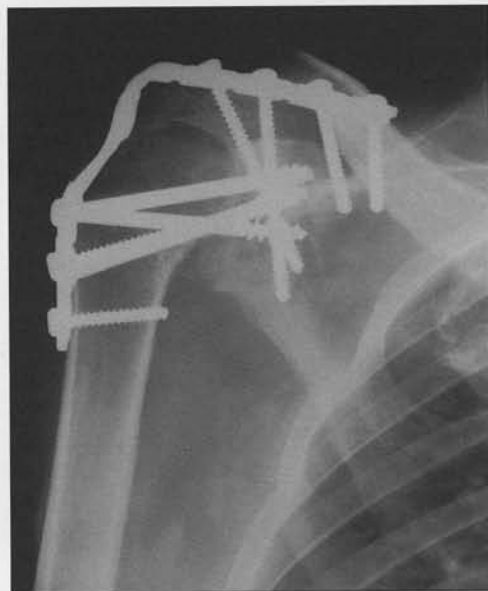

FIGURE 1: Glenohumeral fusion performed because of refractory damage to the rotator cuff and deltoid. Compression screws and a neutralization plate provide excellent initial stability.

Shoulder motion, the motion between the humerus and the thorax, is a composite of the motion at the glenohumeral (Figure 1) and scapulothoracic (Figure 2) articulations. Arthrodesis of one or the other of these articulations is occasionally required. The degree of motion in the remaining joint after one of these two types of fusions has not been rigorously determined.

Our study compared the humerothoracic motion in the remaining joint after a glenohumeral or scapulothoracic fusion with the motion of the same joint in the normal shoulder. The purpose of this study was to determine if fusion was associated with a compensatory increase or a decrease in residual motion.

We measured the motion of the shoulder using a six-degree of freedom position sensing system developed at the University of Washington Department of Orthopaedics by Dr. John A. Sidles. The total angle of elevation achievable is influenced by the plane in which the arm is elevated. To specify the plane of elevation, we refer to the coronal plane as the 0° plane. Anterior elevation in the sagittal plane is elevation in the +90° plane, and posterior elevation in the sagittal plane is in the -90° plane.

We compared the motions in eight normal subjects with those of 12 shoulders that had glenohumeral arthrodesis and seven shoulders that had scapulothoracic arthrodesis. In normal subjects, the glenohumeral and scapulothoracic motions were measured by pinning sensors to the humerus and to the scapula. In the patients with arthrodeses, measurement of motion at the single residual joint required the attachment of the sensor to the humerus only.

In the normal subjects, elevation in the +90° plane averaged 147±15°. The scapulothoracic component of that motion averaged 57° and the glenohumeral component 91°. In the patients with glenohumeral arthrodeses, elevation in the +90° plane was limited to 47°. In shoulders with scapulothoracic arthrodeses elevation in the +90° plane averaged 93°. These numbers were comparable to the values for the two respective components of motion in the normal shoulders.

Similarly, elevation in the -90° plane averaged 74±12° in normal shoulders. The scapulothoracic component averaged 21° and the glenohumeral component averaged 58°. In the patients with glenohumeral arthrodeses, the elevation in the -90° plane averaged 22° and in the patients with scapulothoracic arthrodeses it averaged 35°. Again, these values are comparable to the component motions of the normal shoulder.

External rotation averaged 65° in the normals, with an average of 16° at the scapulothoracic and 51° at the glenohumeral joint. Patients with glenohumeral arthrodeses averaged 9° of external rotation and those with scapulothoracic arthrodeses averaged 33°.

Finally, internal rotation averaged 78° for normal shoulders. The scapulothoracic component averaged 25° and the glenohumeral component averaged 70°. Patients with glenohumeral arthrodeses averaged 46° and those with scapulothoracic fusions averaged 60°.

Despite the relatively small sample sizes, these results indicate that the residual shoulder motion after a glenohumeral or a scapulothoracic arthrodesis is essentially that of the unfused joint in a normal shoulder. Since the normal motion at the glenohumeral joint is substantially greater than that at the scapulothoracic joint, it can be predicted that patients with glenohumeral arthrodeses would be substantially more compromised from a functional standpoint than those with scapulothoracic fusions.

An analysis of the function of shoulders with fusions confirmed this prediction. All patients with scapulothoracic fusions were able to reach their mouth, side pocket, back pocket, perineum, and groin. All but one could reach their axilla and their back, and all but two could reach their hair. In marked contrast, of the 12 patients deprived of glenohumeral motion, 11 lost the ability to reach their hair and back, seven lost the ability to reach their perineum, and six lost the ability to reach the back pocket, five the axilla, and two the side pocket.

In conclusion, this study is the first to measure in six degrees of freedom the in vivo glenohumeral and scapulothoracic motions in normal subjects and subjects with glenohumeral or scapulothoracic arthrodeses. It demonstrates that, to a large degree, the motion of the residual joint after an arthrodesis can be predicted from a knowledge of the two component motions of the normal shoulder. It demonstrates that the scapulothoracic joint is an important contributor to the normal range of motion of the arm, and that glenohumeral motion is essential for some of the important activities of daily living.

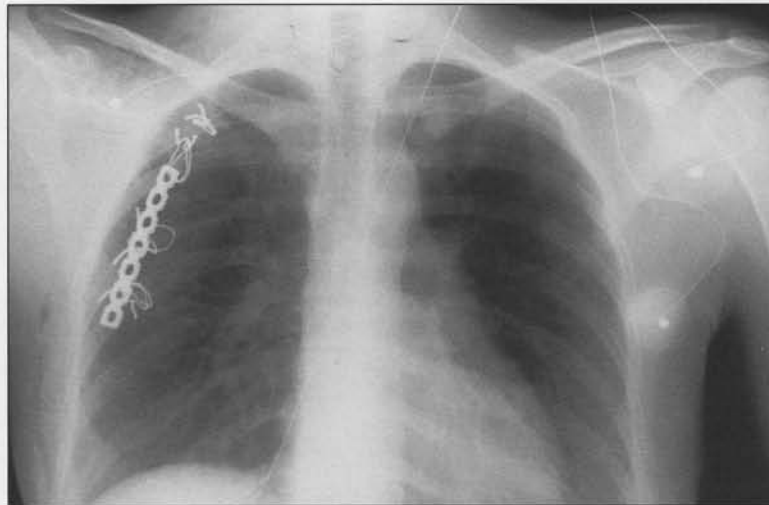


FIGURE 2: Scapulothoracic fusion performed because of shoulder girdle weakness from scapulo-humeral muscular dystrophy. A plate is used to buttress and secure the medial scapular border to the ribs using circlage wires. Bone graft assists the fusion of the scapula to the ribs.

Supported by the University of Washington Department of Orthopaedics

Recommended Reading

Harryman DT II, Sidles JA, Harris, SL, Matsen FA III: Laxity of the normal glenohumeral joint: A quantitative in vivo assessment. *J Shoulder Elbow Surg* 1:66-76, 1992.

Harryman DT II, Sidles JA, Matsen FA III: The role of the rotator interval capsule in passive motion and stability of the shoulder. *J Bone Joint Surg* 74A(1):53-66, 1992.

Harryman DT II, Sidles JA, Clark JM, McQuade KJ, Gibb TD, Matsen FA III: Translation of the humeral head on the glenoid with passive glenohumeral motions. *J Bone Joint Surg* 72A:1334-1343, 1990.

Glenohumeral Stability from Concavity-Compression

A Quantitative Analysis

Steven B. Lippitt, M.D.
J. Eric Vanderhooft, M.D.
Scott L. Harris, B.S.
John A. Sidles, Ph.D.
Douglas T. Harryman II, M.D.
Frederick A. Matsen III, M.D.

The mechanisms by which the glenohumeral joint is stabilized in the mid-range of motion have not been well defined. In the mid-range, the ligaments and capsule are lax and cannot exert major stabilizing effects. The rotator cuff is ideally situated to compress the humeral head into the concave glenoid fossa in the mid-range of motion. However, the glenoid is only one-fourth the articular surface of the humeral head and provides a much more shallow socket as compared to the acetabulum of the hip joint.

The purpose of this research is to determine the degree to which compression of the humeral head into the

glenoid concavity stabilizes it against translating forces. Given that the anatomy of the glenoid fossa changes around its circumference, we also investigated the differences in compression stabilization for different directions of displacement. Finally, we investigated the effects of labral resection on the efficiency of compression stabilization.

Methods

We studied ten normal, fresh-frozen, cadaver glenohumeral joints in which the labrum was preserved but the tendons and capsule were resected. With minimal load applied, the humeral head was translated from the center of the glenoid to the glenoid edge, from superior to inferior, and from anterior to posterior. The lateral displacement of the humeral head plotted as a function of the translation away from the glenoid center in the given direction provided a measure of the effective depth of the glenoid concavity.

We applied a compressive load of 50 newtons to the humeral head

in a direction normal to the glenoid surface. We then applied increasing translation forces tangential to the glenoid surface until the head dislocated over the glenoid lip. The translation force at dislocation was recorded for eight different directions 45° apart (superior, antero-superior, anterior, etc.). Finally, the entire protocol was repeated after the glenoid labrum was excised flush with the articular cartilage.

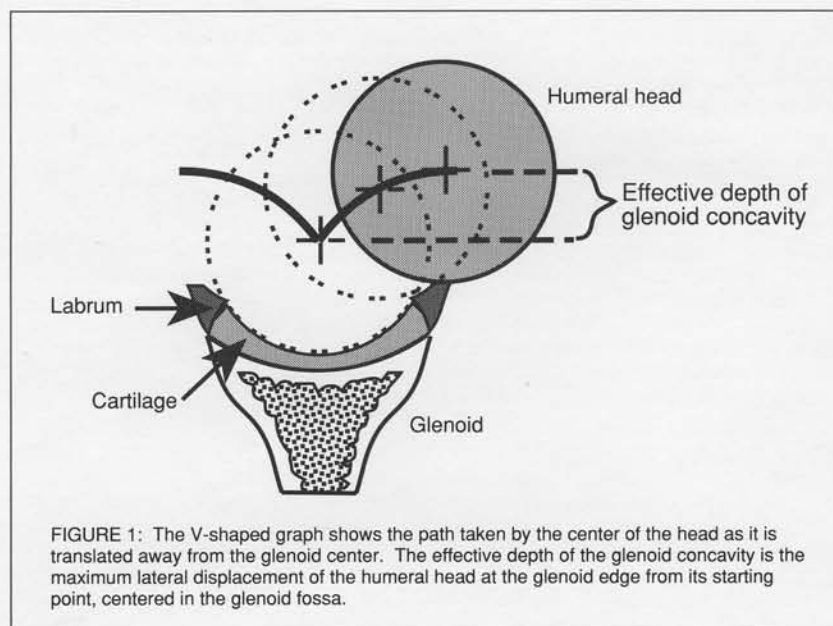
Results

The lateral displacement of the humeral head as it rode up the surface of the glenoid concavity was plotted as a function of the translation in a given direction away from the glenoid center, creating a V-shaped graph (Figure 1). This graph represented the changing slope of the glenoid concavity that was in contact with the humeral head. The effective depth of the concavity was given by the maximum lateral translation of the humeral head at the glenoid edge compared to the starting point at the glenoid center. This effective depth of the glenoid concavity was always greater in the superior-inferior (0°-180°) direction than in the anterior-posterior (90°-270°) direction, as seen for a typical shoulder in Figure 2.

With the applied compressive load of 50 newtons, we observed a sudden dislocation of the humeral head as the translation force was increased beyond a threshold level. To quantify this limit of the glenohumeral stability, we computed a "stability ratio" as follows:

$$\text{Stability ratio (\%)} = \frac{\text{translation force at onset of dislocation}}{\text{compressive force}} \times 100$$

Higher stability ratios reflect greater degrees of stability from concavity-compression. Figure 3 shows the average stability ratios for the intact labrum and the labrum-excised glenoid preparations with a 50-newton compressive load. Note that with the labrum intact, the stability ratio was as high as 64% for some directions of translation force; that is, when compressed into the glenoid concavity, the humeral head



resisted a translation force up to 64% of the compressive load (Figure 3A).

Resection of the glenoid labrum reduced the stability ratio (effectiveness of concavity-compression stabilization) for each direction (i.e., 0°, 45°, 90°, etc.) for the 50-newton compressive load (Figure 3B). The percent reduction in stability by labrum resection was variable, with an average of approximately 20%.

Compression stabilization was more effective in the superior and inferior plane than in the anterior or posterior plane, due to the greater glenoid depth in the former direction. In contrast, we found no significant difference between superior and inferior directions, nor between the anterior and posterior directions for stability ratio.

Conclusions

Our study investigated the stabilizing role of concavity-compression at the glenohumeral joint. The results indicate that compression of the humeral head into the concave glenoid fossa can effectively stabilize the articulation in the mid-range where the capsule and ligaments are lax. The greater the glenoid concavity, the greater the stability of the humeral head to translation forces, with the greatest stability in the superior-inferior direction. The effectiveness of this mechanism is significantly decreased by the absence of an intact glenoid labrum.

This research suggests that the stability of the glenohumeral joint may be compromised in directions where the labrum is torn. Stability

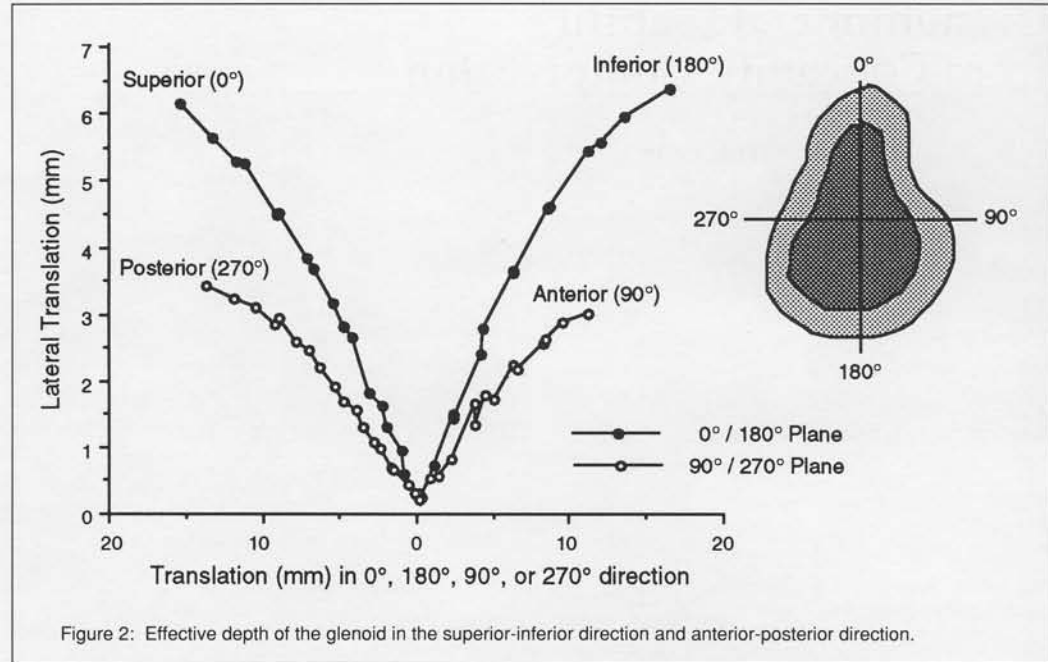


Figure 2: Effective depth of the glenoid in the superior-inferior direction and anterior-posterior direction.

also may be compromised in all directions when the glenoid surface is relatively flat, when the labrum is small or less firm, when the muscular compressive force is imbalanced or eccentrically applied into the glenoid, and when the glenoid concavity does not stay properly aligned to the humeral head. Repair of the glenoid labrum in a manner that reestablishes the concavity may be important to restoring glenohumeral stability after traumatic dislocation.

Supported by the University of Washington Department of Orthopaedics

Recommended Reading

Cooper DE, Arnoczky SP, O'Brien SJ, et al: Anatomy, histology, and vascularity of the glenoid labrum. An anatomical study. *J Bone Joint Surg* 74(A):46-52, 1992.

Flatow E L, Soslowsky LJ, Ateshian GA, et al: Shoulder joint anatomy and the effect of subluxations and size mismatch on patterns of glenohumeral contact. *Orthop Trans* 15(3):803-804, 1991.

Howell SM, Galinat BJ: The glenoid-labral socket. A constrained articular surface. *Clin Orthop Rel Res* 243:122-125, 1989.

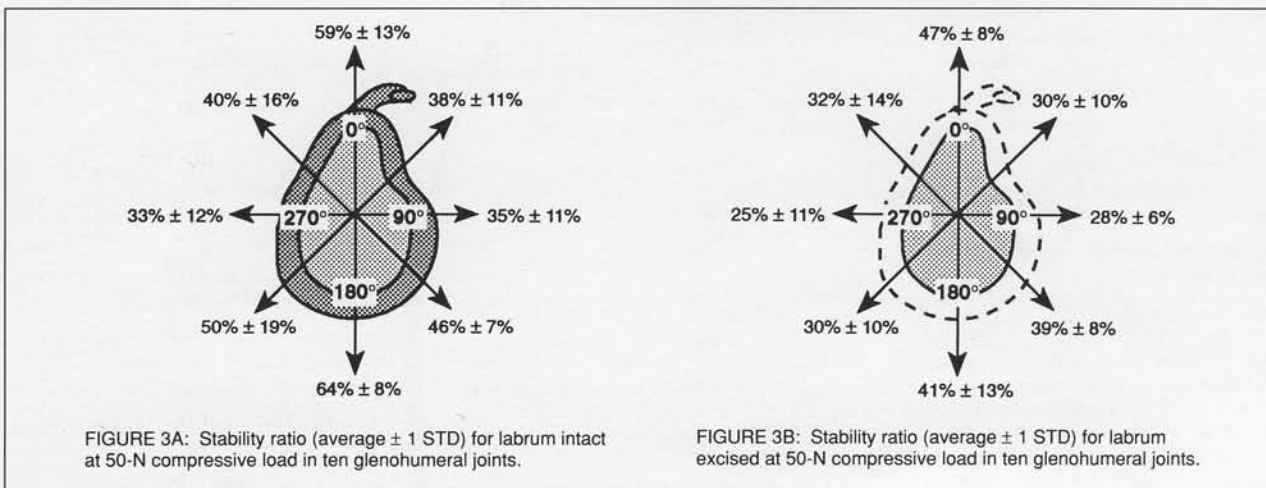


FIGURE 3A: Stability ratio (average \pm 1 STD) for labrum intact at 50-N compressive load in ten glenohumeral joints.

FIGURE 3B: Stability ratio (average \pm 1 STD) for labrum excised at 50-N compressive load in ten glenohumeral joints.

Seatbelt Injuries (from page 27)

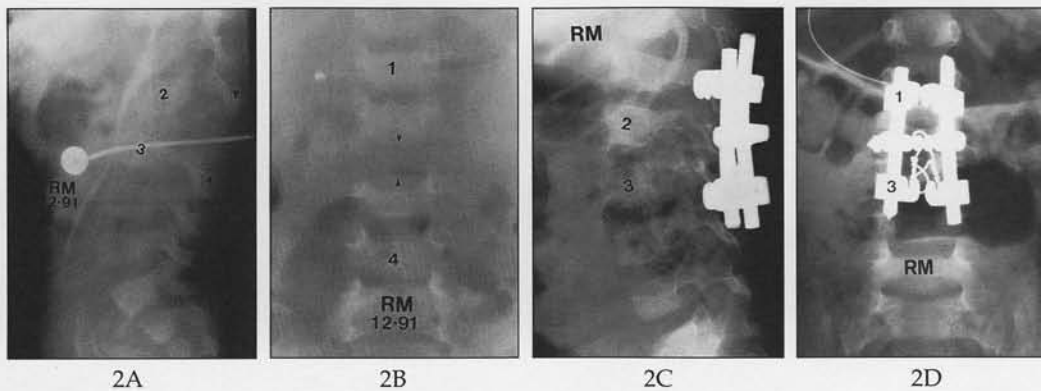


FIGURE 2A: Lateral lumbar radiograph of two-year-old boy who sustained L2/3 Chance fracture with complete T10 paraplegia and bowel perforation. He was rear seat passenger wearing a lap belt and no child restraint in an automobile involved in head-on collision.

FIGURE 2B: Anteroposterior lumbar radiograph demonstrating diastasis between L2 and L3. At surgery the neural elements and dura were ruptured and unreparable.

FIGURES 2C-D: Treatment with pediatric CD rods and posterior lateral fusion L1 to L3.

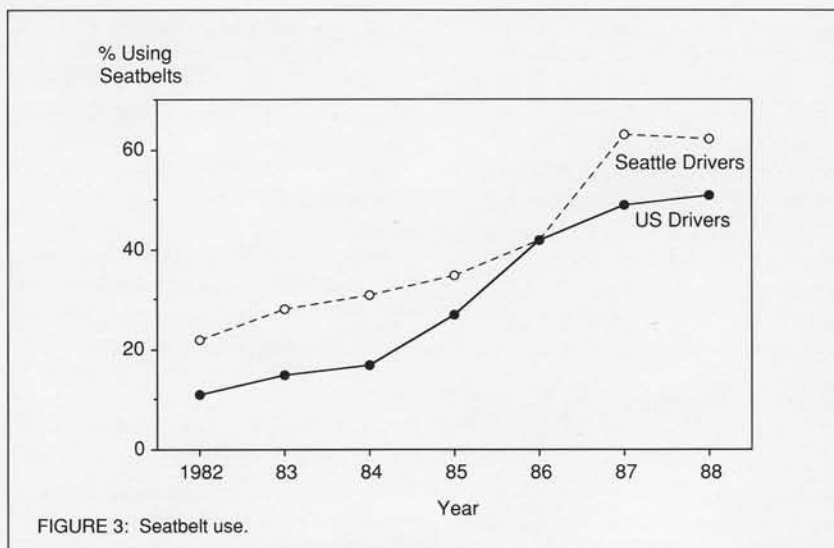


FIGURE 3: Seatbelt use.

the problem of the many automobiles that have inadequate restraint systems manufactured before 1990. Also, when children wear the current lap/shoulder systems designed for adults, the shoulder harness often crosses the neck or is held under the shoulder, which increases the risk of injury. We believe that the engineering and design of these restraints should be improved to better distribute crash forces, particularly for smaller and younger occupants.

Supported by the Harborview Injury Prevention and Research Center, and the federal Center for Disease Control

Recommended Reading

Anderson PA, Rivara FP, Maier RV, Drake C: The epidemiology of seatbelt-associated injuries. *J Trauma* 31: 60-67, 1991.

Budorick TE, Anderson PA, Rivara FP, Cohen W: Chance-type fracture of the cervical spine: A case report. *J Bone Joint Surg* 73:1097-1100, 1991.

Anderson PA, Henley MB, Rivara FP, Maier RV: Flexion distraction and Chance injuries to the thoracolumbar spine. *J Orthop Trauma* 5:153-160, 1991.

Tibia Vara (from page 11)

these measurements be used to identify patients who could be observed or treated non-operatively for a longer period. Infantile tibia vara must be observed closely, and treatment begun at a young age when the disease is in its early stages to achieve the best long-term results.

TABLE 2: Final Results for Each Langenskiöld Stage

Stage	Percent		
	Good	Fair	Poor
I	50	50	0
II	40	48	12
III	12	35	53
IV	0	50	50
V	0	0	100
VI	0	0	100

Recommended Reading

Levine AM, Drennan JC: Physiological bowing and tibia vara. *J Bone Joint Surg* 64A:1158, 1982.

Langenskiöld A, Riska EB: Tibia vara (osteochondrosis deformans tibiae). *J Bone Joint Surg* 46A:1405, 1964.

Loder RT, Johnston CE: Infantile tibia vara. *J Pediatr Orthop* 7:639, 1987.

Schoenecker PL, et al: Blount's disease: A retrospective review and recommendations for treatment. *J Pediatr Orthop* 5:181, 1985.

Salenius P, Vankka E: The development of the tibiofemoral angle in children. *J Bone Joint Surg* 57A:259, 1975.

Smith CR: Tibia vara (Blount's disease). Current concept review. *J Bone Joint Surg* 64A:630, 1982.

Ringling to a single proton's magnetic nudge

A proton behaves as if it were a miniature bar magnet twirling like a top. This combination of spin and magnetism has permitted researchers to develop a variety of sophisticated techniques — based on a phenomenon known as nuclear magnetic resonance — for determining the composition and structure of molecules in pure samples and for picturing complex processes such as blood flow through the heart.

A medical physicist has now suggested an alternative, potentially more sensitive means of extracting information from a nuclear magnetic resonance experiment. His calculations show that, under the proper conditions, a single proton's interaction with a magnetic field may be strong enough to set a nearby, microscopic sliver of quartz quivering in much the same way that a tuning fork begins to ring when bathed in sound waves of just the right frequency. By monitoring these induced vibrations, researchers could, in principle, detect and locate single protons deposited on a surface.

"It turns out that the predicted signal levels are well above quantum and [thermal] noise limits," says John A. Sidles of the orthopedics department at the University of Washington School of Medicine in Seattle. Although little is known about fabricating mechanical oscillators small enough to work in such an experiment, the technique may eventually allow the imaging of individual biological molecules — a level of resolution not possible with conventional magnetic resonance imaging.

"Sidles' idea is kind of revolutionary in the field [of nuclear magnetic resonance imaging]," says physicist Myer Bloom of the University of British Columbia in Vancouver, who studied a related effect in the 1960s. "I don't see why the idea shouldn't be right, but I'm not completely sure that the claimed sensitivity can be achieved."

Sidles presents the theoretical basis of his proposed technique in the Feb. 24 *PHYSICAL REVIEW LETTERS*. Through a quirk of the review process, a subsequent paper describing possible designs for such a detector appeared last summer in the June 17 *APPLIED PHYSICS LETTERS*.

Sidles' scheme ingeniously combines nuclear magnetic resonance techniques with the kind of technology that made possible both the scanning tunneling microscope and the atomic force microscope (SN: 4/1/89, p.200; 2/29/92, p.135). Already used to measure tiny variations in magnetic force across a surface, these scanning methods — when further refined

A single proton sitting on a quartz slab interacts with the magnetic field generated by a spherical permanent magnet attached to a quartz oscillator resembling a tuning fork. When the slab supporting the proton moves back and forth at an appropriate frequency, the proton exerts a force that induces vibrations in the oscillator.

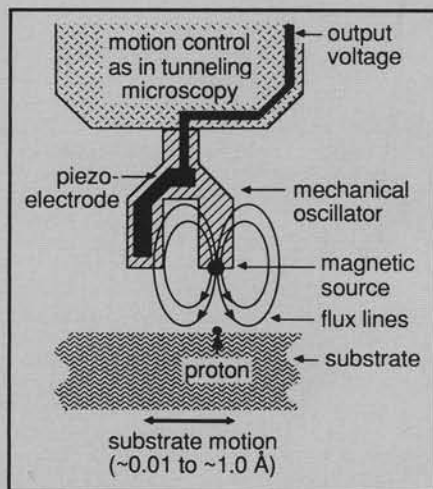
and developed — could form the basis for detecting single-proton magnetic resonance.

In such an experiment, a miniature mechanical oscillator would ride just a few angstroms above a surface dotted with protons. When the distance between a proton and the oscillator reached a certain critical value, the oscillator would begin to vibrate, generating a detectable signal. Successive scans could produce enough information to reconstruct the three-dimensional structure of a protein or some other complicated molecule.

"I hope my work will establish ... molecular imaging [via nuclear magnetic resonance] as a legitimate, publishable area of research," Sidles says. "Even if the approaches I have described prove impractical, perhaps other, more ingenious scientists will be encouraged to do better."

"It may be hard to make the thing work properly, but it has the potential of being very important," Bloom says. "It gives you a different way of thinking about fundamental measurements."

— I. Peterson



Sidles/APPLIED PHYSICS LETTERS

SCIENCE NEWS®

The Weekly Newsmagazine of Science

March 7, 1992

Vol 141, No. 10

This reprint from *Science News* reports on Dr. John A. Sidles' theoretical work for a proposed new technique that could lead to major advances in the field of magnetic resonance imaging.

Reprinted with permission from *Science News*, the weekly newsmagazine of science, ©1992 by Science Service, Inc.

Chief Resident Abstracts

Surgical Treatment of Upper Extremity Deformities in Arthrogryposis

Curtis W. Rodin, M.D.
Allan W. Bach, M.D.

Arthrogryposis multiplex congenita is a nonprogressive congenital syndrome or complex that occurs in approximately three in 10,000 live births. It is characterized by poorly developed and contracted muscles, deformed joints with abnormal periarticular tissues, an intact sensory system, and normal intellectual development. Patterns of deformity and weakness are more variable in the upper extremity and typically include internal rotational contractures of the shoulder, extension contractures of the elbow, wrist flexion, pronation, ulnar deviation contractures, digital interphalangeal joint contractures, and thumb-in-palm deformity.

Of the 91 patients treated for arthrogryposis at Children's Hospital and Medical Center from 1970 to 1989, 25 had 67 operative procedures to correct upper extremity deformities. Sixteen procedures in 12 patients involved the elbow. Nine posterior releases yielded greater than 100° of flexion in six patients, 70° in two, and 55° in one. Four Steindler flexorplasties resulted in grade 2/5 flexor strength in a 10-30° flexion arc. Two triceps transfers resulted in good strength (3/5) and range of motion (40-115°).

Twenty procedures in 14 patients involved the wrist. Soft tissue procedures were used in the majority; most obtained neutral wrist flexion and some achieved passive dorsiflexion. Carpectomies and fusions were done for persistent or untreated deformities in older children. No active extension was gained with flexor carpi ulnar to extensor carpi medialis brevis transfer.

Hand and digit deformities were treated with 14 procedures in nine patients. Four of five isolated PIP releases recurred, but those done in conjunction with wrist releases maintained position. Web Z-plasties improved hand use.

Eight patients had 16 procedures for thumb-in-palm deformity. The majority were first web Z-plasties with or without skin graft, singly or in combination with capsule and/or adductor releases. Thirteen of 16 were successful in achieving position resulting in improved grasp and opposition.

To our knowledge, this review evaluates the largest series of combined upper extremity procedures in arthrogryposis to date and demonstrates important principles in patient care. In general, patients with arthrogryposis show remarkable adaptability to their deformity, and a thorough evaluation of overall function and abilities must be made prior to any surgical intervention. It appears that increasing range of motion has a favorable influence on function. Adding even limited amounts of motor power can provide a sizeable functional improvement.

Histiocytosis X: A Spectrum of Disease

Michael J. Sailer, M.D.
Ernest U. Conrad III, M.D.

Histiocytosis X is the designation for a spectrum of disease characterized by a non-neoplastic proliferation of reticulo-histiocytic elements with varying numbers of eosinophils, neutrophils, leukocytes, plasma cells, and multinucleate giant cells. Solitary or multifocal eosinophilic granuloma is defined as isolated bony involvement and accounts for 37% to 62% of all bony lesions. Hand-Schüller-Christian disease is a benign, chronic, disseminated form, with absence of severe multisystem dysfunction. Skin

involvement is common and the classic triad of a skull lesion, exophthalmos, and diabetes insipidus occurs with a 10% frequency. Letterer-Siwe disease is a highly malignant, acute, disseminated form, with symptoms of fever, hepatosplenomegaly, lymphadenopathy, thrombocytopenia, otitis media, and skin lesions. Prior studies have reported a 40% mortality rate.

To help define appropriate treatment for these conditions, we reviewed the computerized database Children's Hospital and Medical Center and identified 42 patients diagnosed with histiocytosis X from 1980 to 1990. Twenty-three had solitary or multifocal eosinophilic granuloma, 10 had Hand-Schüller-Christian disease, and nine had Letterer-Siwe disease. The average age at diagnosis was 4.2 years, with a mean three years of follow-up (range three months to nine years). Male to female ratio was 15/27, as compared to a 2/1 ratio in previous studies. Forty-seven bone sites were involved, with wide anatomic distribution.

We found three thoracic and one lumbar lesion, all the classic vertebra plana. All four patients were braced and spinal lesions were treated with various combinations of biopsy and curettage, bone grafting, and chemotherapy. All four demonstrated loss of vertebral body height and all were free of spinal disease at follow-up.

Our series included 18 involved skulls and three mandibles. Only one active skull lesion was found at follow-up, in a patient with Letterer-Siwe disease, and it was treated with excision, x-ray therapy, and chemotherapy. The appendicular skeleton was involved in 15 patients; at follow-up 14 were disease-free and one had died of Letterer-Siwe disease. In the 11 patients with appendicular or spinal involvement only, none developed further lesions.

This study confirms many prior observations about the spectrum of histiocytosis X as well as reports that bony manifestations run a benign course. In our study, biopsy and curettage, with or without bone grafting, x-ray therapy, chemotherapy, and bracing, either alone or in combination, were equally effective in disease eradication.

Diagnostic Hip Arthrocentesis in Children: The Significance of a Dry Tap

John D. West, M.D.
Mark C. Dales, M.D.

Severe complications result from delayed diagnosis in septic hips in children. Differentiating between sterile toxic synovitis and a septic hip is often difficult as the history, physical exam, and laboratory studies frequently are similar. Arthrocentesis is the standard approach and usually is diagnostic; however, a dilemma occurs when no fluid is obtained despite arthrogram-documented penetration of the joint.

We reviewed 60 hip aspirations performed in 54 patients at Children's Hospital and Medical Center from 1980 to 1990. Patient age ranged from three weeks to 16 years (mean 4.5 years) with symptom duration from less than 24 hours to six months (mean 5.5 days). Twenty-five of the 60 hips were septic. Fifteen had toxic synovitis with rapid resolution of symptoms. Twelve had osteomyelitis, seven in the proximal femur and five in the ilium.

Fourteen of the suppurative hips had sterile joint fluid cultures but diagnostic gram stains. Ten of the 14 had been previously treated with antibiotics. Illnesses frequently associated with hip pyarthroses were respiratory or ear-nose-throat infection in seven patients, *H. influenza* meningitis in four, proximal femoral osteomyelitis in three, and recent surgical procedures in three.

In seven of the 60 hip aspirations (12%) no fluid was obtained despite arthrogram documentation of the intra-articular location of the needle. These patients had symptoms of less than 96 hours duration. Five of the seven hips were suppurative (71%). Four hips were grossly purulent with two loculated at arthrotomy. Two of the joint cultures grew *S. aureus* while three remained sterile but had previous positive blood cultures prior to the institution of antibiotic therapy. Duration between the dry tap and arthrotomy

ranged from less than 24 to 48 hours. Two hips with a dry tap were not septic, one had toxic synovitis and the other osteomyelitis of the ilium.

Two patients with an initial dry tap are known to have residual sequelae. A ten-year-old boy had severe avascular necrosis and collapse of the femoral head at two years, and a 15-month-old infant had a half-centimeter shortening of the femoral neck after 13 months. Two patients have no apparent sequelae; a nine-year-old after eight years of follow-up and a two-year-old after 23 months of follow-up. One patient was lost to follow-up.

Our data support the belief that the history, exam, radiograph, and lab values generally do not help to differentiate between toxic synovitis and pyarthrosis. Arthrocentesis usually is diagnostic, although failure to obtain fluid is not rare and a dry aspiration does not rule out pyarthrosis. We recommend immediate arthrotomy to avoid potential serious morbidity associated with further delay.

Posterior Dislocation of the Insall Burstein Posterior Stabilized II Total Knee Prosthesis

Donald B. Striplin, M.D.
Raymond P. Robinson, M.D.

We reviewed a series of 240 consecutive total knee replacements using the Insall Burstein Posterior Stabilized II prostheses implanted at Virginia Mason Medical Center in 1989-90. We report two cases of posterior femorotibial dislocations.

This posterior stabilized design uses a transverse femoral cam that comes into contact with a tibial post during knee flexion. This mechanism enhances femoral rollback and increases potential knee flexion. This prosthesis has increased height of the posterior femoral flange and allows the femoral cam to ride up higher on the tibial post to enhance flexion.

Case 1: A 61-year-old woman underwent bilateral total knee

replacements with cemented 59-mm prostheses. Examination prior to closure revealed excellent stability to varus and valgus stress in full extension but mild laxity in 90° of flexion. At three-month follow-up her knee range of motion was from full extension to 125° of flexion, with mild laxity again noted. A few days later when the patient tried to get up from a chair, she was unable to extend her knee. A lateral radiograph revealed a posterior dislocation of the femorotibial articulation.

Case 2: A 75-year-old man had bilateral simultaneous total knee replacements with cemented 69-mm prostheses. Seven months later, while attempting to rise from a kneeling position, he felt pain in his right knee and was unable to extend the joint. A lateral radiograph revealed a posterior dislocation. Closed reduction was performed, the knee was not immobilized, and the patient resumed full weight-bearing. Two months later he again dislocated his knee while kneeling on the floor.

Summary: Four factors were involved in these dislocations. First, the knees were flexed 120° to 130°, resulting in a rise of the femoral cam to the top of the tibial post. Second, the joints were distracted, lifting the cam above the tibial post. Such distraction could result from an externally applied load or from impingement of bone or soft tissue posterior to the knee joint during extreme knee flexion. Third, there was sufficient ligamentous laxity in flexion to allow joint distraction resulting from such a force. A posterior tibial post does not obviate the need for precise match of flexion and extension gaps. Fourth, a posteriorly directed force on the proximal tibia occurred, pushing the tibial post behind the femoral cam.

It was impressive how little laxity in flexion was necessary to make a knee with this prosthesis vulnerable to dislocation when all four factors were combined. Recent design changes address two of the factors leading to dislocation in our patients, but they do not eliminate the importance of achieving good balance of extension and flexion gaps even if a posterior stabilized prosthesis is being used.

A Prospective Study Evaluating Core Decompression for Early Osteonecrosis of the Hip in a High-Risk Group of Patients

Elisha T. Powell IV, M.D.
William L. Lanzer, M.D.
Martin G. Mankey, M.D.

Numerous investigators have advocated core decompression of the femoral head for the early treatment of osteonecrosis. However, others have argued that core decompression should be considered a relatively ineffective procedure with significant morbidity.

Among the various etiologies associated with osteonecrosis of the femoral head, prolonged steroid administration has been associated with fat emboli in subchondral arteries, fat-cell hypertrophy, and a gradual increase of intraosseous pressure in the femoral head. Increased pressure is thought to produce a venous obstruction resulting in progressive ischemia and eventual osteonecrosis. Patients with risk factors such as collagen vascular and steroid associated disease states have had poor results from core decompression.

From 1986-88, at the University of Washington Medical Center, 22 patients with history and physical findings consistent with osteonecrosis of the femoral head were evaluated preoperatively by conventional radiographs, radionuclide scanning, and magnetic resonance imaging (MRI). Our series included 12 women and 10 men ranging from 16 to 60 years (mean 35 years). Osteonecrosis was related to steroid use in 17 patients. Three had a significant history of alcohol use, and two had no identifiable risk factors.

All patients with Ficat stage 0, I, or II disease underwent core decompression. Histologic examination showed osteonecrosis of the femoral head in all 34 biopsies. Vascular outflow obstruction was evaluated in 24 of the 34 hips. All 24 had elevation of hydraulic resistance prior to core decompression. MRI

was more sensitive than radionuclide bone scanning, plain radiographs, or clinical exam in detecting stage 0 and stage I osteonecrosis of the femoral head. The bone scan was falsely negative in 31% of the hips. MRI was 100% sensitive and specific.

Complete follow-up was available for all patients for an average of four years. Four patients were deceased at the time of final follow-up. Of the 29 remaining hips, the mean preoperative modified Harris Hip score was 41 points and the mean postoperative score was 85 points.

Our results demonstrated clinical improvement, without radiographic progression, in 58.6% of our hips (66.6% of our patients). Eight out of 29 hips had hip arthroplasty performed compared to an expected 20 based on projections of data from historical studies.

The importance of early diagnosis and surgical treatment of avascular necrosis of the femoral head in patients on high doses of steroids is emphasized by the excellent results seen in core decompression of stage 0 and I avascular necrosis. In contrast, poor results with a failure rate of 87% occurred in treatment of stage II disease. Thus, even in a group of systemically ill patients on high doses of steroids, core decompression can be effective if performed in the early stages of avascular necrosis.

Deep Vein Thrombosis (DVT) Prophylaxis in Orthopaedic Trauma Patients

Jeffrey L. Stickney, M.D.

Pulmonary embolism (PE) is the cause of death in 10.9% of fatalities in patients who survive the first 24 hours after a traumatic injury, and is present in 27% of all patients who die four days or more after injury. Following orthopaedic trauma, the incidence of deep vein thrombosis (DVT) as detected by venography is 53% if no prophylaxis is provided. These lower extremity DVTs are assumed to be the source of fatal pulmonary embolism.

The treatment of DVT in a postoperative multiply injured patient has a very high rate of associated morbidity and mortality. A high complication rate also is associated with fully anti-coagulating a trauma patient.

Our goal in this prospective, randomized trial was to establish whether mechanical compression was an adequate prophylactic measure or if the addition of anti-coagulation was merited despite the obvious concerns of increased blood loss in trauma patients. Our study population included 112 patients with pelvic or femur fractures (57 men and 55 women, mean age 45.6 years) randomized into two groups from January through June 1990 at Tampa General Hospital, a level one trauma center.

Group 1 received compression (TED) thigh-high hose with thigh-high sequential compression devices (SCD); group 2 received TED hose, SCDs and anticoagulation with preoperative subcutaneous heparin and postoperative warfarin. The screening tool for the detection of DVT was color doppler ultrasound.

The overall incidence of DVT was 10 of 112, or 9%. In our patient population 33% of the women taking estrogen developed a DVT compared to only 6.8% of those who were not taking estrogen.

A number of prophylactic measures have been developed in an attempt to interfere with the process of thrombus formation while maintaining adequate hemostasis; however, prophylaxis is not widely accepted by practicing orthopaedists, and controversy still exists regarding the need for treatment of DVT.

This study documents that SCDs with anticoagulation therapy is an effective method of reducing the incidence of DVT. The complications associated with the use of anticoagulation was a 7% incidence of gastrointestinal blood loss with no increased incidence of wound hematoma formation. We recommend prophylaxis for all patients with pelvis or femur fractures, and the patients of particular concern are those that have sustained multiple trauma, have multiple repeat trips to the operating room, patients over the age of 50 and women on estrogen.

Department of Orthopaedics

Faculty

Frederick A. Matsen III, M.D.
Professor and Chair

Paul A. Anderson, M.D.
Associate Professor

Michele C. Battié, Ph.D.
Research Assistant Professor

Stephen K. Benirschke, M.D.
Associate Professor

Stanley J. Bigos, M.D.
Professor

Anne-Marie Bollen, Ph.D.
Research Associate

Jens R. Chapman, M.D.
Assistant Professor

John M. Clark Jr., M.D., Ph.D.
Associate Professor

Ernest U. Conrad III, M.D.
Associate Professor

Mark C. Dales, M.D.
Assistant Professor

David R. Eyre, Ph.D.
Professor

Theodore K. Greenlee Jr., M.D.
Associate Professor

Douglas P. Hanel, M.D.
Associate Professor

Sigvard T. Hansen Jr., M.D.
Professor

Douglas T. Harryman II, M.D.
Assistant Professor

M. Bradford Henley, M.D.
Associate Professor

Scott A. Hoffinger, M.D.
Assistant Professor

Roger V. Larson, M.D.
Associate Professor

Vincent S. Mosca, M.D.
Assistant Professor

Christopher Niyibizi, Ph.D.
Research Assistant Professor

Milton L. Routt Jr., M.D.
Assistant Professor

Linda J. Sandell, Ph.D.
Associate Professor

Bruce J. Sangeorzan, M.D.
Associate Professor

John A. Sidles, Ph.D.
Associate Professor

Douglas G. Smith, M.D.
Assistant Professor

Lynn T. Staheli, M.D.
Professor

D. Michael Strong, Ph.D.
Research Professor

Marc F. Swiontkowski, M.D.
Professor

Carol C. Teitz, M.D.
Associate Professor

Allan F. Tencer, Ph.D.
Associate Professor

Thomas E. Trumble, M.D.
Associate Professor

Jiann-Jiu Wu, Ph.D.
Research Associate Professor



Department of Orthopaedics
University of Washington, RK-10
Seattle, Washington 98195

Phone: (206) 543-3690
Fax: (206) 685-3139

Affiliated Institutions

**Children's Hospital and
Medical Center**
4800 Sand Point Way NE
Seattle, WA 98105
(206) 526-2108

Harborview Medical Center
325 Ninth Avenue
Seattle, WA 98104
(206) 223-3466

**University of Washington
Medical Center**
1959 NE Pacific Street
Seattle, WA 98195
(206) 548-4288

Veterans Affairs Medical Center
1660 South Columbian Way
Seattle, WA 98108
(206) 764-2215