

The Rotator Cuff

Purchase for your reference library today!



[Subscribe/Register](#) | [Help](#) | [About](#) | [Feedback](#)

FREDERICK MATSEN III MD [Sign Out](#)



[Citation Search](#)

[Home](#)

[Current Issue](#)

[All Issues](#)

[Browse by:](#)

[CME](#)

[Image Quizzes](#)

[My JBJS](#)

The Journal of Bone & Joint Surgery, Volume 93, Issue 17

Case Reports | September 07, 2011

Glenohumeral Chondrolysis Associated with Use of an Intra-Articular Pain Pump Delivering Local Anesthetics Following Manipulation Under Anesthesia: A Report of Four Cases

Juan A. Serrato, MD¹; Cassie M. Fleckenstein, MS¹; Samer S. Hasan, MD, PhD¹

¹ Cincinnati SportsMedicine Research and Education Foundation, 10663 Montgomery Road, 1st Floor, Cincinnati, OH 45242. E-mail address for C.M. Fleckenstein: cfleckenstein@csmedref.org

[View Disclosures and Other Information](#)

The Journal of Bone & Joint Surgery. 2011; 93:e99 1-8 doi:10.2106/JBJS.J.01604

[Article](#) [Figures](#) [References](#) [Comments](#)

text A A A

Print	PDF
Email	Share
Get Citation	Rights & Permissions
Sign Up for Alerts on this Article	Submit a Comment

Related Articles

Patient Activation and Functional Recovery in Persons Undergoing Spine Surgery

J Bone Joint Surg Am. 2011; 93:1665-1671
doi:10.2106/JBJS.J.00855

The Effect of Three Weekly Intra-Articular Injections of Hyaluronate on Pain, Function, and Balance in Patients with Unilateral Ankle Arthritis

J Bone Joint Surg Am. 2011; 93:1720-1726
doi:10.2106/JBJS.J.00315

[View More](#)

STABILITY stryker
Mobile Bearing Hip System
Addressing a real concern with data to back it.
Click to Learn More
ADM X3 Anatomic Dual Mobility
MDM X3 Modular Dual Mobility

Related Content

Topic Collections

[Shoulder Pain Management](#)

PubMed Articles

Editors' note.

Arthroscopy : the journal of arthroscopic & related surgery : official publication of the Arthroscopy Association of North America and the International Arthroscopy Association: Issue date- 2011 Jan
[More recent history of rapid adoption of new technology in sports medicine: intra-articular pain pumps.](#)

Arthroscopy : the journal of arthroscopic & related

Introduction

[Introduction](#) | [Case Reports](#) | [Discussion](#) | [References](#)

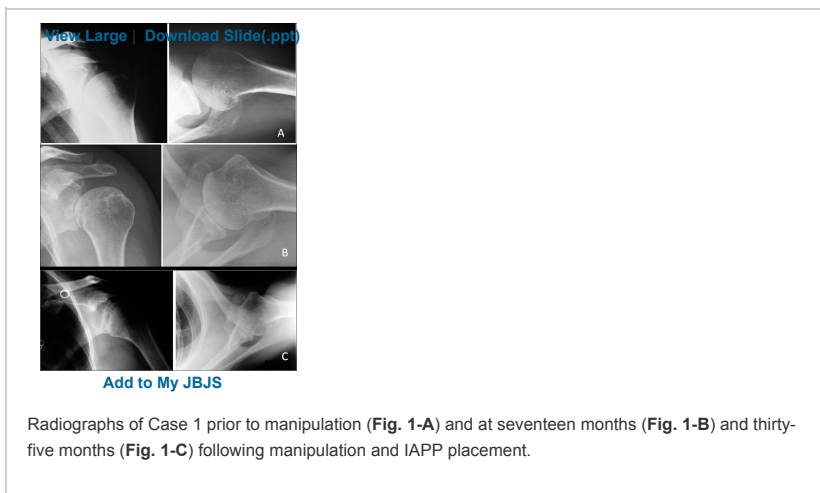
Glenohumeral chondrolysis is a devastating condition characterized by rapid dissolution of the articular cartilage surfaces of the glenoid and the humeral head. Patients typically present with a painful stiff joint, and radiographs demonstrate joint space narrowing and subchondral cystic changes. Because most cases of glenohumeral chondrolysis have occurred following arthroscopic shoulder surgery, the term "post-arthroscopic glenohumeral chondrolysis" (PAGCL) has been used to describe this condition. Several causative factors have been implicated, including suture anchors that are prominent or that become loose¹, excessive intra-articular use of thermal heat²⁻⁴, and intra-articular pain pump (IAPP) catheters delivering local anesthetics⁵⁻¹⁰. Most of the patients described developed glenohumeral chondrolysis following arthroscopic stabilization procedures in which one or more suture anchors were employed, with or without adjunctive use of thermal heat, and in which an IAPP was placed at the conclusion of the procedure to deliver local anesthetics for postoperative analgesia.

To the best of our knowledge, glenohumeral chondrolysis developing after the use of an IAPP and without arthroscopy has not been described previously. We report four cases of glenohumeral chondrolysis that occurred following the use of an IAPP delivering either 0.25% or 0.5% bupivacaine with epinephrine for forty-eight to sixty hours after isolated manipulation of the shoulder under anesthesia, without a surgical procedure. In all four patients, the initial treatment, including manipulation and placement of an IAPP (AmbIT; Sorenson Medical Products, West Jordan, Utah), was done elsewhere by the same orthopaedic surgeon between March 2006 and August 2007. One of the four patients was treated with a subsequent prosthetic shoulder arthroplasty by another surgeon prior to referral to the senior author (S.S.H.). Each of the four patients in this series was informed that data concerning his or her case were submitted for publication, and verbal consent was obtained. A formal written consent specific to this case report was not obtained, owing to the retrospective nature of this work.

Case Reports

[Introduction](#) | [Case Reports](#) | [Discussion](#) | [References](#)

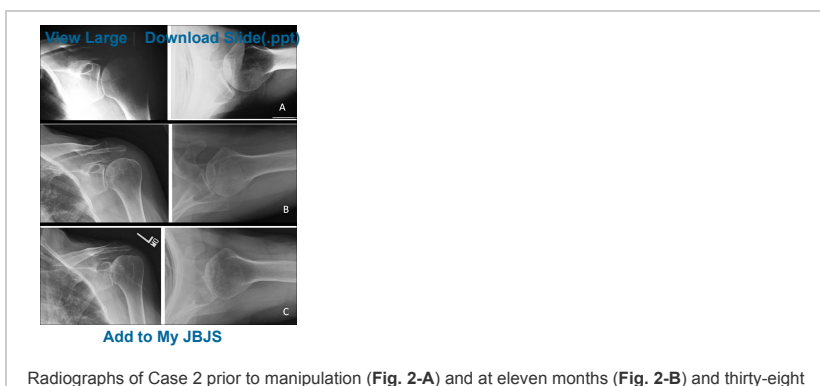
CASE 1. A fifty-five-year-old woman presented for evaluation of pain and stiffness in the left shoulder, and was diagnosed with idiopathic adhesive capsulitis. Passive forward elevation and abduction were 100° and 90°, respectively, and internal and external rotation was markedly restricted. A magnetic resonance imaging (MRI) scan suggested a partial-thickness rotator cuff tear but no glenohumeral arthritis. Initial radiographs did not demonstrate glenohumeral arthritis (Fig. 1-A). The patient underwent manipulation of the shoulder under anesthesia followed by placement of a pain pump catheter delivering 0.5% bupivacaine with epinephrine at a flow rate of 2 mL/hr. The catheter was threaded over a sheath placed percutaneously from an anterior approach. Within one month following the manipulation, active and passive shoulder elevation and abduction, measured by both the treating surgeon and the physical therapist, had both improved to >150°. Three months following the manipulation, the patient had recovered nearly full motion.



Radiographs of Case 1 prior to manipulation (Fig. 1-A) and at seventeen months (Fig. 1-B) and thirty-five months (Fig. 1-C) following manipulation and IAPP placement.

Seventeen months following manipulation, the patient returned to her orthopaedic surgeon because of increasing pain and the onset of shoulder crepitation. Radiographs demonstrated substantial glenohumeral joint space narrowing and subchondral cysts (Fig. 1-B). A repeat MRI revealed marked glenohumeral cartilage loss. The diagnosis of chondrolysis was made, and the patient was subsequently referred to the senior author. At her initial visit, examination of the left shoulder revealed active forward elevation to 140°, abduction to 140°, and external rotation to 60°. Internal rotation to the back was to the level of the ninth thoracic vertebral spinous process. At her most recent visit, thirty-five months following manipulation, active motion had diminished, with forward elevation to 90°, abduction to 80°, external rotation to 30°, and internal rotation to the lumbosacral junction. Follow-up radiographs demonstrated obliteration of the glenohumeral joint space and extensive subchondral cystic changes (Fig. 1-C). At the time of writing, the patient was considering total shoulder arthroplasty.

CASE 2. A sixty-year-old woman presented with left shoulder pain and stiffness of seven months' duration, beginning after she lifted a box and felt a "pop" in the shoulder. Examination of the left shoulder revealed "minimal internal and external rotation," forward elevation to 100°, and abduction to 50°. Radiographs obtained at her initial visit did not show any sign of glenohumeral arthritis (Fig. 2-A). She was diagnosed with idiopathic adhesive capsulitis and was treated with shoulder manipulation under anesthesia, followed by placement of an IAPP to deliver 0.5% bupivacaine with epinephrine at 2 mL/hr. Following shoulder manipulation, the patient had an uneventful initial recovery. According to both the physical therapist and the orthopaedic surgeon, forward elevation and abduction exceeded 170° within one month after the manipulation.



Radiographs of Case 2 prior to manipulation (Fig. 2-A) and at eleven months (Fig. 2-B) and thirty-eight

surgery : official publication of the Arthroscopy Association of North America and the International Arthroscopy Association: Issue date- 2011 Apr

[View More](#)

Results provided by:



Guidelines

[Guideline on use of local anesthesia for pediatric dental patients.](#) -American Academy of Pediatric Dentistry

[Intraspinal techniques for pain management in cancer patients: guideline recommendations.](#) - Program in Evidence-based Care

[View More](#)

Results provided by:



jbjsjobs

09/20/2011

[Joint Replacement Orthopaedic Surgeon](#)

NY - Montefiore Medical Center

09/20/2011

[Pediatric Orthopaedic Surgeons](#)

NY - Montefiore Medical Center

09/07/2011

[ORTHOPAEDIST FOOT AND ANKLE](#)

NJ - 08807

08/01/2011

[General Orthopaedic Surgeon](#)

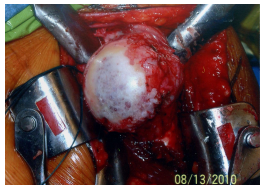NY - Able Orthopedic and Sports Medicine P.C.

[View More From](#)

months (Fig. 2-C) following manipulation and IAPP placement.

The patient returned to the orthopaedic surgeon eleven months following the manipulation with complaints of increasing left shoulder pain and stiffness. Radiographs documented some glenohumeral joint space narrowing (Fig. 2-B), but the diagnosis of chondrolysis was not established. Instead, the patient was treated for residual or recurrent adhesive capsulitis. She received an intra-articular corticosteroid injection (2 mL of betamethasone and 8 mL of 0.5% bupivacaine) followed by a course of supervised physical therapy. A second intra-articular corticosteroid/bupivacaine injection into the shoulder was administered fourteen months following the manipulation. The patient reported minimal improvement following these interventions. Thirty-eight months following the manipulation, she returned to her orthopaedic surgeon with continued symptoms. Radiographs demonstrated marked glenohumeral degenerative changes, including obliteration of the joint space, subchondral glenoid and humeral head cystic changes, and peripheral osteophytes (Fig. 2-C).

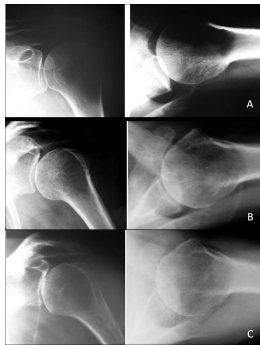
The patient was subsequently referred to the senior author, who found active left shoulder motion to be severely restricted, with forward elevation to 60°, abduction to 40°, external rotation to 20°, and internal rotation to the ipsilateral thigh. An MRI documented corresponding glenohumeral joint changes and an intact rotator cuff. Because of persistent severe pain and marked motion deficits, the patient underwent left total shoulder arthroplasty. The findings at surgery included advanced arthrosis (Fig. 3) with diffuse cartilage loss and soft, cystic subchondral bone.



[View Large](#) | [Download Slide\(.ppt\)](#)
[Add to My JBJS](#)

Fig. 3
Intraoperative photograph of Case 2, demonstrating advanced chondrolysis at the time of total shoulder arthroplasty.

CASE 3. A fifty-two-year-old woman presented with left shoulder pain and stiffness of two months' duration. The patient demonstrated marked deficits in active and passive motion, with forward elevation limited to 90° and abduction limited to 60°. An MRI scan suggested a partial-thickness rotator cuff tear; neither MRI nor radiographs (Fig. 4-A) demonstrated evidence of glenohumeral arthritis. The patient was diagnosed with idiopathic adhesive capsulitis, and a shoulder manipulation under anesthesia was performed. At the conclusion of the procedure, the patient received an IAPP delivering 0.25% bupivacaine with epinephrine at 2 mL/hr. The patient started an outpatient physical therapy program. Her symptoms decreased and motion improved for the first two months, so that forward elevation and abduction were approximately 140°.



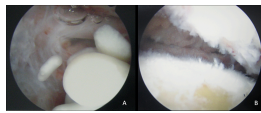
[View Large](#) | [Download Slide\(.ppt\)](#)
[Add to My JBJS](#)

Radiographs of Case 3 prior to manipulation (Fig. 4-A) and at eleven months (Fig. 4-B) and twenty-four months (Fig. 4-C) following manipulation and IAPP placement.

The patient returned with complaints of increasing pain three months following the manipulation. She received a corticosteroid injection (2 mL of triamcinolone and 8 mL of 0.5% bupivacaine), and her motion improved but the pain persisted.

The patient presented to the senior author for a second opinion four months following the manipulation. Nonsteroidal anti-inflammatory medications and exercises helped to improve shoulder motion so that, eleven months following manipulation, active forward elevation was 150°. However, the shoulder examination continued to demonstrate a painful loss of internal rotation and positive impingement signs in addition to tenderness over the rotator cuff. An MRI suggested a high-grade, partial-thickness rotator cuff tear that had progressed, so shoulder arthroscopy with arthroscopic rotator cuff debridement or repair was recommended.

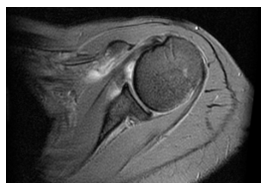
Left shoulder arthroscopy was performed twelve months following manipulation and revealed diffuse Outerbridge¹¹ grade-II and grade-III changes to the articular cartilage of the glenoid and the humeral head and multiple chondral loose bodies, but no rotator cuff tear (Figs. 5-A and 5-B). The diagnosis of chondrolysis was made. During the ensuing months, shoulder motion gradually diminished and the pain worsened. Radiographs at eleven months (Fig. 4-B) and twenty-four months (Fig. 4-C) following the manipulation demonstrated progressive joint space narrowing. The patient ultimately underwent elective total shoulder arthroplasty, which was performed twenty-eight months following manipulation and placement of the IAPP.



[View Large](#) | [Download Slide\(.ppt\)](#)
[Add to My JBJS](#)

Intraoperative arthroscopic images of Case 3, demonstrating chondral loose bodies (Fig. 5-A) and diffuse glenohumeral chondrolysis (Fig. 5-B) at twelve months after manipulation and IAPP placement.

CASE 4. A fifty-three-year-old woman presented for treatment of a left shoulder injury sustained in a fall down the stairs three months earlier. She had initially sought the care of her primary care physician as well as a local chiropractor. Radiographs did not demonstrate a fracture or glenohumeral arthritis. MRI showed capsular thickening and rotator cuff tendinosis without fracture or glenohumeral arthritis (Fig. 6). The patient was referred to her orthopaedic surgeon, who noted that motion of the left shoulder was "very poor" and diagnosed idiopathic adhesive capsulitis. Nonoperative treatment was recommended, but nonsteroidal anti-inflammatory medications, physical therapy, and a corticosteroid injection (2 mL of triamcinolone and 8 mL of 0.5% bupivacaine) failed to relieve the symptoms. Four months after the injury, she underwent a left shoulder manipulation under anesthesia followed by placement of an IAPP delivering 0.25% of bupivacaine with epinephrine at 2 mL/hr. The patient initiated physical therapy the day after the manipulation, and within one week the physical therapist documented that forward elevation and abduction had improved to 160°. The patient did well in therapy and on her own for the first three months.

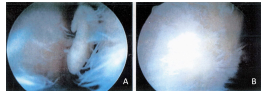


[View Large](#) | [Download Slide\(.ppt\)](#)
[Add to My JBJS](#)

Fig. 6
 Representative axial cut from the MRI of Case 4, obtained prior to manipulation, demonstrating preserved glenohumeral articular surfaces.

Seven months following the manipulation, the patient sought a second opinion because of increasing shoulder pain and decreasing mobility. The second surgeon diagnosed shoulder impingement and a partial-thickness rotator cuff tear and performed shoulder arthroscopy eight months after the manipulation. Shoulder arthroscopy did not demonstrate a rotator cuff tear but did reveal diffuse Outerbridge grade-III and grade-IV chondral damage to the humeral head and glenoid as well as multiple chondral loose bodies (Figs. 7-A and 7-B), which were removed. There was no improvement following this surgery and, eleven months following the manipulation,

prosthetic hemiarthroplasty was performed. Twenty-five months following the manipulation, the hemiarthroplasty was revised to a total shoulder replacement because of persistent pain attributed to glenoid erosion. The patient was subsequently referred to the senior author for an evaluation that revealed some loss of motion but no evidence of instability, implant loosening, or infection.



[View Large](#) | [Download Slide\(.ppt\)](#)
[Add to My JBJS](#)

Intraoperative arthroscopic images of Case 4, demonstrating chondral loose bodies (**Fig. 7-A**) and diffuse chondrolysis (**Figs. 7-A and 7-B**) at eight months after manipulation and IAPP placement.

Discussion

[Introduction](#) | [Case Reports](#) | [Discussion](#) | [References](#)

Since the report in 2007 by Hansen et al.⁵, in which twelve of nineteen patients who had received an IAPP for bupivacaine infusion subsequently developed glenohumeral chondrolysis, there have been several published case series of patients with this complication, including the report of seventeen cases by Bailie and Ellenbecker⁷ and that of eighteen cases by Anderson et al.⁶. Two additional case series included patients with glenohumeral chondrolysis related to an IAPP^{12,13}, and several case reports^{2,14,15} describing this problem have also been published. Scheffel et al.¹⁶ performed a systematic review of 100 cases of glenohumeral chondrolysis, fifty-nine of which were related to an IAPP. From November 2007 to July 2010, the senior author of the present study examined and/or treated thirty-five patients referred to his practice with glenohumeral chondrolysis, thirty-three of whom developed the condition after placement of an IAPP delivering bupivacaine. The mean age of these patients at the time of IAPP placement was 29.3 years (range, fifteen to sixty years).

The four patients in our case series were fifty-two, fifty-three, fifty-five, and sixty years old at the time of shoulder manipulation and IAPP placement. They are the oldest four patients with glenohumeral chondrolysis who have been examined to date by the senior author. Only two of the remaining twenty-nine patients with chondrolysis related to an IAPP were over thirty-five years old at the time of IAPP placement. Although these patients were considerably older than most patients with glenohumeral chondrolysis, it is unlikely that the rapid glenohumeral joint deterioration represented an exacerbation of unrecognized and/or preexisting degenerative change or was due to an altogether different etiology. At the time of their first evaluation by the initial orthopaedic surgeon, all four patients had radiographs and/or MRIs that did not reveal an underlying arthropathy. In addition, all four patients initially responded well to the manipulation and the subsequent physical therapy. This response strongly suggests that adhesive capsulitis was the correct diagnosis for all four patients. Patients with glenohumeral arthritis, and not frozen shoulder, would not likely have responded as well to an isolated shoulder manipulation under anesthesia.

All four patients developed striking radiographic changes within eleven to twenty-four months following the use of an IAPP. However, three of the four patients (Cases 2, 3, and 4) were not diagnosed with chondrolysis when they presented to three different orthopaedic surgeons because of worsening shoulder pain and stiffness several months following manipulation. One patient (Case 4) presented with symptoms following use of an IAPP in 2006, before the relationship between glenohumeral chondrolysis and the infusion of local anesthetics was widely recognized. In Case 2, radiographs demonstrated early degenerative changes eleven months following manipulation, but this was not appreciated initially. In Case 3, the senior author failed to establish that a pain pump had been used previously until after shoulder arthroscopy confirmed substantial chondral damage. Moreover, radiographs and MRI studies obtained within the first year following manipulation did not demonstrate advanced joint destruction.

This small case series has limitations. The initial treating orthopaedic surgeon did not use imaging to confirm intra-articular placement of the pain pump catheter tip. In theory, the catheter could have been placed external to the glenohumeral joint in all four cases. Consequently, it is impossible to be certain that the chondrolysis was caused by the intra-articular infusion of local anesthetics. Nevertheless, the intent was to place the catheter within the glenohumeral joint at the site of capsular release. Another limitation is that the manipulation was not combined with arthroscopy, which might have identified early osteoarthritis. Finally, the initial treating surgeon did not consistently record range-of-motion measurements before and immediately after manipulation.

Consequently, we used the physical therapy progress notes when necessary to verify the gains in shoulder motion following manipulation.

Most authors of published reports on chondrolysis related to an IAPP have acknowledged the presence of other potential causative factors. Most patients with glenohumeral chondrolysis in published series have been young people who underwent arthroscopic glenohumeral instability repairs, usually with suture anchors and sometimes with adjunctive use of thermal heat. Hansen et al.⁵ found that glenohumeral chondrolysis occurred in twelve of nineteen shoulders in which an IAPP had been placed at the time of arthroscopic shoulder surgery; none of the other 158 shoulders that had undergone arthroscopic shoulder surgery without an IAPP showed signs of glenohumeral chondrolysis. Follow-up statistical analysis using the Fisher exact test revealed that "the likelihood that chance alone could explain the observed distribution of chondrolysis is less than 1 in 10,000."¹⁷ Others have also concluded that the principal cause of chondrolysis in the series by Hansen et al.⁵ appears to be the IAPP⁸.

Recently, to explore factors that might be associated with chondrolysis, Wiater et al.¹⁰ reported on 375 glenohumeral arthroscopic procedures performed by an individual community orthopaedic surgeon. Forty-nine of the 109 shoulders in which an IAPP had been used postoperatively developed chondrolysis. Over one-half of these cases were diagnosed within eighteen months following IAPP use. All patients in whom chondrolysis developed in the shoulder had received an IAPP infusing either lidocaine or 0.5% bupivacaine, with or without epinephrine¹⁰. None of the six cases receiving an IAPP infusing 0.25% bupivacaine developed chondrolysis. Statistical analyses revealed that younger patient age, suture capsular plication, and Bankart repair were among the factors associated with an increased risk of chondrolysis.

Two of the four patients in our series had infusion of 0.25% bupivacaine with epinephrine, and two had infusion of 0.5% bupivacaine with epinephrine. All four patients used an identical pain pump at a flow rate of 2 mL/hr for forty-eight to sixty hours until the catheter was removed during the first postoperative physical therapy visit. These findings confirm that, in some patients, chondrolysis can occur even with infusion of a low concentration of bupivacaine (0.25%) at a low flow rate (2 mL/hr). This is in contrast to the findings of Wiater et al.¹⁰ as well as those of a retrospective comparative study by Rapley et al.⁹, who did not observe chondrolysis in patients who had used an IAPP at a flow rate of 2 mL/hr.

Chondrolysis progresses rapidly, even in patients fifty to sixty years old. Three of our four patients (Cases 2, 3, and 4) underwent prosthetic shoulder arthroplasty at a mean of twenty-six months after the use of an IAPP. In many cases of glenohumeral chondrolysis, multiple factors could be acting synergistically to cause the condition, and could help explain why some patients do not develop chondrolysis following the use of an IAPP. However, the essential factor for the development of most of the current cases of chondrolysis, except those related to loose or proud suture anchors, appears to be the use of an IAPP.

The four cases reported here confirm that the other cited risk factors need not be present. To the best of our knowledge, this series represents the only cases of glenohumeral chondrolysis arising in the absence of any other known causative factors besides the use of an IAPP catheter delivering local anesthetics. These cases reinforce the mounting evidence that IAPP catheters can cause articular cartilage injury in the glenohumeral joint.

References

[Introduction](#) | [Case Reports](#) | [Discussion](#) | [References](#) 

- 1 Athwal GS; Shridharani SM; O'Driscoll SW. Osteolysis and arthropathy of the shoulder after use of bioabsorbable knotless suture anchors. A report of four cases. *J Bone Joint Surg Am.* 2006;88:1840-5. [\[CrossRef\]](#)[\[PubMed\]](#)
- 2 Petty DH; Jazrawi LM; Estrada LS; Andrews JR. Glenohumeral chondrolysis after shoulder arthroscopy: case reports and review of the literature. *Am J Sports Med.* 2004;32:509-15. [\[CrossRef\]](#)[\[PubMed\]](#)
- 3 Good CR; Shindle MK; Kelly BT; Wanich T; Warren RF. Glenohumeral chondrolysis after shoulder arthroscopy with thermal capsulorrhaphy. *Arthroscopy.* 2007;23:797. e1-5. [\[PubMed\]](#)
- 4 Levine WN; Clark AM Jr; D'Alessandro DF; Yamaguchi K. Chondrolysis following arthroscopic thermal capsulorrhaphy to treat shoulder instability. A report of two cases. *J Bone Joint Surg Am.* 2005;87:616-21. [\[CrossRef\]](#)[\[PubMed\]](#)
- 5 Hansen BP; Beck CL; Beck EP; Townsley RW. Postarthroscopic glenohumeral chondrolysis. *Am J Sports Med.* 2007;35:1628-34. [\[CrossRef\]](#)[\[PubMed\]](#)
- 6 Anderson SL; Buchko JZ; Taillon MR; Ernst MA. Chondrolysis of the glenohumeral joint after infusion of bupivacaine through an intra-articular pain pump catheter: a report of 18 cases. *Arthroscopy.*

2010;26:451-61.[\[CrossRef\]](#)[\[PubMed\]](#)

7 Bailie DS; Ellenbecker TS. Severe chondrolysis after shoulder arthroscopy: a case series. *J Shoulder Elbow Surg.* 2009;18:742-7.[\[CrossRef\]](#)[\[PubMed\]](#)

8 Busfield BT; Romero DM. Pain pump use after shoulder arthroscopy as a cause of glenohumeral chondrolysis. *Arthroscopy.* 2009;25:647-52.[\[CrossRef\]](#)[\[PubMed\]](#)

9 Rapley JH; Beavis RC; Barber FA. Glenohumeral chondrolysis after shoulder arthroscopy associated with continuous bupivacaine infusion. *Arthroscopy.* 2009;25:1367-73.[\[CrossRef\]](#)[\[PubMed\]](#)

10 Wiater BP; Neradilek MB; Polissar NL; Matsen FA 3rd. Risk factors for chondrolysis of the glenohumeral joint: a study of three hundred and seventy-five shoulder arthroscopic procedures in the practice of an individual community surgeon. *J Bone Joint Surg Am.* 2011;93:615-25.[\[CrossRef\]](#)[\[PubMed\]](#)

11 Outerbridge RE. The etiology of chondromalacia patellae. *J Bone Joint Surg Br.* 1961;43:752-7.[\[PubMed\]](#)

12 Levy JC; Virani NA; Frankle MA; Cuff D; Pupello DR; Hamelin JA. Young patients with shoulder chondrolysis following arthroscopic shoulder surgery treated with total shoulder arthroplasty. *J Shoulder Elbow Surg.* 2008;17:380-8.[\[CrossRef\]](#)[\[PubMed\]](#)

13 McNickle AG; L'Heureux DR; Provencher MT; Romeo AA; Cole BJ. Postsurgical glenohumeral arthritis in young adults. *Am J Sports Med.* 2009;37:1784-91.[\[CrossRef\]](#)[\[PubMed\]](#)

14 Greis PE; Legrand A; Burks RT. Bilateral shoulder chondrolysis following arthroscopy. A report of two cases. *J Bone Joint Surg Am.* 2008;90:1338-44.[\[CrossRef\]](#)[\[PubMed\]](#)

15 Saltzman M; Mercer D; Bertelsen A; Warme W; Matsen F. Postsurgical chondrolysis of the shoulder. *Orthopedics.* 2009;32:215.[\[CrossRef\]](#)[\[PubMed\]](#)



16 Scheffel PT; Clinton J; Lynch JR; Warme WJ; Bertelsen AL; Matsen FA 3rd. Glenohumeral chondrolysis: a systematic review of 100 cases from the English language literature. *J Shoulder Elbow Surg.* 2010;19:944-9.[\[CrossRef\]](#) [\[PubMed\]](#)

17 Hasan SS; Levy M; Noyes FR; Moller SA; Zambelli-Weiner A; Beck CL Jr; Townsley R; Beck EP; Hansen B. Letter to the editor. *Am J Sports Med.* 2010;38: NP1—2; author reply NP2.

Content

[Current Issue](#)
[All Issues](#)
[Browse](#)
[CME](#)
[Video Library](#)
[Podcasts](#)
[Image Quizzes](#)

Services

[Manage Manuscript](#)
[Subscribe/Register](#)
[Help](#)
[Access for Developing Countries](#)
[Journal Club](#)
[Orthopaedic Bookshelf](#)
[RSS Feeds](#)
[Email Alerts](#)
 [Find us on Facebook](#)
 [Follow us on Twitter](#)

General Information

[About](#)
[Advertisers](#)
[Contact Us](#)
[Privacy Notice](#)
[Terms of Use](#)
[Rights & Permissions](#)
[Institutions/Librarians](#)
[Instructions for Authors](#)
[Subscriptions](#)
[Subscription Agents](#)
[Media](#)
[Site Map](#)

The Journal of Bone and Joint Surgery
 20 Pickering Street
 Needham, MA 02492 USA
 Online ISSN: 1535-1386
 Copyright © 2011. All Rights Reserved.
 The Journal of Bone and Joint Surgery, Inc.

