

damage despite adequate decompression of the forearm and hand compartments. In the several days between fasciotomy and wound closure, adequate wound care should be ensured. This is performed with frequent dressing changes and either whirlpool or pulse lavage type irrigation. At this time it is also wise to instruct the patient in hand motion exercises. The chief reason for these exercises is to ensure that the patient's range of motion remains relatively stable and that tendon gliding continues, especially with the flexor tendons at the wrist level.

COMPLICATIONS

As with any surgery, bleeding and hematoma are possible, especially in a forearm fasciotomy in which no tourniquet is used intraoperatively. Any open wound is prone to infection, and good wound care should be instituted to prevent this problem. Finally, the most dreaded complication of forearm fasciotomy is continued muscle necrosis and eventual fibrosis despite forearm fasciotomies. In general, this will likely not occur with adequate decompression. As stated previously, the most likely reason for continued muscle necrosis following this operation is inadequate decompression of the forearm and hand compartments.

RESULTS

In general, adequate decompression of the compartments of the forearm and hand will allow resolution of the compartment syndrome and will lead to an outcome in which the patient has no or minimal residual dysfunction, although this general scenario is not without exceptions. Most frequently, the cause of muscle necrosis and subsequent fibrosis following forearm fasciotomy is due to incomplete fasciotomy. Therefore, care must be taken intraoperatively to fully extend the fasciotomy proximally and distally, thereby decompressing the full length of all the affected muscle bellies. Following fasciotomy, patients will require diligent wound care to ensure that the wounds remain clean so that they will be ready for either delayed primary closure or skin grafting.

RECOMMENDED READING

- Del Pinal F, et al. Acute hand compartment syndromes after closed crush: a reappraisal. *Plast Reconstr Surg.* 2002;110(5):1232-1239.
- Elliott KG, Johnstone AJ. Diagnosing acute compartment syndrome. *J Bone Joint Surg Br.* 2003;85(5):625-632.
- Gelberman RH, et al. Compartment syndromes of the forearm: diagnosis and treatment. *Clin Orthop Relat Res.* 1981;161: 252-261.
- Gulgonen A. Acute compartment syndrome. In: Green, et al, eds. *Green's operative hand surgery.* Philadelphia: Elsevier;2005:1986-1996.
- McQueen MM, Gaston P, Court-Brown CM. Acute compartment syndrome. Who is at risk? *J Bone Joint Surg Br.* 2000;82(2):200-203.
- Naidu SH, Heppenstall RB. Compartment syndrome of the forearm and hand. *Hand Clin.* 1994;10(1):13-27.
- Tsuge K. Treatment of established Volkmann's contracture. *J Bone Joint Surg Am.* 1975;57(7):925-929.

13 Soft Tissue Interposition Flaps in the Management of Heterotopic Ossification and Proximal Radioulnar Synostosis

Douglas P. Hanel and Seth D. Dodds

INDICATIONS/CONTRAINDICATIONS

Heterotopic ossification of the elbow with loss of motion can be severely debilitating. The functional arc of elbow motion spans from 30 to 130 degrees of flexion and from 50 degrees of pronation to 50 degrees of supination. Limitations to this functional arc significantly impair the ability to perform activities of daily living. Cases of elbow ankylosis or radioulnar synostosis further minimize use of the affected extremity. Once heterotopic ossification has developed and constricts motion, it is nearly impossible to regain the lost motion with conservative measures, such as physical therapy, dynamic splinting, radiation therapy, or medication.

Surgical resection of heterotopic bone about the elbow should be considered in patients who present with an unacceptable loss of flexion/extension or pronation/supination. Excision is also warranted in cases of neurovascular impingement caused by ectopic bone. In cases of proximal radioulnar synostosis or even radial head excision, interposition materials can be used to cover exposed bone surfaces.

While options for soft tissue interposition include silicone sheeting, fat graft, and free adipofascial flaps, pedicled myofascial flaps and allograft fascia lata have become increasingly popular. The pedicled anconeus myofascial flap is an ideal choice in those cases approached posterolaterally, whereas the pedicled brachioradialis muscle flap passed through the interosseous membrane is best suited for those cases approached from an anterior exposure. The soft tissue interposition acts as a barrier to the formation of recurrent heterotopic calcification and allegedly decreases pain with pronation and supination. It is suggested, though unproven, that pedicled graft tissue has greater po-

tential for sustained viability when judged against nonvascularized tissue transfers, such as subcutaneous fat or an adipose fascial graft. When properly fixed to the underlying bone, these pedicled flaps can sustain aggressive postoperative range-of-motion exercises that might dislodge less robust tissue such as fat alone or adipose-fascial grafts. We prefer the anconeus muscle pedicle flap when available and tensor fascia lata allograft when the anconeus is not available or not large enough.

Historically, contraindications to excision of heterotopic bone with or without soft tissue interposition flaps included immature ossification and an unreliable soft tissue envelope. In the past decade there have been a number of reports documenting the efficacy of early excision of heterotopic bone. It is our experience that patients suffer less soft tissue contracture and have superior function with early release of a stiff elbow. The recurrence of heterotopic bone in the posttraumatic setting has not been shown to be predicated on the timing of the excision. Outcomes of surgical excision, however, will be threatened by a poor soft tissue envelope. Once the posttraumatic or post-burn wounds have healed, soft tissue swelling has abated, and nerve recovery has plateaued, patients may safely undergo elbow contracture release.

Contraindications to pedicled soft tissue interposition flaps depend on the specific muscle selected. For an anconeus muscle interposition, previous traumatic or surgical disruption of its primary vascular supply (the medial collateral artery from the profunda brachii) jeopardizes the viability of the raised muscle flap. The brachioradialis "wrap around" flap should not be raised if there is a non-functioning biceps brachii or brachialis, as the brachioradialis provides assistance with elbow flexion as well as supination when the forearm is fully pronated. Assuming that the arm and forearm musculature is intact, using the anconeus or brachioradialis as a pedicled interposition flap causes little functional loss.

PREOPERATIVE PLANNING

Before operative release and soft tissue interposition, patients must be carefully evaluated. The history should focus on the primary complaint. Patients must verbalize appropriate frustration with their disability from elbow stiffness to warrant release. It is also imperative that patients demonstrate the willingness and capacity for intensive rehabilitation. If the presenting complaint is predominantly pain, then contracture release will be futile. A focused surgical history needs to be elicited. Previous injuries and surgeries of the involved extremity offer critical information about the status of osseous and cartilaginous structures as well as the elbow's soft tissue envelope. Operative reports from previous surgeries help understand the integrity and location of possibly transposed neurovascular structures.

Elbow range of motion, stability, pain, and functional ability are assessed. The Mayo Elbow Performance Score serves as a summary of these findings. In addition, the examination includes assessment of forearm rotation and wrist and hand function. If there is physical evidence of nerve dysfunction, electrodiagnostic studies should be obtained to confirm the location of compression and to act as a baseline of nerve function. All of our patients have had previous surgeries, and as such, a careful assessment of incisions about the elbow with regard to the palpable and radiographic location of heterotopic ossification is essential. The integrity of the skin and subcutaneous tissues should be evaluated. Lingering soft tissue swelling, edema, or erythema may all point to additional diagnoses to be contended with before deciding on heterotopic bone excision.

Standard radiographs of the elbow are obtained with oblique views to improve visualization of ectopic ossification. We routinely perform computed tomography (CT) on cases of elbow heterotopic ossification where the congruity of the articular surface is in question and in all cases with proximal radioulnar synostosis. An axial CT scan with coronal and sagittal reformatted images is currently the most helpful method to visualize the location and extent of a bony bridge between the radius and ulna (Figs. 13-1 and 13-2). Vascular study of the elbow and proximal forearm should be considered if there are concerns about the integrity of the regional blood supply, especially in cases of pedicled soft tissue interposition. Unless there are specific historical or physical findings suggesting potential or indolent infection, we limit blood studies to those required for a prolonged general anesthetic.

The timing for intervention is somewhat nebulous and is certainly directed by physician bias. We do not believe there is sufficient scientific evidence to suggest that nuclear medicine scans or blood alkaline phosphatase levels are beneficial in the assessment or timing of surgical intervention. In reviewing the literature and comparing our experience, it would appear that waiting for fracture heal-

tential for sustained viability when judged against nonvascularized tissue transfers, such as subcutaneous fat or an adipose fascial graft. When properly fixed to the underlying bone, these pedicled flaps can sustain aggressive postoperative range-of-motion exercises that might dislodge less robust tissue such as fat alone or adipose-fascial grafts. We prefer the anconeus muscle pedicle flap when available and tensor fascia lata allograft when the anconeus is not available or not large enough.

Historically, contraindications to excision of heterotopic bone with or without soft tissue interposition flaps included immature ossification and an unreliable soft tissue envelope. In the past decade there have been a number of reports documenting the efficacy of early excision of heterotopic bone. It is our experience that patients suffer less soft tissue contracture and have superior function with early release of a stiff elbow. The recurrence of heterotopic bone in the posttraumatic setting has not been shown to be predicated on the timing of the excision. Outcomes of surgical excision, however, will be threatened by a poor soft tissue envelope. Once the posttraumatic or post-burn wounds have healed, soft tissue swelling has abated, and nerve recovery has plateaued, patients may safely undergo elbow contracture release.

Contraindications to pedicled soft tissue interposition flaps depend on the specific muscle selected. For an anconeus muscle interposition, previous traumatic or surgical disruption of its primary vascular supply (the medial collateral artery from the profunda brachii) jeopardizes the viability of the raised muscle flap. The brachioradialis "wrap around" flap should not be raised if there is a non-functioning biceps brachii or brachialis, as the brachioradialis provides assistance with elbow flexion as well as supination when the forearm is fully pronated. Assuming that the arm and forearm musculature is intact, using the anconeus or brachioradialis as a pedicled interposition flap causes little functional loss.

PREOPERATIVE PLANNING

Before operative release and soft tissue interposition, patients must be carefully evaluated. The history should focus on the primary complaint. Patients must verbalize appropriate frustration with their disability from elbow stiffness to warrant release. It is also imperative that patients demonstrate the willingness and capacity for intensive rehabilitation. If the presenting complaint is predominantly pain, then contracture release will be futile. A focused surgical history needs to be elicited. Previous injuries and surgeries of the involved extremity offer critical information about the status of osseous and cartilaginous structures as well as the elbow's soft tissue envelope. Operative reports from previous surgeries help understand the integrity and location of possibly transposed neurovascular structures.

Elbow range of motion, stability, pain, and functional ability are assessed. The Mayo Elbow Performance Score serves as a summary of these findings. In addition, the examination includes assessment of forearm rotation and wrist and hand function. If there is physical evidence of nerve dysfunction, electrodiagnostic studies should be obtained to confirm the location of compression and to act as a baseline of nerve function. All of our patients have had previous surgeries, and as such, a careful assessment of incisions about the elbow with regard to the palpable and radiographic location of heterotopic ossification is essential. The integrity of the skin and subcutaneous tissues should be evaluated. Lingering soft tissue swelling, edema, or erythema may all point to additional diagnoses to be contended with before deciding on heterotopic bone excision.

Standard radiographs of the elbow are obtained with oblique views to improve visualization of ectopic ossification. We routinely perform computed tomography (CT) on cases of elbow heterotopic ossification where the congruity of the articular surface is in question and in all cases with proximal radioulnar synostosis. An axial CT scan with coronal and sagittal reformatted images is currently the most helpful method to visualize the location and extent of a bony bridge between the radius and ulna (Figs. 13-1 and 13-2). Vascular study of the elbow and proximal forearm should be considered if there are concerns about the integrity of the regional blood supply, especially in cases of pedicled soft tissue interposition. Unless there are specific historical or physical findings suggesting potential or indolent infection, we limit blood studies to those required for a prolonged general anesthetic.

The timing for intervention is somewhat nebulous and is certainly directed by physician bias. We do not believe there is sufficient scientific evidence to suggest that nuclear medicine scans or blood alkaline phosphatase levels are beneficial in the assessment or timing of surgical intervention. In reviewing the literature and comparing our experience, it would appear that waiting for fracture heal-

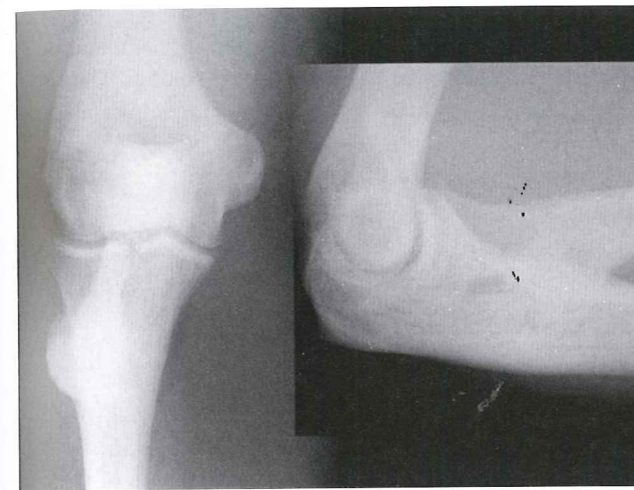

FIGURE 13-1

The anteroposterior and lateral elbow radiographs of a 42-year-old power lifter 8 weeks after a single incision repair of distal biceps tendon rupture. The forearm is ankylosed in mid pronation-supination.

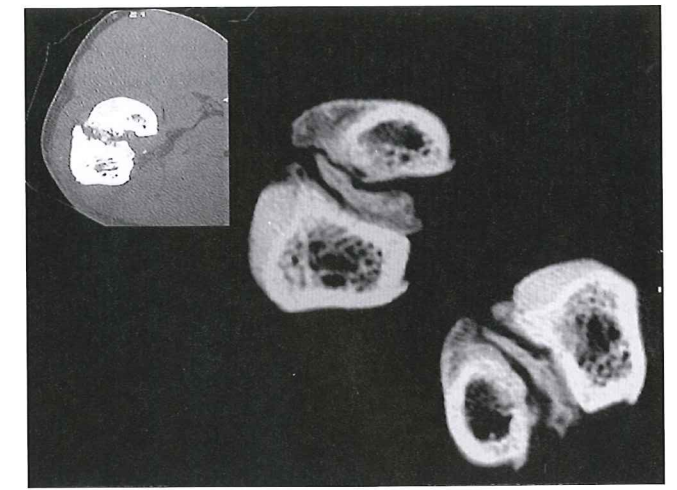


FIGURE 13-2

Coronal CT image reveals the extent of heterotopic bone involvement in the region of the bicipital tuberosity.

ing and ectopic bone maturation, defined as well-delineated borders, is the most commonly used parameters. This would suggest that operative intervention be carried out 4 to 12 months after injury.

Excision of heterotopic ossification and soft tissue flap interposition does not require a great deal of special equipment. We have listed a few items that facilitate operative intervention and postoperative rehabilitation in Table 13-1. In addition to the tools listed in the table, we have the following items readily available: a hinged fixator, radial head prosthetics, allograft tendon for ligament reconstruction, allograft fascia lata if local interposition material is not available, and a total elbow arthroplasty set when all else fails and the patient is the appropriate age.

SURGERY

Patient Positioning

Operative approach and patient positioning are determined by previous incisions, location of heterotopic bone or synostosis, and shoulder mobility. While many surgeons prefer to operate on the elbow with the affected extremity positioned across the patient's supine chest, we prefer to position

TABLE 13-1. Soft Tissue Interposition Flaps for Elbow Heterotopic Ossification: Operative Equipment

| Standard Equipment | Optional Equipment |
|---|--|
| Sterile tourniquet | Fluoroscopy |
| Retractors, thyroid type (long and narrow) | Hardware removal instruments |
| Lamina spreader | Total elbow arthroplasty |
| Vessel loops | Lidocaine infusion pump |
| Rongeurs (including Kerrison and pituitary) | Continuous passive motion machine |
| Osteotomes and curettes | Postoperative radiation therapy |
| Suture anchors | Static progressive vs. dynamic splinting |
| Hinged elbow distractor | |
| Tensor fascia lata allograft | |
| Closed suction drain | |

the patient with the affected extremity abducted onto a radiolucent table. The extremity is draped free up to the clavicle. If the shoulder is mobile, external rotation will present the medial and anterior aspects of the elbow while internal rotation presents the lateral and posterior elbow. The flexibility to effortlessly alternate between lateral and medial approaches facilitates complete excision of heterotopic bone about the elbow.

Technique

Exposure We do not use tourniquets for these cases. They are a detriment to tissue mobilization, mask small arterial bleeding, and lead to venous engorgement during prolonged cases. The initial increase in bleeding at the time of incision is mitigated by injecting the proposed incision with 0.25% bupivacaine and 1/200,000 dilute epinephrine solution. The incision is delayed 7 to 10 minutes to allow the epinephrine to affect local capillaries.

It is our preference to use a posterior skin incision for elbow release surgery. This window allows a "global" approach to the elbow and can be used to access the medial, lateral, and anterior sides of the joint. The skin incision is typically straight, passing 2 cm medial or lateral to the tip of the olecranon, but may be curvilinear to incorporate previously placed posteromedial or posterolateral surgical scars. Depending on the required heterotopic bone excision or hardware removal, the incision may extend from the proximal arm to the distal forearm. This dissection avoids injury to both the medial and the lateral brachial cutaneous nerves, preserving sensibility to the proximal forearm.

When employing this approach, it is critical to create thick soft tissue flaps. The skin incision is carried down to and includes the triceps fascia proximally and the extensor fascia of the forearm distally. This effectively creates robust fasciocutaneous flaps that can be elevated circumferentially about the elbow. The extent of elevation is dictated by the location of the joint involvement. If there is medial joint involvement, as determined by CT scan, or ulnar nerve symptoms, we address these first. If there is no involvement we go directly to the lateral elbow and proximal forearm. The dissection is carried to the medial intermuscular septum, and the ulnar nerve is identified as it passes from the anterior to the posterior compartment approximately 8 to 10 cm proximal to the medial epicondyle. Even if the ulnar nerve has been "transposed anteriorly" in previous procedures, we believe that it is critical to identify the entire medial intermuscular septum, and follow it to the humerus (Fig. 13-3). In cases in which the medial intermuscular septum has been excised in part or in whole, the dissection follows the medial border of the triceps until the humerus is encountered. When the ulnar nerve is found, it should be mobilized from the cubital tunnel, preferably with a small cuff of medial triceps to protect the nerve's vascular supply. The nerve is followed into the forearm until disappeared deeply between the heads of the flexor carpi ulnaris. Any tight scar or fascial bands crossing the nerve in this dissection are divided. The medial intermuscular septum is removed in its entirety. By following the ulnar nerve proximally in the arm, the median nerve and its accompanying brachial artery can be located along the anterior margin of the intermuscular septum. Alternatively, in arms that are not densely scarred the median nerve and brachial artery can be identified in the distal arm superior to the leading edge of the pronator teres origin as it runs medial to the substance of the biceps and brachialis muscles and just beneath the fibers of the bicipital aponeurosis. Excision of heterotopic bone involving the medial posterior and anterior elbow joint is conducted and described in greater detail in the next section.

Next, the lateral side of the elbow and involvement of the proximal forearm are addressed. In cases of anterolateral heterotopic ossification, the radial nerve is identified at mid-arm and followed distally. This is done by elevating the lateral flap in the same tissue plane as the medial dissection, between the muscular investing fascia and the muscle belly of the triceps. When the lateral intermuscular septum is encountered, the radial nerve should be identified and protected. Identifying the radial nerve in a scarred bed can be daunting. We therefore use the following strategies. First, inspect the undersurface of the flap; frequently the posterior antebrachial cutaneous branches of the radial nerve to arm and forearm are visible. These branches can be followed proximally into the lateral intermuscular septum where they are found to take off from the radial nerve proper (Fig. 13-4). If this landmark is not readily available, our second approach is to dissect the distal portion of the flap toward the lateral epicondyle. On reaching the lateral intermuscular septum, the dissection is directed cephalad. The triceps muscle belly is freed from the posterior aspect of the intermuscular septum. Small vessels and nerves seen entering the triceps muscle should be followed proximally; they will lead to the radial nerve proper. If these markers fail to lead to the nerve, cautiously proceed along the posterior intermuscular septum. Somewhere between 6 and 10 cm proximal to the tip of

the patient with the affected extremity abducted onto a radiolucent table. The extremity is draped free up to the clavicle. If the shoulder is mobile, external rotation will present the medial and anterior aspects of the elbow while internal rotation presents the lateral and posterior elbow. The flexibility to effortlessly alternate between lateral and medial approaches facilitates complete excision of heterotopic bone about the elbow.

Technique

Exposure We do not use tourniquets for these cases. They are a detriment to tissue mobilization, mask small arterial bleeding, and lead to venous engorgement during prolonged cases. The initial increase in bleeding at the time of incision is mitigated by injecting the proposed incision with 0.25% bupivacaine and 1/200,000 dilute epinephrine solution. The incision is delayed 7 to 10 minutes to allow the epinephrine to affect local capillaries.

It is our preference to use a posterior skin incision for elbow release surgery. This window allows a "global" approach to the elbow and can be used to access the medial, lateral, and anterior sides of the joint. The skin incision is typically straight, passing 2 cm medial or lateral to the tip of the olecranon, but may be curvilinear to incorporate previously placed posteromedial or posterolateral surgical scars. Depending on the required heterotopic bone excision or hardware removal, the incision may extend from the proximal arm to the distal forearm. This dissection avoids injury to both the medial and the lateral brachial cutaneous nerves, preserving sensibility to the proximal forearm.

When employing this approach, it is critical to create thick soft tissue flaps. The skin incision is carried down to and includes the triceps fascia proximally and the extensor fascia of the forearm distally. This effectively creates robust fasciocutaneous flaps that can be elevated circumferentially about the elbow. The extent of elevation is dictated by the location of the joint involvement. If there is medial joint involvement, as determined by CT scan, or ulnar nerve symptoms, we address these first. If there is no involvement we go directly to the lateral elbow and proximal forearm. The dissection is carried to the medial intermuscular septum, and the ulnar nerve is identified as it passes from the anterior to the posterior compartment approximately 8 to 10 cm proximal to the medial epicondyle. Even if the ulnar nerve has been "transposed anteriorly" in previous procedures, we believe that it is critical to identify the entire medial intermuscular septum, and follow it to the humerus (Fig. 13-3). In cases in which the medial intermuscular septum has been excised in part or in whole, the dissection follows the medial border of the triceps until the humerus is encountered. When the ulnar nerve is found, it should be mobilized from the cubital tunnel, preferably with a small cuff of medial triceps to protect the nerve's vascular supply. The nerve is followed into the forearm until disappeared deeply between the heads of the flexor carpi ulnaris. Any tight scar or fascial bands crossing the nerve in this dissection are divided. The medial intermuscular septum is removed in its entirety. By following the ulnar nerve proximally in the arm, the median nerve and its accompanying brachial artery can be located along the anterior margin of the intermuscular septum. Alternatively, in arms that are not densely scarred the median nerve and brachial artery can be identified in the distal arm superior to the leading edge of the pronator teres origin as it runs medial to the substance of the biceps and brachialis muscles and just beneath the fibers of the bicipital aponeurosis. Excision of heterotopic bone involving the medial posterior and anterior elbow joint is conducted and described in greater detail in the next section.

Next, the lateral side of the elbow and involvement of the proximal forearm are addressed. In cases of anterolateral heterotopic ossification, the radial nerve is identified at mid-arm and followed distally. This is done by elevating the lateral flap in the same tissue plane as the medial dissection, between the muscular investing fascia and the muscle belly of the triceps. When the lateral intermuscular septum is encountered, the radial nerve should be identified and protected. Identifying the radial nerve in a scarred bed can be daunting. We therefore use the following strategies. First, inspect the undersurface of the flap; frequently the posterior antebrachial cutaneous branches of the radial nerve to arm and forearm are visible. These branches can be followed proximally into the lateral intermuscular septum where they are found to take off from the radial nerve proper (Fig. 13-4). If this landmark is not readily available, our second approach is to dissect the distal portion of the flap toward the lateral epicondyle. On reaching the lateral intermuscular septum, the dissection is directed cephalad. The triceps muscle belly is freed from the posterior aspect of the intermuscular septum. Small vessels and nerves seen entering the triceps muscle should be followed proximally; they will lead to the radial nerve proper. If these markers fail to lead to the nerve, cautiously proceed along the posterior intermuscular septum. Somewhere between 6 and 10 cm proximal to the tip of

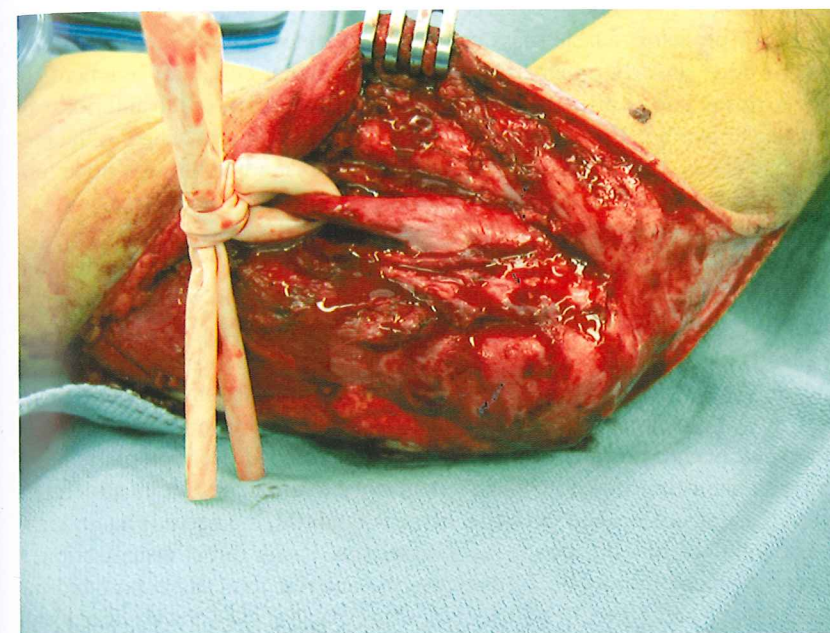


FIGURE 13-3

This previously "transposed ulnar nerve" sits directly on the medial epicondyle. It is essential to identify and protect the ulnar nerve before proceeding with capsular and heterotopic bone resection.

the lateral epicondyle, the nerve will be encountered passing along the spiral groove to pass through the lateral intermuscular septum to enter the anterior aspect of the arm. Once the radial nerve is identified, the lateral intermuscular septum is removed and the nerve followed distally. At the level of the elbow, the nerve is easily followed into the internervous plane between the proximal aspect of the brachioradialis and the distal aspect of the brachialis. Simple blunt dissection between these two muscles just superior to the joint line will reveal the radial nerve before it dives under the supinator more distally.

Excision of Heterotopic Bone The excision of heterotopic bone and the scarred joint capsule follows. Anterior heterotopic bone frequently resides in the distal aspect of the brachialis muscle. It can extend medially and laterally encasing the collateral ligaments or even neighboring neurovascular structures. If a medial approach is chosen, entrance to the joint capsule and distal aspect of the brachialis can be achieved by exploiting the internervous plane between the ulnar innervated

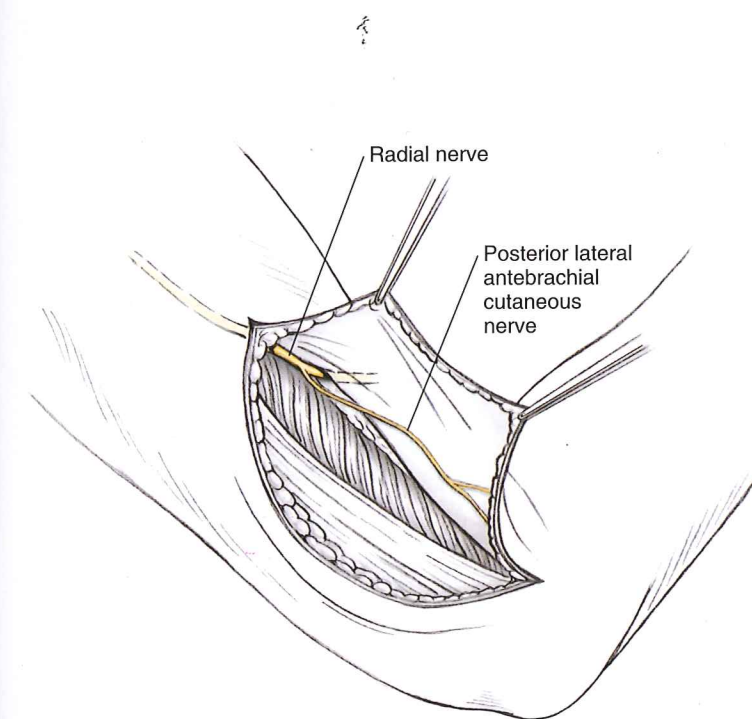


FIGURE 13-4

The posterior antebrachial cutaneous nerve is identified distally and followed proximally into the lateral intermuscular septum. This cutaneous nerve leads to the radial nerve proper. The radial nerve proper can then be followed from into the anterior compartment of the arm.

flexor carpi ulnaris and the median innervated palmaris longus, flexor carpi radialis, and pronator teres. Alternatively, the flexor-pronator muscle mass can be sharply elevated off the medial epicondyle, carefully preserving the underlying anterior band of the medial collateral ligament. In severely contracted elbows, this exposure affords uncompromised visualization of the anterior capsule and crossing neurovascular bundle. This elevated myofascial flap can be reattached to the medial epicondyle with multiple suture anchors or sutured down to the epicondyle through bone tunnels. If the flexor-pronator mass is released, consideration can be given to submuscular transposition of the ulnar nerve.

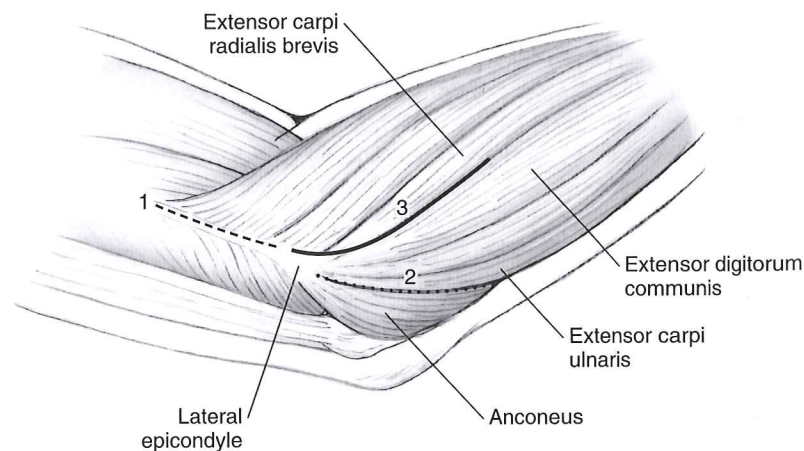
The anterolateral aspect of the elbow is approached next. If there is complete elbow flexion and extension, the dissection is directed toward the posterolateral forearm. In cases in which the anterior joint needs to be exposed, one of three intervals is used (Fig. 13-5). The first approach, and in our experience the most frequently used, elevates the proximal most portion of the muscle taking origin from the medial epicondyle, usually the brachioradialis and a portion of the extensor carpi radialis longus. The dissection is carried medially, sweeping the brachialis from the front of the humerus. The interval between this muscle and the anterior joint capsule is developed. Heterotopic bone, if encountered, is dissected with blunt-tipped elevators and left attached to the anterior joint structures. If the relationship between these structures and the radial nerve is doubtful, the nerve is again identified in the distal arm and followed into the area of joint dissection. Under direct visualization, a blunt right-angled retractor is placed in the interval between the anterior joint dissection and the more superficially located muscle and nerve. The dissection stops distally when the coronoid process is encountered or the heterotopic bone becomes confluent the forearm bones. The entire anterior joint capsule and the heterotopic bone are removed. The coronoid fossa is cleared of soft tissues. Two other approaches to the anterolateral elbow consist of developing the interval between the anconeus and extensor carpi ulnaris, or the interval between the extensor carpi radialis brevis origin and the extensor digitorum communis. Both dissections allow easy access to the joint capsule overlying the radial head and neck. The capsular, radial, and annular portion of the lateral collateral ligament complex can be reflected or excised to expose the joint. The ulnar portion of the lateral collateral ligament, if not encased in ectopic bone, should be preserved (Fig. 13-6). More often than not, elevation of the lateral elbow complex from the ulna is necessary. The ligamentous attachments will be reconstructed after the ectopic bone has been excised. If visualization of the anterior joint capsule is insufficient with these intermuscular approaches, the origin of the brachioradialis and extensor carpi radialis longus is elevated as described previously.

The posterior elbow joint is approached from the lateral side by elevating the triceps muscle from the lateral column of the distal humerus and developing the interval between triceps muscle and the posterior joint capsule. The triceps muscle insertion onto the olecranon is preserved. The posterior capsule, the contents of the olecranon fossa, and any bony impediments to elbow motion arising from these posterior structures are debrided.

Proximal Radioulnar Synostosis Takedown In cases in which pathology is limited to the proximal radioulnar joint in the vicinity of the bicipital tuberosity, the synostosis may be approached by sweeping the entire anconeus and ulnar origin of the extensor carpi ulnaris complex off of the

FIGURE 13-5

Three intervals used to approach the anterior lateral elbow. (1) Partial elevation of the muscles taking origin from the lateral epicondyle, the brachioradialis, and cephalad portion of the extensor carpi ulnaris. (2) Anconeus and extensor carpi ulnaris. (3) Extensor carpi radialis brevis and extensor digitorum communis.



flexor carpi ulnaris and the median innervated palmaris longus, flexor carpi radialis, and pronator teres. Alternatively, the flexor-pronator muscle mass can be sharply elevated off the medial epicondyle, carefully preserving the underlying anterior band of the medial collateral ligament. In severely contracted elbows, this exposure affords uncompromised visualization of the anterior capsule and crossing neurovascular bundle. This elevated myofascial flap can be reattached to the medial epicondyle with multiple suture anchors or sutured down to the epicondyle through bone tunnels. If the flexor-pronator mass is released, consideration can be given to submuscular transposition of the ulnar nerve.

The anterolateral aspect of the elbow is approached next. If there is complete elbow flexion and extension, the dissection is directed toward the posterolateral forearm. In cases in which the anterior joint needs to be exposed, one of three intervals is used (Fig. 13-5). The first approach, and in our experience the most frequently used, elevates the proximal most portion of the muscle taking origin from the lateral epicondyle, usually the brachioradialis and a portion of the extensor carpi radialis longus. The dissection is carried medially, sweeping the brachialis from the front of the humerus. The interval between this muscle and the anterior joint capsule is developed. Heterotopic bone, if encountered, is dissected with blunt-tipped elevators and left attached to the anterior joint structures. If the relationship between these structures and the radial nerve is doubtful, the nerve is again identified in the distal arm and followed into the area of joint dissection. Under direct visualization, a blunt right-angled retractor is placed in the interval between the anterior joint dissection and the more superficially located muscle and nerve. The dissection stops distally when the coronoid process is encountered or the heterotopic bone becomes confluent the forearm bones. The entire anterior joint capsule and the heterotopic bone are removed. The coronoid fossa is cleared of soft tissues. Two other approaches to the anterolateral elbow consist of developing the interval between the anconeus and extensor carpi ulnaris, or the interval between the extensor carpi radialis brevis origin and the extensor digitorum communis. Both dissections allow easy access to the joint capsule overlying the radial head and neck. The capsular, radial, and annular portion of the lateral collateral ligament complex can be reflected or excised to expose the joint. The ulnar portion of the lateral collateral ligament, if not encased in ectopic bone, should be preserved (Fig. 13-6). More often than not, elevation of the lateral elbow complex from the ulna it is necessary. The ligamentous attachments will be reconstructed after the ectopic bone has been excised. If visualization of the anterior joint capsule is insufficient with these intermuscular approaches, the origin of the brachioradialis and extensor carpi radialis longus is elevated as described previously.

The posterior elbow joint is approached from the lateral side by elevating the triceps muscle from the lateral column of the distal humerus and developing the interval between triceps muscle and the posterior joint capsule. The triceps muscle insertion onto the olecranon is preserved. The posterior capsule, the contents of the olecranon fossa, and any bony impediments to elbow motion arising from these posterior structures are debrided.

Proximal Radioulnar Synostosis Takedown In cases in which pathology is limited to the proximal radioulnar joint in the vicinity of the bicapital tuberosity, the synostosis may be approached by sweeping the entire anconeus and ulnar origin of the extensor carpi ulnaris complex off of the

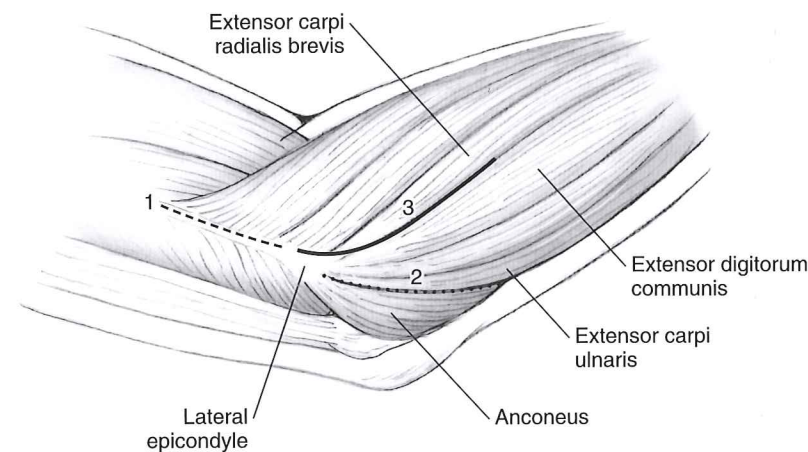


FIGURE 13-5

Three intervals used to approach the anterior lateral elbow. (1) Partial elevation of the muscles taking origin from the lateral epicondyle, the brachioradialis, and cephalad portion of the extensor carpi ulnaris. (2) Anconeus and extensor carpi ulnaris. (3) Extensor carpi radialis brevis and extensor digitorum communis.

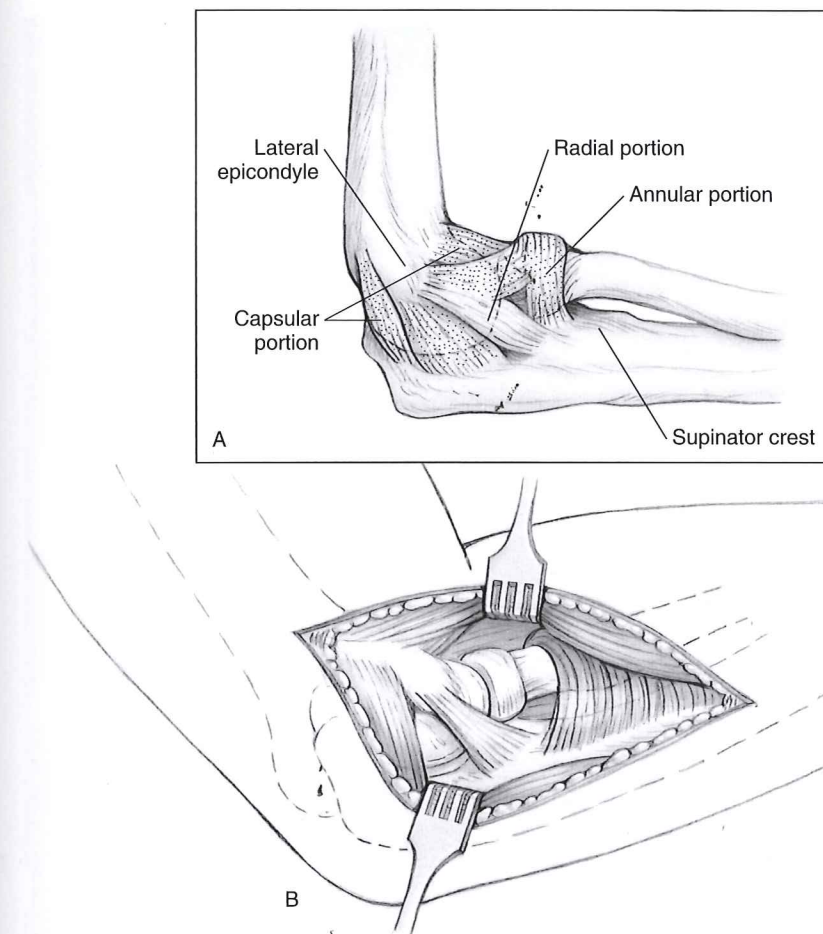


FIGURE 13-6

A: Lateral collateral ligament complex of the elbow consisting of the capsular, radial, and annular portions (stippled) removed to expose the lateral elbow articulations. **B:** The stippled portion of Figure 13-6A has been removed, exposing the radial head and neck, and the distal humerus. Preserving the ulnar portion of lateral collateral ligament (shaded area), when possible, preserves elbow stability.

posterolateral edge of the proximal ulna (Fig. 13-7A-C). The dissection along the proximal ulna is carried along the radial edge to the base of the synostosis and followed along the interosseous space until the radius is encountered. If the forearm can be pronated, there should be no danger to the posterior interosseous nerve. A pronated forearm allows the posterior interosseous nerve to lay anteriorly and medially protected in the substance of the supinator muscle. However, a supinated forearm does just the opposite. In cases where the forearm is ankylosed in supination, consideration should be given to locating the posterior interosseous nerve before the posterior dissection. This usually requires an anterior incision immediately adjacent to the ulnar border of the brachioradialis. The radial nerve is found in the interval between the brachioradialis and brachialis muscle and followed distally until it is seen to divide into the posterior interosseous nerve (PIN) and the superficial branch of the radial nerve. The PIN is followed distally into the supinator muscle. The arcade of Frohse is divided along with fibrosed muscle and scarred tissue that could lead to potential compression injury during the dissection. The posterior dissection is then resumed.

Once the anconeus is elevated, tissue retraction is maintained by broad right-angled retractors or broad Homan retractors. Narrow lever arm type retractors are avoided. Although anecdotal, it is thought that narrow retractors place excessive pressure on adjacent neurovascular structures, especially the PIN.

Synostosis resection proceeds using a combination of small rongeurs, osteotomes, and Kerrison rongeurs. Small lamina spreaders help retract the proximal radius and proximal ulna, opening up the space between. Once the synostosis has been released and there is freedom between the two bones, the lamina spreader offers greater direct visualization of remaining ectopic bone. The synostosis can now be excised down to the native cortices of the proximal radius and proximal ulna. It is imperative that the exposed bony surfaces be debrided to a smooth surface. Sharp edges combined with forearm rotation will penetrate and disrupt interposition flaps.

Intraoperative radiography is used to demonstrate the thoroughness of the ectopic bone excision. On completion of the resection, the surgical field is irrigated with 3 L of normal saline. Bleeding

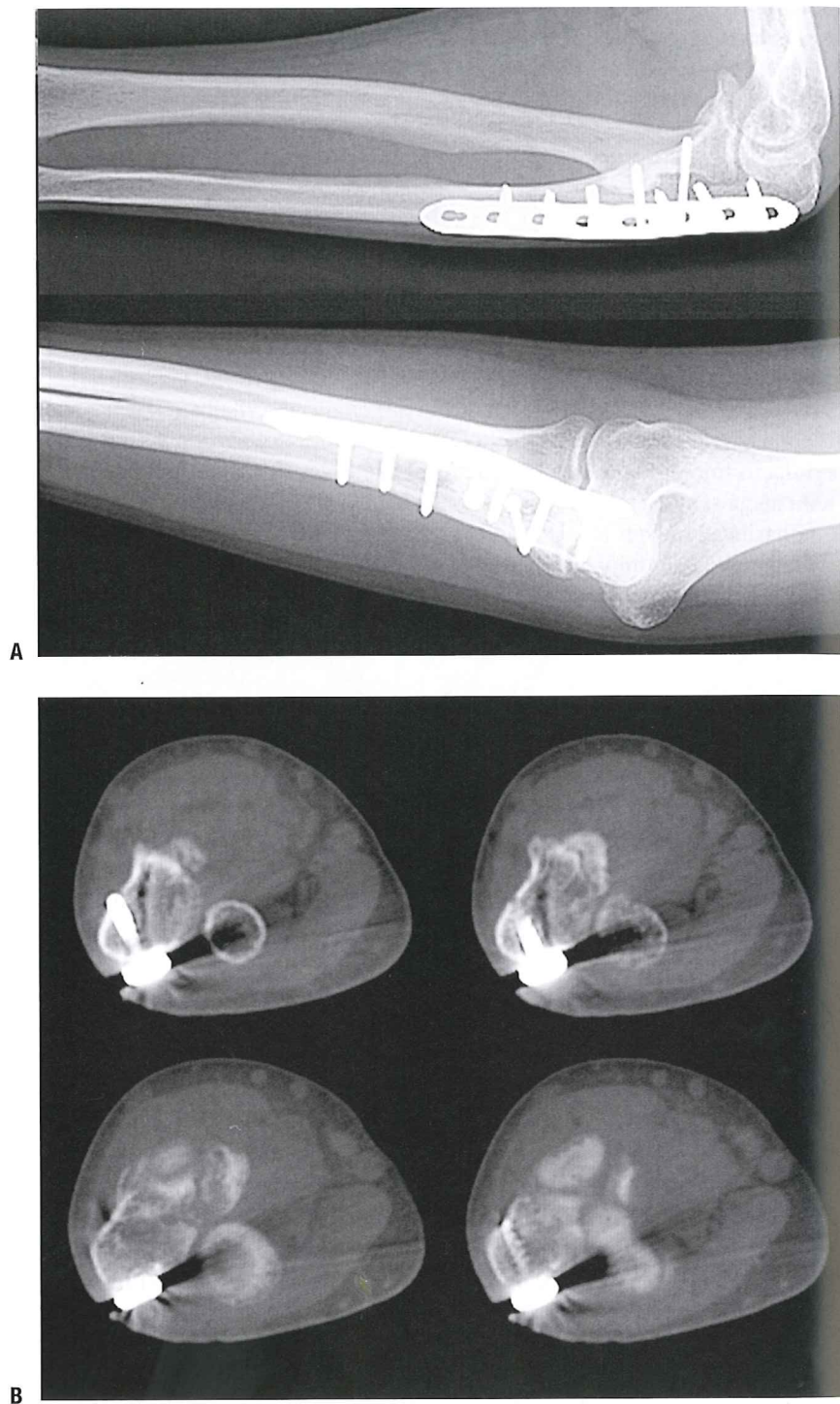
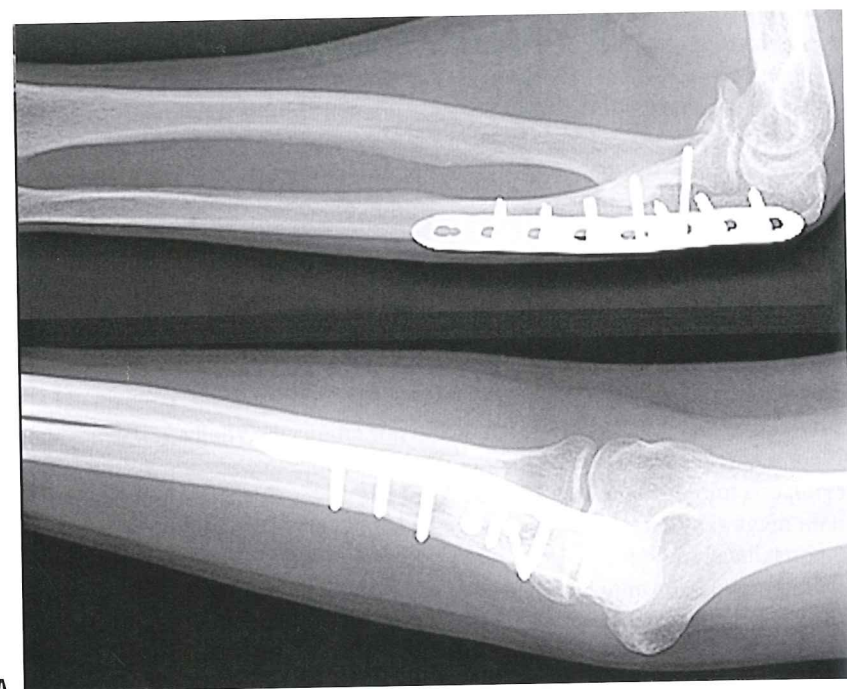
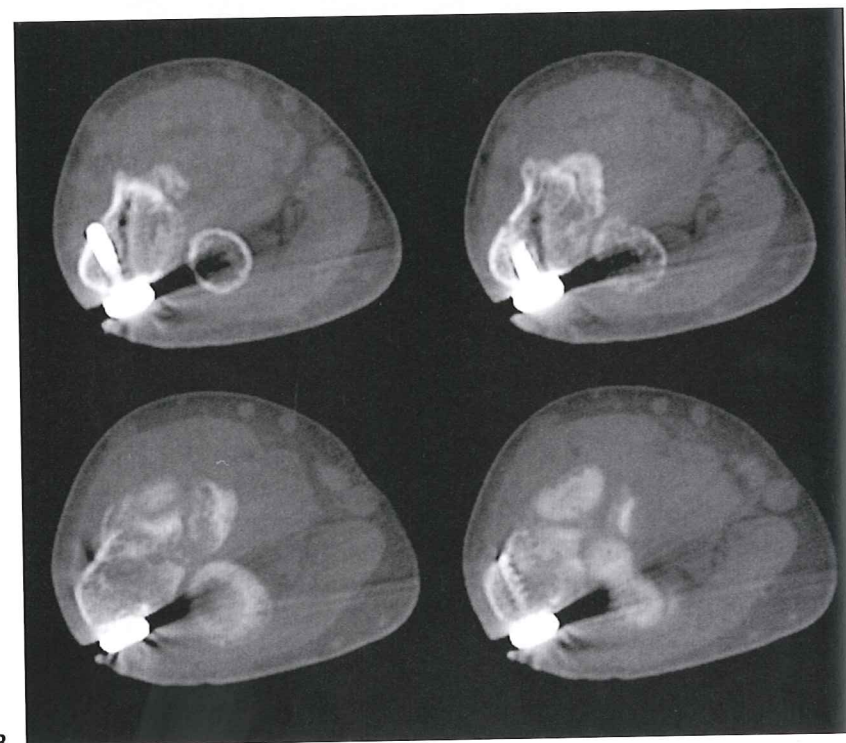


FIGURE 13-7

A: This patient developed a radioulnar synostosis after treatment of a Monteggia fracture. **B:** The CT scans demonstrate the location of the synostosis adjacent to the bicipital tuberosity. (*Continued*)



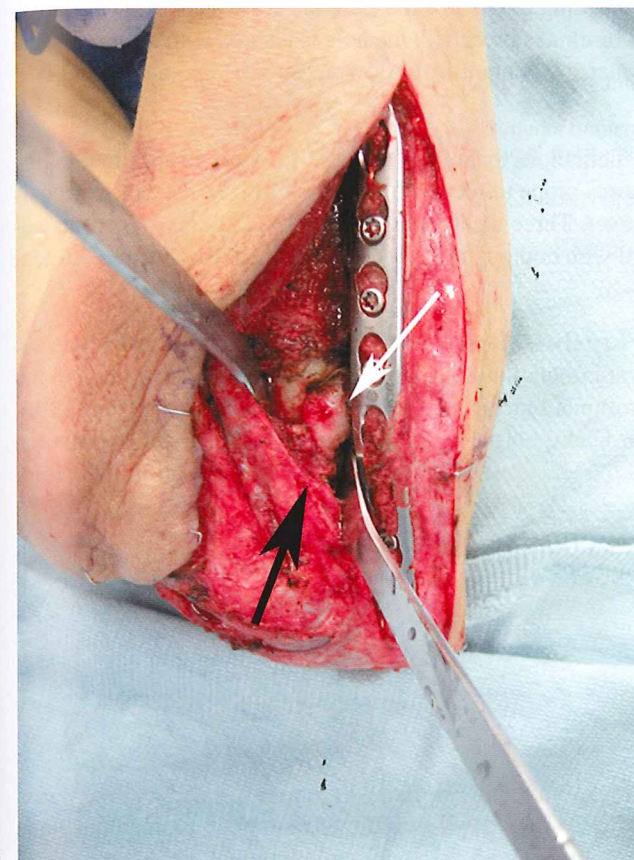
A



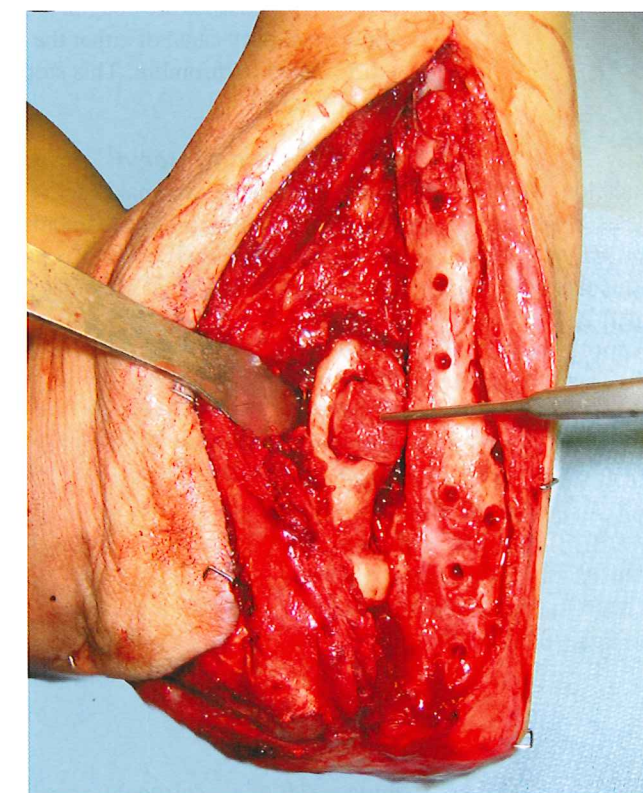
B

FIGURE 13-7

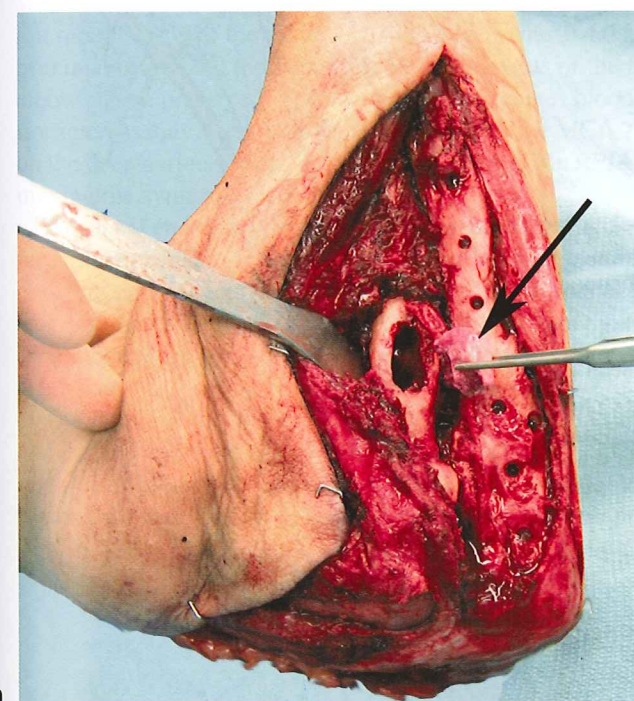
A: This patient developed a radioulnar synostosis after treatment of a Monteggia fracture. **B:** The CT scans demonstrate the location of the synostosis adjacent to the bicipital tuberosity. (Continued)



C



E



D

FIGURE 13-7

Continued **C:** The entire anconeus and extensor carpi ulnaris complex have been elevated from the ulna (*dark arrow*), exposing the bridge of heterotopic bone between the radius and ulna (*light arrow*). **D:** The synostosis encased the bicipital tuberosity and tendon. The ectopic bone was removed, and the tendon left attached to a block of heterotopic bone (*dark arrow*). The resection exposed the medullary canal of the radius. The fixation plate was removed. **E:** The medullary canal is packed with allograft bone chips to minimize extrusion of marrow content. The biceps tendon and attached bone block are pushed into the medullary canal and secured with a stout nonabsorbable

points in soft tissues are coagulated, and bleeding points in exposed bone are sealed with bone wax. If the medullary canal of either the radius or ulna is breached, the hole is packed with allograft bone graft soaked in thrombin. This stops the marrow content from flowing into the operative field (see Fig. 13-7D,E).

Interposition Material Even with meticulous technique, the proximity of the proximal radius and ulna to each other makes these structures prone to recurrent synostosis. Some type of interposition material is a useful preventative adjunct. Three techniques are discussed in the following section. Each of these procedures is preceded with copious irrigation of the synostosis site and diligent hemostasis as described previously.

Pedicle Anconeus Myofascial Flap Interposition The anconeus myofascial flap receives its blood supply from the collateral circulation about the elbow, predominantly the medial collateral artery (MCA) branch of the profunda brachii artery and venae comitantes (Fig. 13-8). The muscle is elevated from the posterior lateral border of the ulna, usually in a distal to proximal direction. The distal edge starts roughly at the junction of the proximal and mid one-third of the fore-

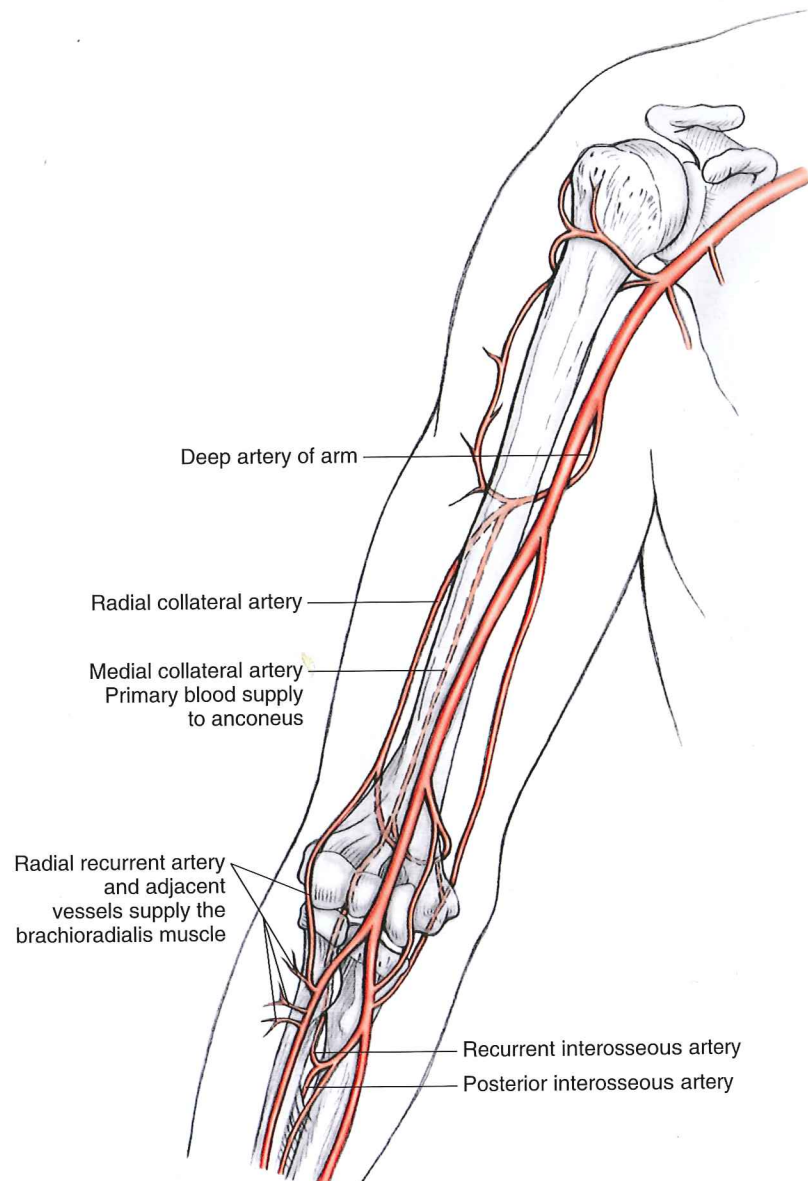


FIGURE 13-8

The arterial anatomy of the distal arm. The medial collateral artery (MCA), a branch of the profunda brachii, is the primary blood supply to the anconeus. The radial recurrent artery (RRA), a branch of the radial artery, and small arterial branches within 3 cm of the RRA, provide the primary blood supply to the brachioradialis muscle.

points in soft tissues are coagulated, and bleeding points in exposed bone are sealed with bone wax. If the medullary canal of either the radius or ulna is breached, the hole is packed with allograft bone graft soaked in thrombin. This stops the marrow content from flowing into the operative field (see Fig. 13-7D,E).

Interposition Material Even with meticulous technique, the proximity of the proximal radius and ulna to each other makes these structures prone to recurrent synostosis. Some type of interposition material is a useful preventative adjunct. Three techniques are discussed in the following section. Each of these procedures is preceded with copious irrigation of the synostosis site and diligent hemostasis as described previously.

Pedicle Anconeus Myofascial Flap Interposition The anconeus myofascial flap receives its blood supply from the collateral circulation about the elbow, predominantly the medial collateral artery (MCA) branch of the profunda brachii artery and venae comitantes (Fig. 13-8). The muscle is elevated from the posterior lateral border of the ulna, usually in a distal to proximal direction. The distal edge starts roughly at the junction of the proximal and mid one-third of the fore-

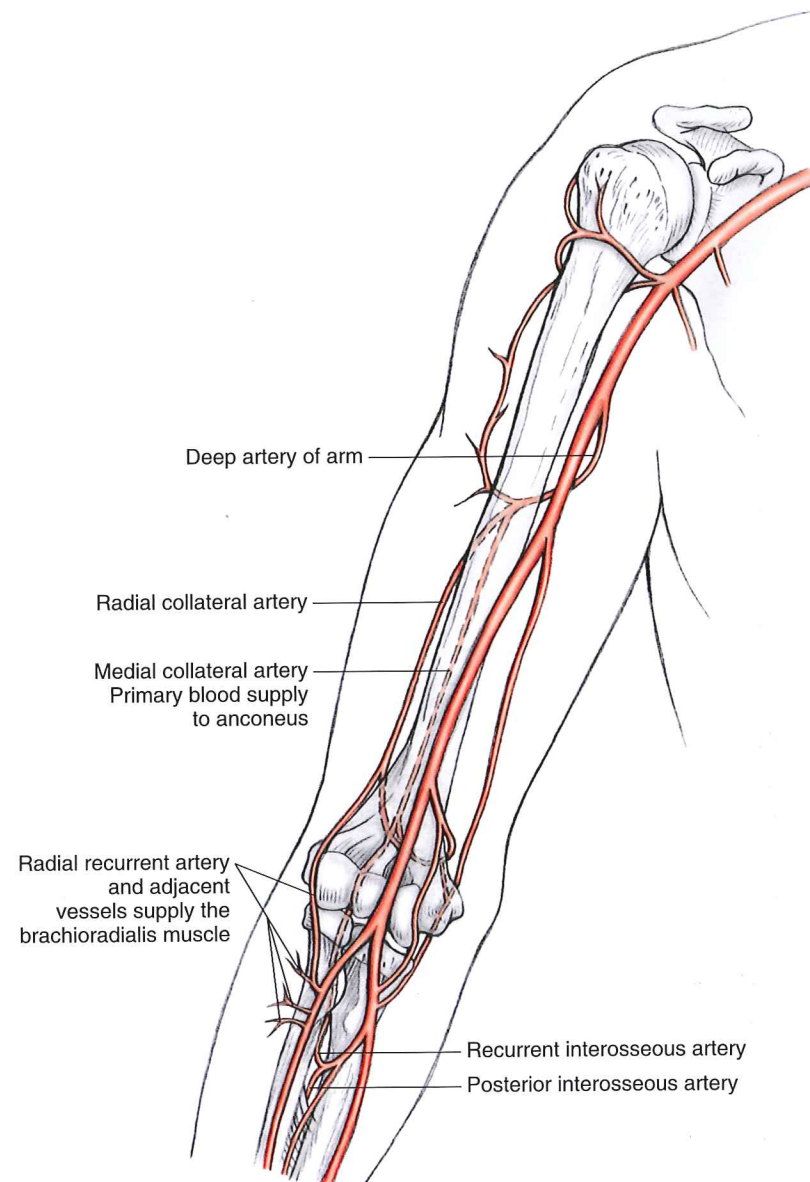


FIGURE 13-8

The arterial anatomy of the distal arm. The medial collateral artery (MCA), a branch of the profunda brachii, is the primary blood supply to the anconeus. The radial recurrent artery (RRA), a branch of the radial artery, and small arterial branches within 3 cm of the RRA, provide the primary blood supply to the brachioradialis muscle.

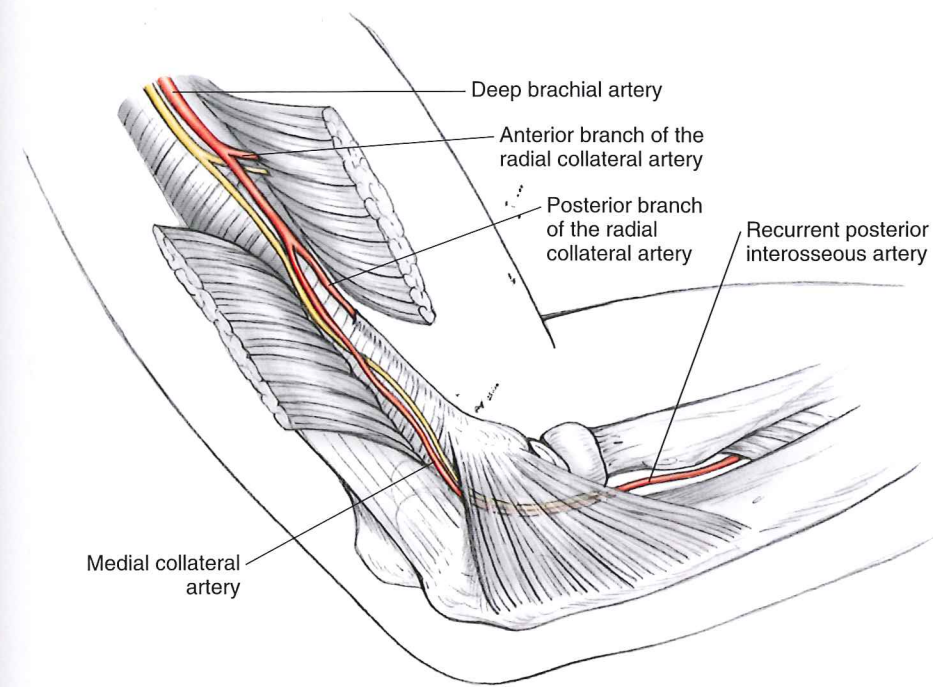


FIGURE 13-9

In addition to the medial collateral artery (MCA), the anconeus receives blood supply distally from the recurrent posterior interosseous artery (RPIA). These vessels (the MCA and RPIA) frequently form an anastomosis on the deep surface of the anconeus. The RPIA is frequently sacrificed in the process of elevating this flap. (From Schmidt CC, Kohut GN, Greenberg JA, Kann SE, Idler RS, Kiefhaber TR. The anconeus muscle flap: its anatomy and clinical application. *J Hand Surg Am.* 1999;24(2):359-369. With permission.)

arm. A stout septum separates this muscle from the flexor carpi ulnaris. Identification of this septum and the anconeus itself may be difficult if previous surgery or initial trauma has injured the muscle. In these cases, an alternative material may be required.

Elevation of the flap is carried up to the lateral epicondyle until sufficient freedom exists to permit mobilization of the tissue's leading edge to the distal extent of the synostosis. By protecting the proximal origin and the lateral fascial attachments of the triceps, the medial collateral artery of the elbow can be preserved. The anconeus also receives blood supply distally from the recurrent posterior interosseous artery (RPIA). These vessels (the MCA and RPIA) frequently form an anastomosis on the deep surface of the anconeus (Fig. 13-9). The RPIA is usually sacrificed in the process of removing the synostosis or in elevating this flap.

The distal end of the anconeus flap is attached to the ulnar edge of the biceps tuberosity while the forearm is placed in full pronation. Sutures alone or suture anchors placed into the proximal radius or biceps tendon secure the anconeus flap with mattress or Bunnell locking stitches. Now, as the forearm is supinated, the anconeus will be drawn into the proximal radioulnar space where the synostosis previously lay—creating a thin, pedicled interposition flap of viable muscle and fascia (Fig. 13-10).

The utility of the anconeus myofascial interposition flap has recently been expanded by Morrey and Schneeberger to include soft tissue interposition between the capitellum and the proximal radius in cases of radial head excision or failed radial head arthroplasty (Fig. 13-11). Three interposition options are described: type I, interposition at the radiocapitellar joint; type II, the muscle is brought

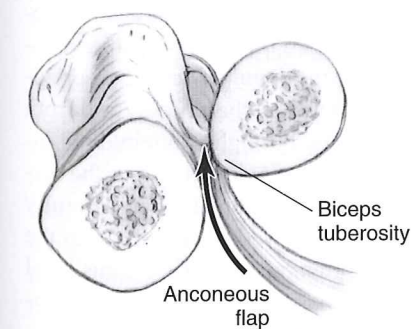


FIGURE 13-10

With the forearm placed in full pronation, the distal end of the anconeus flap is attached to the ulnar edge of the biceps tuberosity (BT) with a suture anchor or direct stitch into the biceps tendon. As the forearm is supinated (arrow), the anconeus will be drawn into the proximal radioulnar space.

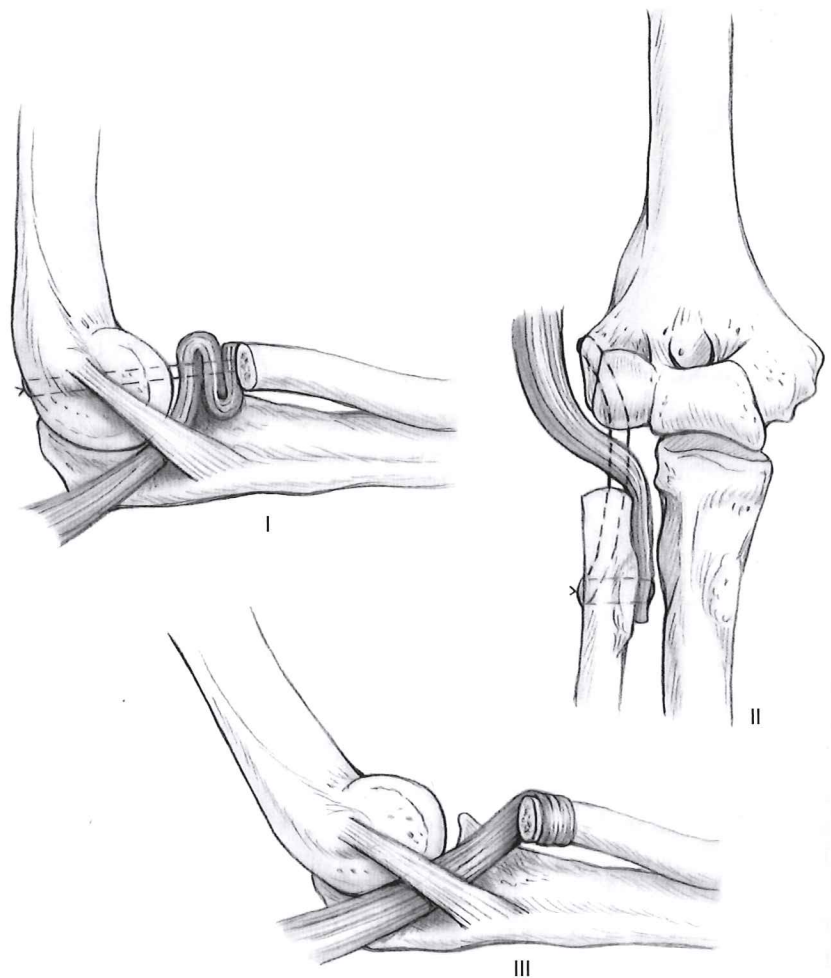


FIGURE 13-11

Three interposition options for the anconeus flap after radial head resection: type I, radiocapitellar joint; type II, radiocapitellar and proximal radioulnar joint; and type III, proximal radioulnar wrap. (From Morrey BF, Schneeberger AG. Anconeus arthroplasty: a new technique for reconstruction of the radiocapitellar and/or proximal radioulnar joint. *J Bone Joint Surg Am.* 2002;84-A(11):1960–1969. With permission.)

posterior to the intact fibers of the ulnar portion of the lateral ulnar collateral ligament and interposed between radiocapitellar and proximal radioulnar joint; and type III, proximal radioulnar wrap. In each type of interposition, the muscle is secured with stout suture placed through drill holes.

Distally based anconeus myofascial flaps composed of anconeus and some neighboring extensor carpi ulnaris have been described. This flap depends on an intact RPIA for its blood supply, a small vessel that is easily injured during the initial fracture fixation or during resection of a synostosis. Distally based anconeus flaps may have application in the management of soft tissue defects not associated with elbow fractures such as burns or skin avulsion but should be used with caution in the setting of synostosis resection.

The proximally based anconeus pedicle flap can also be used to provide soft tissue coverage of small defects about the traumatized elbow. Three areas where this muscle will reach is the lateral epicondyle, the posterior surface of the olecranon, and the distal radial aspect of the triceps insertion into the olecranon. The muscle is elevated, rotated over the defect, and covered with split thickness skin grafts.

Pedicled Brachioradialis Myofascial Flap Interposition The brachioradialis interposition flap is useful when resection of a radioulnar synostosis is performed through a combined anterior and posterior approach. The posterior incision and approach is the same as described previously: the anconeus-extensor carpi ulnaris interval is developed, the supinator sharply elevated from the ulna, and the synostosis excised. The anterior approach is conducted through a longitudinal incision made along the ulnar border of the brachioradialis, from the elbow flexion crease to the distal forearm. The superficial branch of the radial nerve is located in the distal forearm and carefully dissected from the undersurface of the brachioradialis. This nerve is followed proximally into the cephalad region of antecubital fossa where it is found to branch from the radial nerve. At this level the radial nerve branches to the brachioradialis, and extensor carpi radialis muscle may be encoun-

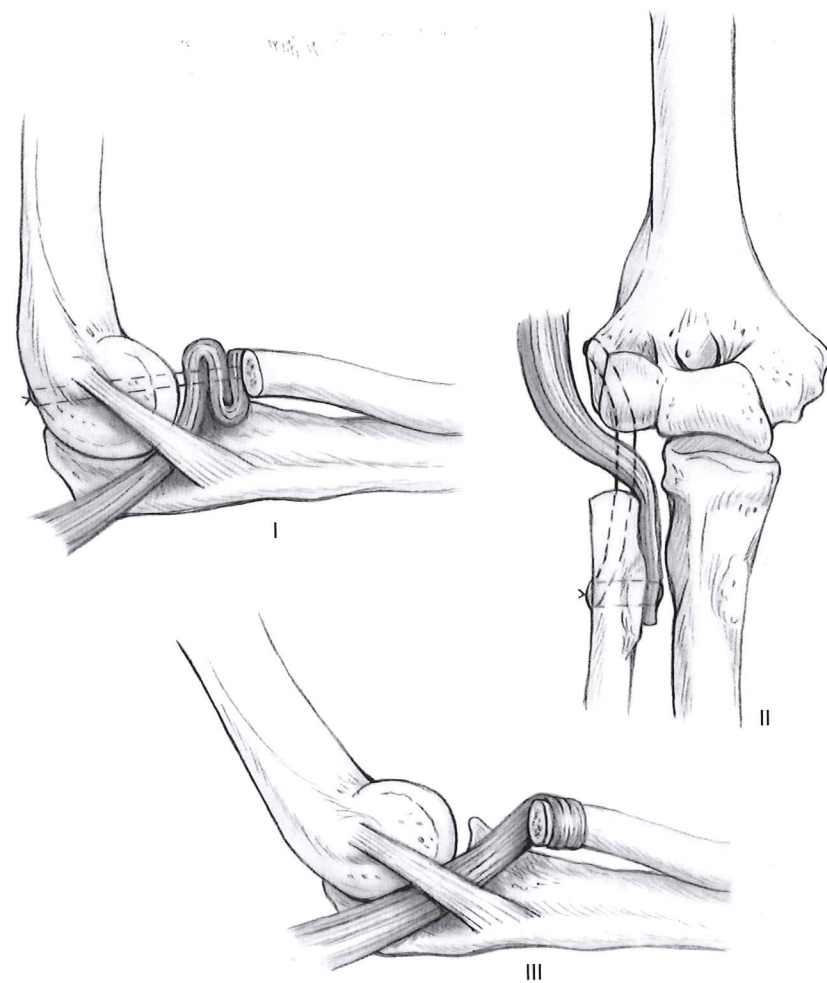


FIGURE 13-11

Three interposition options for the anconeus flap after radial head resection: type I, radiocapitellar joint; type II, radiocapitellar and proximal radioulnar joint; and type III, proximal radioulnar wrap. (From Morrey BF, Schneeberger AG. Anconeus arthroplasty: a new technique for reconstruction of the radiocapitellar and/or proximal radioulnar joint. *J Bone Joint Surg Am.* 2002;84-A(11):1960–1969. With permission.)

posterior to the intact fibers of the ulnar portion of the lateral ulnar collateral ligament and interposed between radiocapitellar and proximal radioulnar joint; and type III, proximal radioulnar wrap. In each type of interposition, the muscle is secured with stout suture placed through drill holes.

Distally based anconeus myofascial flaps composed of anconeus and some neighboring extensor carpi ulnaris have been described. This flap depends on an intact RPIA for its blood supply, a small vessel that is easily injured during the initial fracture fixation or during resection of a synostosis. Distally based anconeus flaps may have application in the management of soft tissue defects not associated with elbow fractures such as burns or skin avulsion but should be used with caution in the setting of synostosis resection.

The proximally based anconeus pedicle flap can also be used to provide soft tissue coverage of small defects about the traumatized elbow. Three areas where this muscle will reach is the lateral epicondyle, the posterior surface of the olecranon, and the distal radial aspect of the triceps insertion into the olecranon. The muscle is elevated, rotated over the defect, and covered with split thickness skin grafts.

Pedicle Brachioradialis Myofascial Flap Interposition The brachioradialis interposition flap is useful when resection of a radioulnar synostosis is performed through a combined anterior and posterior approach. The posterior incision and approach is the same as described previously: the anconeus–extensor carpi ulnaris interval is developed, the supinator sharply elevated from the ulna, and the synostosis excised. The anterior approach is conducted through a longitudinal incision made along the ulnar border of the brachioradialis, from the elbow flexion crease to the distal forearm. The superficial branch of the radial nerve is located in the distal forearm and carefully dissected from the undersurface of the brachioradialis. This nerve is followed proximally into the cephalad region of antecubital fossa where it is found to branch from the radial nerve. At this level the radial nerve branches to the brachioradialis, and extensor carpi radialis muscle may be encoun-

tered and is protected. Most important, the posterior interosseous nerve branch is identified and followed into the substance of the supinator muscle. The stout fibers on the leading edge of the supinator, the arcade of Frohse, are a potential source for compression during the remainder of the procedure and are divided. Simultaneously with the dissection of the radial nerve, the radial artery and its branches to the lateral elbow are encountered and protected. The largest of these branches, the radial recurrent artery, is found crossing from ulnar to radial, just distal to the biceps tendon (see Fig. 13-8). Care is taken to preserve not only the radial recurrent artery, but also the branches of the radial artery just distal to the radial recurrent artery. While the proximal aspect of the brachioradialis muscle belly is vascularized by the radial recurrent artery, the distal aspect of the muscle receives its blood supply from the arborization of the radial artery approximately 3 cm distal to the radial recurrent artery. In this dissection the median nerve and the ulnar artery are shielded by the medially retracted flexor-pronator muscle mass on the ulnar aspect of the proximal forearm.

Once these pertinent neurovascular structures are dissected free and protected, attention can be turned to the synostosis excision. Typically, the heterotrophic bone is found within or deep to the supinator muscle as it extends between the proximal radius and ulna. This anterior approach is helpful to visualize and debride the full extent of bridging bone in complex or revision cases of synostosis resection. After the synostosis has been taken down and the exposed bone edges covered with bone wax, the pedicle brachioradialis myofascial interposition flap is raised (see Fig. 13-12).

The tendon of the brachioradialis is divided and the muscle raised from distal to proximal. The previously identified neurovascular structures are left intact. Although the muscle can be released proximally from its origin on the lateral epicondyle and lateral intermuscular septum, this is usually not necessary; the muscle typically provides enough length for interposition between the proximal radius and ulna.

The muscle is interposed between the radius and ulna from anterior to posterior and secured in one of two ways. The first is to secure muscle to the posterior surface of the fully supinated radius using suture anchors or drill holes. When the forearm is pronated, the muscle is advanced into the interosseous space. The second method, introduced by Diego Fernandez, wraps the muscle around the proximal radius, deep to the superficial branch of the radial nerve, and is sutured to itself with locking sutures. Passing the stitches through the muscle fascia as well as through some of the tendinous fibers optimizes the fixation of this interposition flap to the bone.

In addition to being used for an interposition material, the brachioradialis can be used as a myofasciocutaneous flap to provide coverage for medium-sized elbow defects. The skin over the brachioradialis, centered on the radial recurrent artery, may be harvested up to 2 to 3 cm in width and 6 to 10 cm in length from proximal to distal. A narrow skin paddle permits primary closure of the donor site. Alternatively, the muscle alone can be elevated, inset, and split thickness skin graft is applied over it. The brachioradialis flap can be safely rotated to reach soft tissue defects involving the antecubital fossa, the volar one-third of the forearm, and the posterolateral aspect of the elbow between the lateral epicondyle and the olecranon.

Tensor Fascia Lata Interposition There are certainly cases of heterotopic ossification and radioulnar synostosis in which transposing a local muscle flap may be difficult or impossible. Most frequently these are cases in which the anconeus was injured during the initial traumatic event and where the extensive dissection of the brachioradialis muscle and additional scars are avoidable. In such circumstances, an alternative approach is to use tensor fascia lata (TFL) for interposition. Autograft TFL has the advantage of biocompatibility but the marked disadvantage of donor site morbidity including superficial nerve injury, additional site of scarring, and asymmetry of the thigh secondary to muscle herniation. Given the potential complications and the reality that the interposition graft (whether autograft or allograft) is not living tissue after harvest, we have abandoned the use of autograft TFL in favor of allograft.

The technique is straightforward. Following synostosis exposure and resection, the tensor fascia lata allograft is shaped to cover the exposed bone. A graft 10 to 12 cm long and 4 to 5 cm wide is required in most cases. The tensor fascia lata graft is wrapped around the most accessible bone, usually the ulna, and sutured into place using absorbable sutures (see Fig. 13-13). With a complete wrap, the graft can simply be sutured to itself or neighboring soft tissues to maintain its position. Another technique is to suture the graft to the exposed surface of the ulna, interpose it between the radius and ulna, securing to the exposed surface of the fully pronated radius with suture anchors. As the forearm supinates, the graft follows the radius and provides an effective barrier to reformation of the synostosis. The TFL, once secured to the underlying bone, creates an intact, but not water tight, sleeve

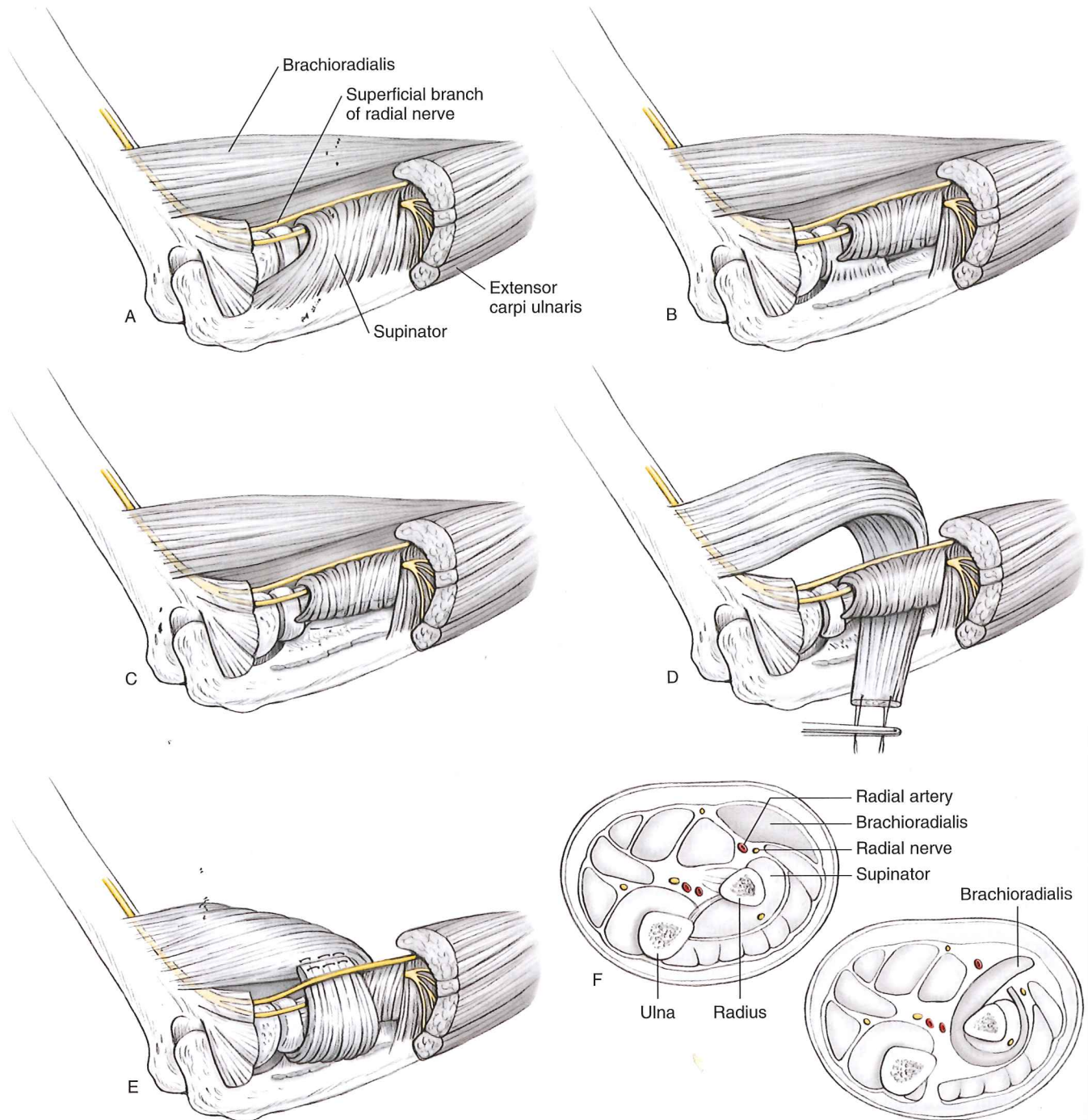


FIGURE 13-12

A: Posterior lateral approach (Kocher). Through a separate incision, the interval between the anconeus and extensor carpi ulnaris is developed. **B:** The supinator is sharply elevated off of the ulna exposing the radioulnar synostosis. **C:** The synostosis is removed and if necessary the interosseous ligament-membrane is excised. **D:** A separate anterior incision runs just ulnar to the brachioradialis muscle. The tendon is divided distally, the superficial branch of the radial nerve is separated from the under belly of the muscle, and the vascular bundles entering the muscle in the proximal forearm are preserved. The muscle is passed through the interosseous space created by the resection. **E:** The tail of the muscle is brought deep to the radial nerve and sutured to the proximal muscle belly. **F:** Cross-section of the forearm. Note the muscle passes radial to the radial artery in the mid forearm, distal to the biceps tendon and deep to the superficial branch of the radial nerve. (From Fernandez DL, Joneschild E. "Wrap around" pedicled muscle flaps for the treatment of recurrent forearm synostosis. *Tech Hand Up Extrem Surg.* 2004;8(2):102-109. With permission.)

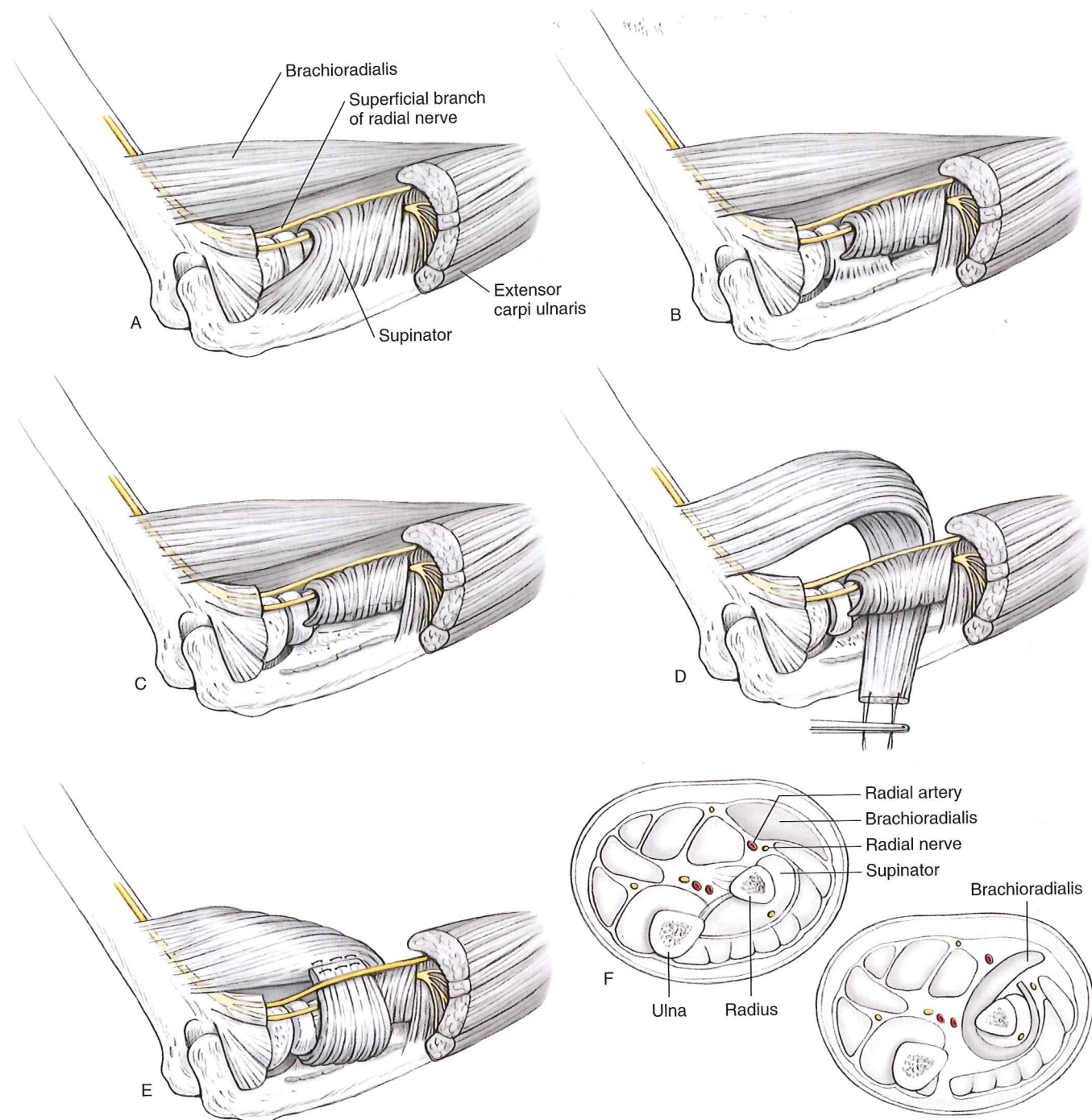


FIGURE 13-12

A: Posterior lateral approach (Kocher). Through a separate incision, the interval between the anconeus and extensor carpi ulnaris is developed. **B:** The supinator is sharply elevated off of the ulna exposing the radioulnar synostosis. **C:** The synostosis is removed and if necessary the interosseous ligament-membrane is excised. **D:** A separate anterior incision runs just ulnar to the brachioradialis muscle. The tendon is divided distally, the superficial branch of the radial nerve is separated from the under belly of the muscle, and the vascular bundles entering the muscle in the proximal forearm are preserved. The muscle is passed through the interosseous space created by the resection. **E:** The tail of the muscle is brought deep to the radial nerve and sutured to the proximal muscle belly. **F:** Cross-section of the forearm. Note the muscle passes radial to the radial artery in the mid forearm, distal to the biceps tendon and deep to the superficial branch of the radial nerve. (From Fernandez DL, Joneschild E. "Wrap around" pedicled muscle flaps for the treatment of recurrent forearm synostosis. *Tech Hand Up Extrem Surg.* 2004;8(2):102-109. With permission.)

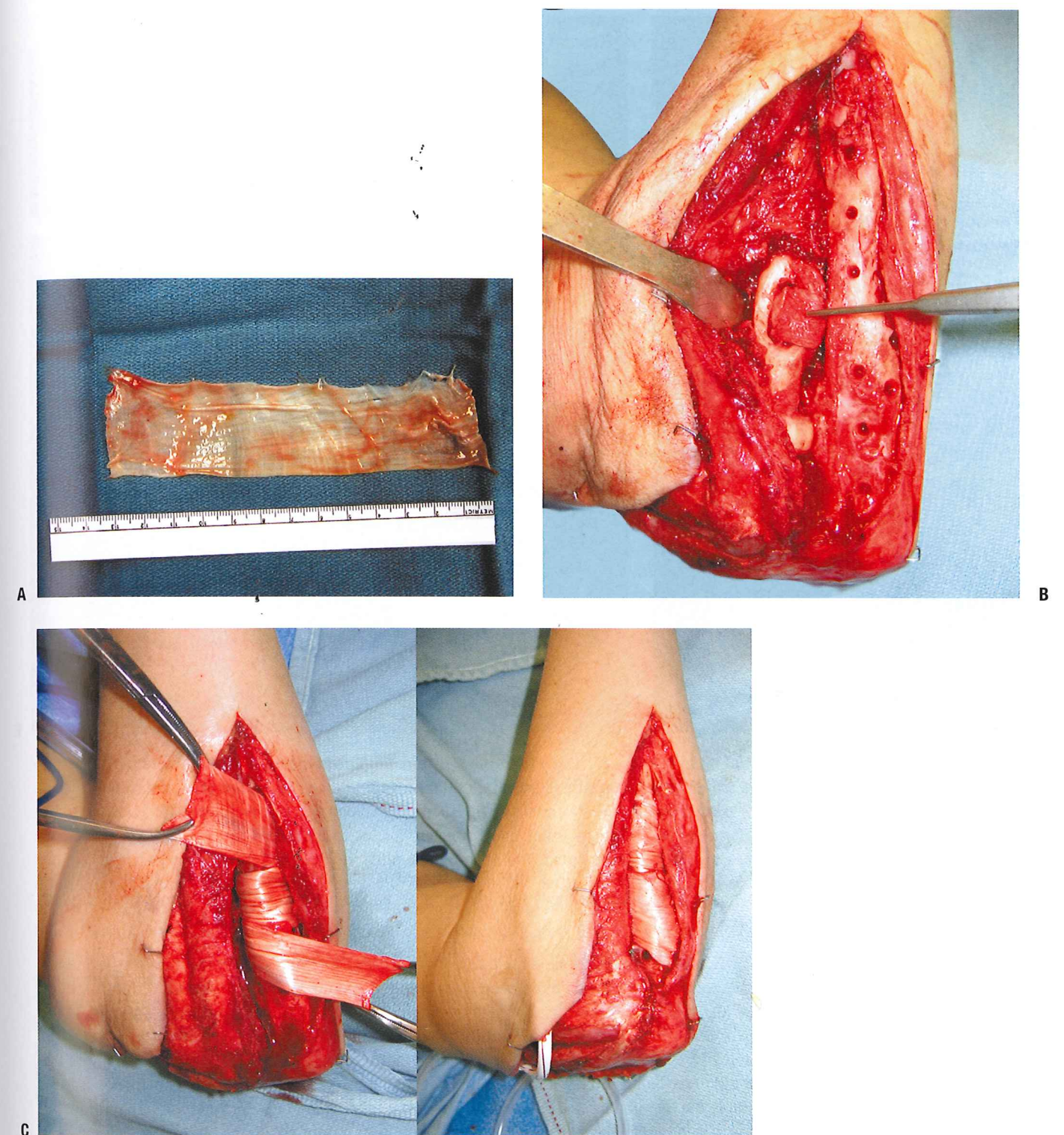


FIGURE 13-13

A: This 4 × 14 cm tensor fascia lata allograft will be used as an interposition material. **B:** This is the forearm of the patient shown in Figure 13-7. After synostosis resection, the rough surfaces of the radius and the ulna are prone to reformation of the synostosis. **C:** The tensor fascia lata allograft is wrapped around the ulna and secured with stout absorbable sutures. (Continued)

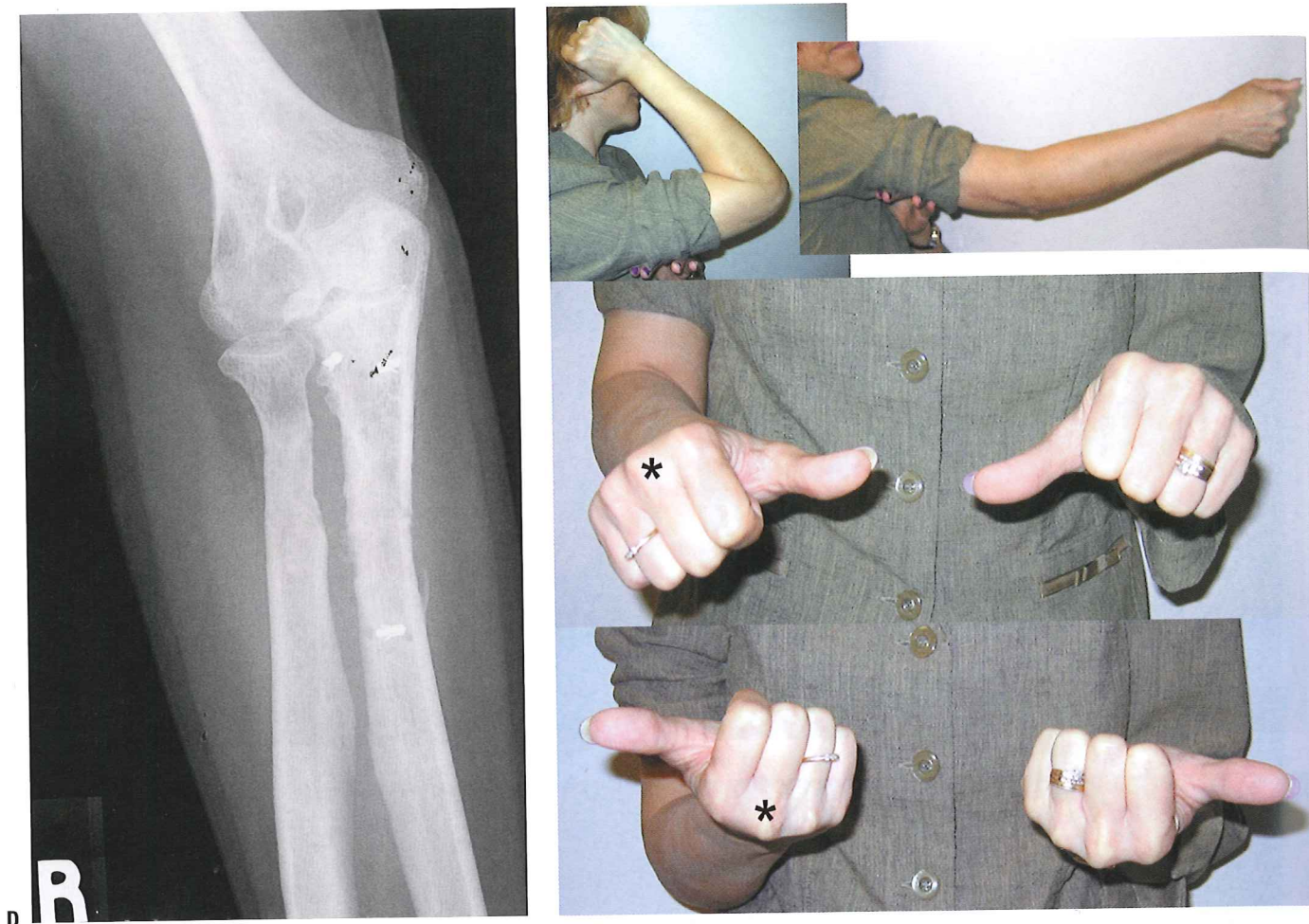

FIGURE 13-13

Continued **D:** Radiographs of the elbow 6 months postoperatively. **E:** Range of motion 6 months postoperatively.

around the proximal aspect of one of the forearm bones. The goals of this type of fascial interposition are twofold: to provide painless forearm rotation and to act as a barrier to future bridging heterotopic bone.

Closure After heterotopic bone excision from an elbow, medial or lateral instability frequently arises. If the collateral ligaments have been excised, they should be reconstructed. Allograft tendon provides an alternative to harvesting autogenous palmaris longus or plantaris for these patients. Using either form of collagen, a tendon reconstruction can be performed with a combination of suture anchors and bone tunnels. Care should be given to reconstructing the anterior band of the medial collateral ligament and the ulnar band of the lateral collateral ligament, as these ligaments have been shown to be instrumental in the maintenance of elbow stability. If stability cannot be achieved with ligamentous reconstruction, a dynamic external fixator or dynamic traction fixator should be applied.

Closed suction drains anterior and posterior to the elbow joint are an integral part of minimizing postoperative swelling and hematoma formation. It is not necessary to place a drain in the site of a synostosis takedown, but it should be placed deep to the fascial layer. Before closing the deep soft tissues, a lidocaine or bupivacaine continuous infusion pump may be placed to help maximize postoperative pain control (in cases in which axillary catheters are not used). The catheter for a bupivacaine infusion pump should be placed in a soft tissue layer or location separate from that of the closed suction drains. Divisions in the intermuscular septi do not need to be sutured, but muscle attachments to the distal humerus or proximal ulna should be repaired. For origins and insertions of

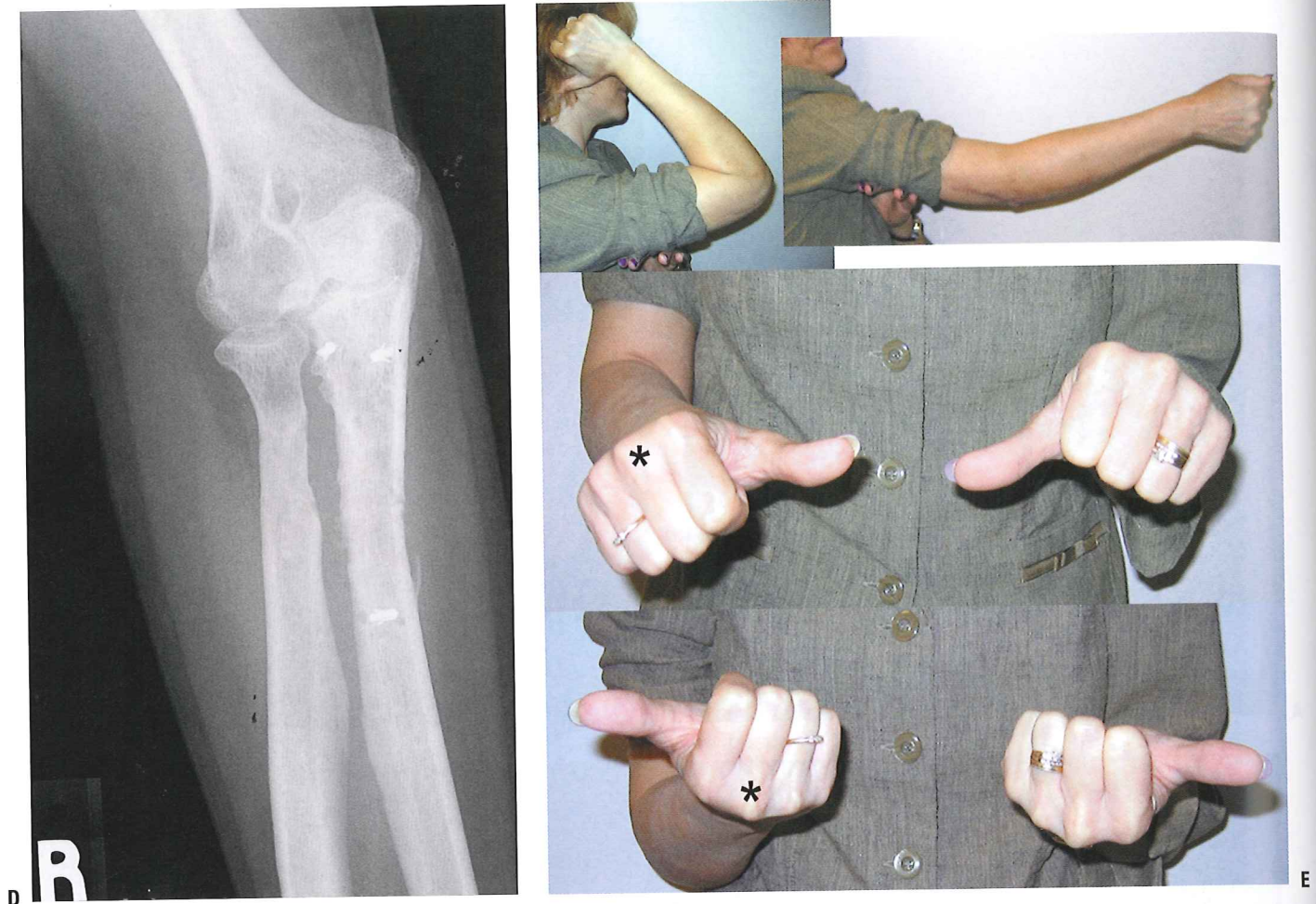

FIGURE 13-13

Continued **D:** Radiographs of the elbow 6 months postoperatively. **E:** Range of motion 6 months postoperatively.

around the proximal aspect of one of the forearm bones. The goals of this type of fascial interposition are twofold: to provide painless forearm rotation and to act as a barrier to future bridging heterotopic bone.

Closure After heterotopic bone excision from an elbow, medial or lateral instability frequently arises. If the collateral ligaments have been excised, they should be reconstructed. Allograft tendon provides an alternative to harvesting autogenous palmaris longus or plantaris for these patients. Using either form of collagen, a tendon reconstruction can be performed with a combination of suture anchors and bone tunnels. Care should be given to reconstructing the anterior band of the medial collateral ligament and the ulnar band of the lateral collateral ligament, as these ligaments have been shown to be instrumental in the maintenance of elbow stability. If stability cannot be achieved with ligamentous reconstruction, a dynamic external fixator or dynamic traction fixator should be applied.

Closed suction drains anterior and posterior to the elbow joint are an integral part of minimizing postoperative swelling and hematoma formation. It is not necessary to place a drain in the site of a synostosis takedown, but it should be placed deep to the fascial layer. Before closing the deep soft tissues, a lidocaine or bupivacaine continuous infusion pump may be placed to help maximize postoperative pain control (in cases in which axillary catheters are not used). The catheter for a bupivacaine infusion pump should be placed in a soft tissue layer or location separate from that of the closed suction drains. Divisions in the intermuscular septi do not need to be sutured, but muscle attachments to the distal humerus or proximal ulna should be repaired. For origins and insertions of

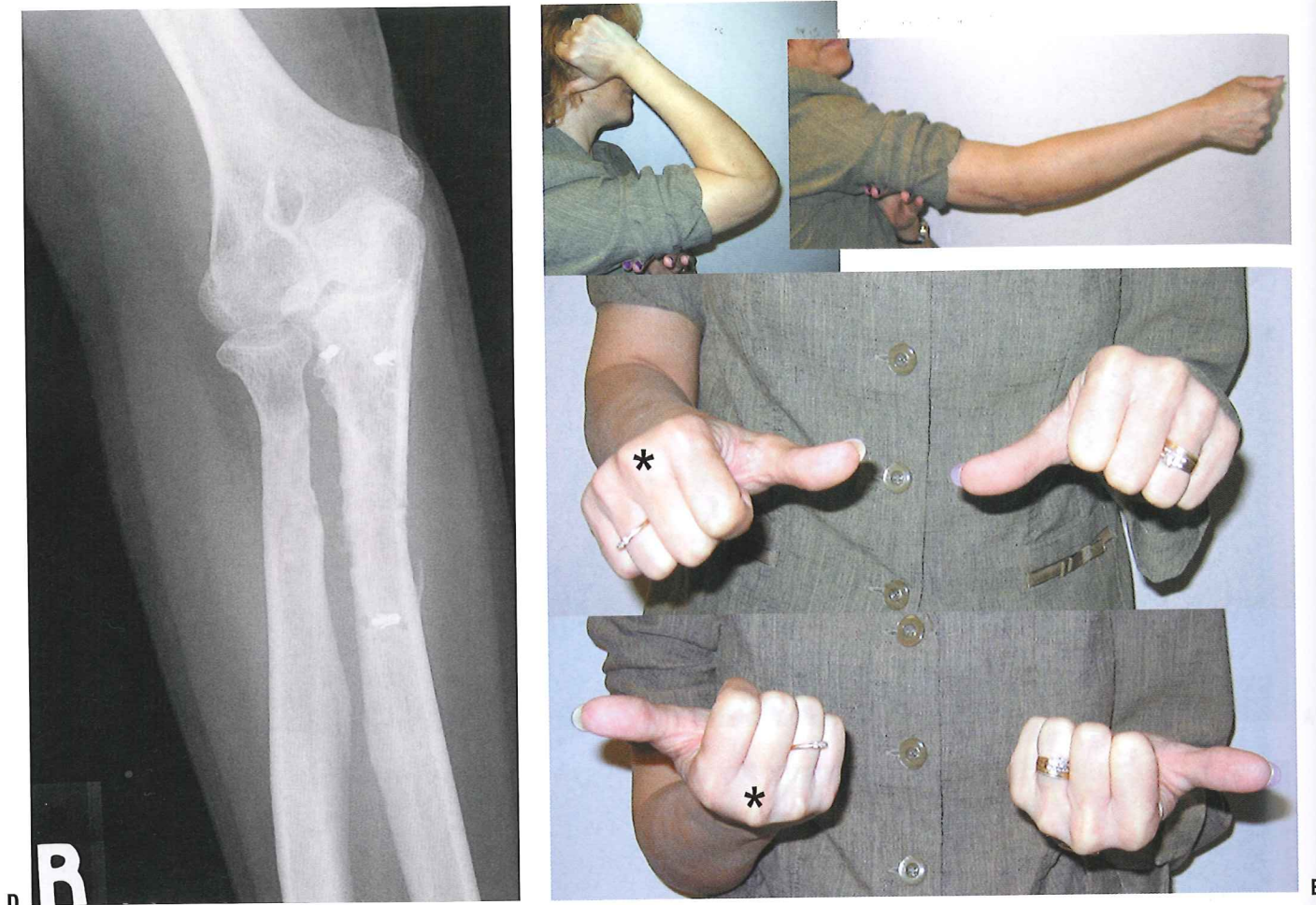

FIGURE 13-13

Continued **D:** Radiographs of the elbow 6 months postoperatively. **E:** Range of motion 6 months postoperatively.

around the proximal aspect of one of the forearm bones. The goals of this type of fascial interposition are twofold: to provide painless forearm rotation and to act as a barrier to future bridging heterotopic bone.

Closure After heterotopic bone excision from an elbow, medial or lateral instability frequently arises. If the collateral ligaments have been excised, they should be reconstructed. Allograft tendon provides an alternative to harvesting autogenous palmaris longus or plantaris for these patients. Using either form of collagen, a tendon reconstruction can be performed with a combination of suture anchors and bone tunnels. Care should be given to reconstructing the anterior band of the medial collateral ligament and the ulnar band of the lateral collateral ligament, as these ligaments have been shown to be instrumental in the maintenance of elbow stability. If stability cannot be achieved with ligamentous reconstruction, a dynamic external fixator or dynamic traction fixator should be applied.

Closed suction drains anterior and posterior to the elbow joint are an integral part of minimizing postoperative swelling and hematoma formation. It is not necessary to place a drain in the site of a synostosis takedown, but it should be placed deep to the fascial layer. Before closing the deep soft tissues, a lidocaine or bupivacaine continuous infusion pump may be placed to help maximize postoperative pain control (in cases in which axillary catheters are not used). The catheter for a bupivacaine infusion pump should be placed in a soft tissue layer or location separate from that of the closed suction drains. Divisions in the intermuscular septi do not need to be sutured, but muscle attachments to the distal humerus or proximal ulna should be repaired. For origins and insertions of

muscle about the medial and lateral elbow, suture anchors provide sufficient stability for the bony reattachment. If the medial, flexor-pronator muscle mass has been elevated, consideration can be made to submuscular transposition of the ulnar nerve. Otherwise, a simple subcutaneous transposition maintained with a small strip of flexor-pronator fascia frequently will suffice. The fascial layer may be repaired with absorbable suture in a running or interrupted fashion. Subcutaneous and skin closure follows. The skin closure should not be under tension, nor should it be so tight as to prevent egress of drainage when early motion is initiated.

POSTOPERATIVE MANAGEMENT

Surgical outcomes of heterotopic bone excision and interposition soft tissue flaps weigh heavily on the patient's postoperative rehabilitation. The affected upper extremity is immobilized in a soft dressing to allow immediate motion. An axillary block catheter placed by the anesthesia team can provide substantial pain relief in the immediate postoperative setting. When such a catheter cannot be placed, we have used continuous bupivacaine infusion pumps to supplement intravenous narcotic pain control.

With adequate analgesia, continuous passive motion of the elbow can be performed in flexion and extension. It is our preference to use a bedside continuous passive motion (CPM) machine for the elbow rather than the more mobile units that provide motion during ambulation. The bedside units tend to maintain a constant position, capitalizing on leverage to impart motion at the patient's elbow. We have not identified a reliable method for continuous passive forearm motion and instead rely on intermittent sessions wherein the extremity is removed from the CPM machine, the elbow flexed 90 degrees, and forearm motion addressed. Resting splints are worn while the patient sleeps at night. The position of the splint is dictated by the particular problems addressed with surgery. For patients with elbow flexion and extension problems, the limb is immobilized in maximum extension and supination. For those patients whose primary problem is forearm motion, the limb is immobilized with elbow flexed 90 degrees and the forearm in maximum supination. Patients are usually discharged on the fourth day postoperatively, and an aggressive home and outpatient therapy program is instituted.

Elbow and forearm specific exercises include active, active-assisted range of motion as well as gentle passive assisted range of motion. To minimize the "trick maneuver" of radiocarpal and intercarpal rotation to augment apparent pronation and supination, the wrist is secured in an immobilizer and a solid object such as a common household tool, a hammer, is grasped tightly in the hand. Doing this directs all pronation and supination efforts to the forearm. When not exercising, the patient should use a static progressive splint, especially at night. The splint is applied an hour before sleep, and the pain associated with initial application should have dissipated enough that sleep will not be interrupted. Dynamic rubber band or spring driven splints are never used. Splinting and exercises are rarely carried out past 6 months postoperatively, as there is usually no change in the range of motion past this date. Anecdotally, however, patients frequently report that even though their range of motion does not change after 6 months, their strength and ease of motion improves up to 2 years postoperatively.

Radiation treatment of the resected bed of heterotopic ossification or synostosis has been shown to be successful in preventing recurrence of ectopic bone. However, no prospective randomized trial has shown this modality to be better than resection alone. As this procedure comes with some inherent risk of wound breakdown, neuritis, and lymphedema, and a remote risk of sarcoma, it should be discussed with the patient preoperatively. We limit radiation therapy to a single dose of 700 cGy within 36 hours of surgery and only in those patients in whom there was ankylosis of the proximal radioulnar joint. All patients are given ketorolac 30 mg IV daily for the 4 days; beyond that, nonsteroidal anti-inflammatory medicines are not used.

COMPLICATIONS

While the release of a stiff or ankylosed elbow can provide dramatic improvement in a patient's upper extremity function, the procedure is not without its complications. It is a high-risk operation which requires strong appreciation for the anatomy of the elbow and traversing neurovascular structures. Nerve injury from retraction or surgical dissection is possible and can be minimized with frequent assessment of nerve location as well as limiting the time and rigorousness of retraction on a

nerve. Loss of fixation of the interposition material can be avoided by careful suture fixation into muscle as well as fascia.

Certainly, the most frequent complication of this procedure is recurrence of the heterotopic bone. In many cases new calcifications arise on postoperative radiographs well into the rehabilitation period. If the physical examination demonstrates no signs of motion loss, these ectopic calcifications are clinically insignificant and don't require routine followup. Some motion loss from the gains made intraoperatively can be expected. But a majority of patients who actively participate in their daily motion exercises will maintain a functional arc of motion and achieve an optimal outcome.

RECOMMENDED READING

- Alonso-Llames M. Bilateral tricipital approach to the elbow. Its application in the osteosynthesis of supracondylar fractures of the humerus in children. *Acta Orthop Scand.* 1972;43(6):479-490.
- Bell SN, Bengler D. Management of radioulnar synostosis with mobilization, anconeus interposition, and a forearm rotation assist splint. *J Shoulder Elbow Surg.* 1999;8(6):621-624.
- Cohen MS, Hastings H II. Post-traumatic contracture of the elbow. Operative release using a lateral collateral ligament sparing approach. *J Bone Joint Surg Br.* 1998;80(5):805-812.
- Dowdy PA, Bain GI, King GJ, et al. The midline posterior elbow incision. An anatomical appraisal. *J Bone Joint Surg Br.* 1995;77(5):696-699.
- Failla JM, Amadio PC, Morrey BF. Post-traumatic proximal radio-ulnar synostosis. Results of surgical treatment. *J Bone Joint Surg Am.* 1989;71(8):1208-1213.
- Fernandez DL, Joneschild E. "Wrap around" pedicled muscle flaps for the treatment of recurrent forearm synostosis. *Tech Hand Upper Extremity Surg.* 2004;8:102-109.
- Garland DE. A clinical perspective on common forms of acquired heterotopic ossification. *Clin Orthop Relat Res.* 1991(263):13-29.
- Hastings H II, Graham TJ. The classification and treatment of heterotopic ossification about the elbow and forearm. *Hand Clin.* 1994;10(3):417-437.
- Hurvitz EA, Mandac BR, Davidoff G, et al. Risk factors for heterotopic ossification in children and adolescents with severe traumatic brain injury. *Arch Phys Med Rehabil.* 1992;73(5):459-462.
- Jones NF, Esmail A, Shin EK. Treatment of radioulnar synostosis by radical excision and interposition of a radial forearm adipofascial flap. *J Hand Surg Am.* 2004;29(6):1143-1147.
- Jupiter JB, Ring D. Operative treatment of post-traumatic proximal radioulnar synostosis. *J Bone Joint Surg Am.* 1998;80(2):248-257.
- Kamineni S, Maritz NG, Morrey BF. Proximal radial resection for posttraumatic radioulnar synostosis: a new technique to improve forearm rotation. *J Bone Joint Surg Am.* 2002;84-A(5):745-751.
- McAuliffe JA, Wolfson AH. Early excision of heterotopic ossification about the elbow followed by radiation therapy. *J Bone Joint Surg Am.* 1997;79(5):749-755.
- Moritomo H, Tada K, Yoshida T. Early, wide excision of heterotopic ossification in the medial elbow. *J Shoulder Elbow Surg.* 2001;10(2):164-168.
- Morrey BF. Surgical treatment of extraarticular elbow contracture. *Clin Orthop Relat Res.* 2000(370):57-64.
- Morrey BF, Askew LJ, Chao EY. A biomechanical study of normal functional elbow motion. *J Bone Joint Surg Am.* 1981;63(6):872-877.
- Patterson SD, Bain GI, Mehta JA. Surgical approaches to the elbow. *Clin Orthop Relat Res.* 2000(370):19-33.
- Ring D, Jupiter JB. Operative release of complete ankylosis of the elbow due to heterotopic bone in patients without severe injury of the central nervous system. *J Bone Joint Surg Am.* 2003;85-A(5):849-857.
- Schmidt CC, Kohut GN, Greenberg JA, et al. The anconeus muscle flap: its anatomy and clinical application. *J Hand Surg Am.* 1999;24(2):359-369.
- Viola RW, Hanel DP. Early "simple" release of posttraumatic elbow contracture associated with heterotopic ossification. *J Hand Surg Am.* 1999;24(2):370-380.
- Viola RW, Hastings H, 2nd. Treatment of ectopic ossification about the elbow. *Clin Orthop Relat Res.* 2000(370):65-86.