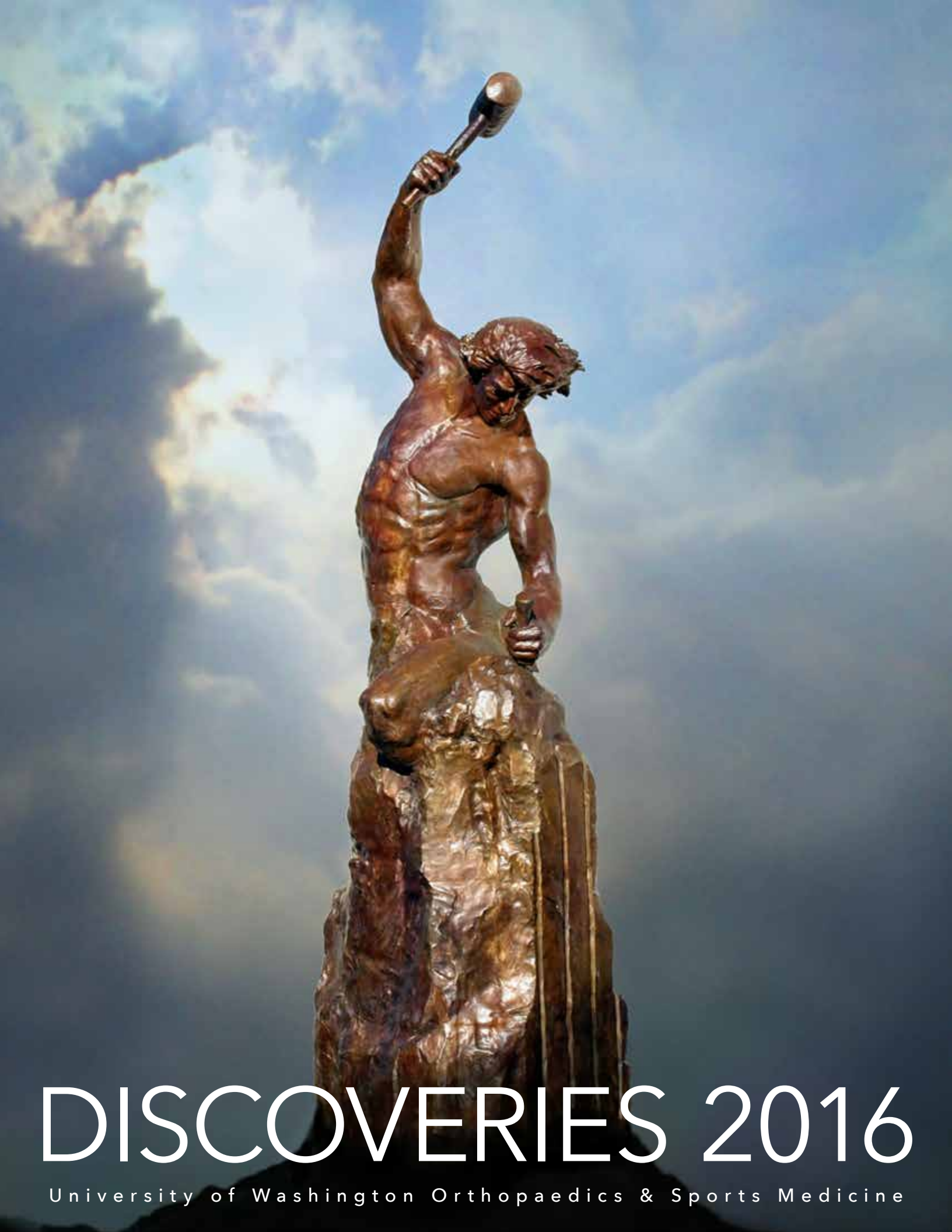


DISCOVERIES 2016

University of Washington Orthopaedics & Sports Medicine



University of Washington
Department of Orthopaedics
and Sports Medicine
Discoveries 2016

UW Medicine
SCHOOL OF MEDICINE

Department of Orthopaedics and Sports Medicine
University of Washington
Seattle, WA 98195

EDITOR-IN-CHIEF:

Howard A. Chansky, MD
chansky@uw.edu

ASSISTANT EDITORS:

Christopher H. Allan, MD
callan@uw.edu

Stephen A. Kennedy, MD
sajk@uw.edu

Adam A. Sassoon, MD, MS
sassoon@uw.edu

MANAGING EDITOR:

Fred Westerberg
fwesterb@uw.edu

Front Cover Illustration: "Self Made Man" sculpture by Bobbie Carlyle
www.bobbiecarlylesculpture.com

A pdf of this publication is available at our website:
www.orthop.washington.edu.

Permission Requests: All inquiries should be directed to the Managing Editor,
University of Washington, Department of Orthopaedics and Sports Medicine,
1959 NE Pacific Street, Box 356500, Seattle, WA 98195-6500, or at the email
address above.

Contents

1

Foreword

2

From The Assistant Editors: The Times They Are A Changin'

3

2016 Departmental Seed Grant Program

4

In Memorium: D. Kay Clawson, MD

6

In Memorium: David M. Chaplin, MD, FRCS

7

2016 Distinguished Alumnus, Franklin G. Alvine, MD

8

New Faculty

13

Department of Orthopaedics and Sports Medicine Faculty

19

Visiting Lecturers

Basic Science

- Progenitor Cells In Adult Human Digits **24** Cristi Stoick-Cooper, PhD, Brent Fall, BS, Andy Zhou, BS, Ursula K. Holder, BS, Colin J. Teteak, BS, Ashley A. Jaeger, BS, Timothy A. Petrie, PhD, Randall T. Moon, PhD, and Christopher H. Allan, MD
- Localization Of Type IIA Collagen In Annulus Fibrosus Of Adult Intervertebral Disc **27** Jiann-Jiu Wu, PhD, Audrey McAlinden, PhD, David R. Eyre, PhD, and Russell J. Fernandes, MSc, PhD
- Developmental Modifications In Type I Collagen Highlight Tissue-Defining Variances Between Ligament And Tendon **29** David M. Hudson, PhD, Jyoti Rai, MS, Marilyn Archer, BS, MaryAnn Weis, BS, Jiann-Jiu Wu, PhD, and David R. Eyre, PhD
- FishBone 2015: Advancing The Use Of Fish For Skeletal Research -- A Meeting Report **31** Ronald Y. Kwon, PhD and Matthew P. Harris, PhD
- Skeletal Defects In Mice With Mesenchyme-Specific Deletion Of The Entire ESET Histone Methyltransferase Protein **36** Liu Yang, PhD, Albert O. Gee, MD, John W. McCornack, BS, and Howard A. Chansky, MD

Clinical Science

- Prospective Comparison Of Patient-Reported Evaluation And Objective Measurement Of Shoulder Function **39** Jason E. Hsu, MD, Anna Tang, BS, and Frederick A. Matsen III, MD
- Single Stage Revision For Failed Shoulder Arthroplasty With Positive Cultures For Propionibacterium **41** Jason E. Hsu, MD, Jacob D. Gorbaty, BA, Ian J. Whitney, MD, and Frederick A. Matsen III, MD
- Clinical Prediction Of Pyogenic Flexor Tenosynovitis From Other Infections Of The Finger – Kanavel’s Cardinal Signs **43** Colin D. Kennedy, MD, Alexander S. Lauder, MD, Jonathan R. Pribaz, MD, and Stephen A. Kennedy, MD
- Impaction Autografting: Bone-Preserving, Secure Fixation Of A Standard Humeral Component Without Ingrowth Or Cement **48** Robert M. Lucas, MD, Jason E. Hsu, MD, Albert O. Gee, MD, Moni Blazej Neradilek, MS, and Frederick A. Matsen III, MD
- Treatment Of Irreparable Cuff Tears By Smoothing The Humeral Side Of The Humeroscapular Motion Interface: Patient-Reported Outcomes For 151 Shoulders With An Average Of 7.5 Year Followup **50** Jason E. Hsu, MD, Jacob D. Gorbaty, BA, Robert M. Lucas, MD, Stacy M. Russ, BA, and Frederick A. Matsen III, MD
- More Bang For Your Bundle? Oxinium Femurs On All-Polyethylene Tibial Components: Early Results And Hospital Cost Savings **53** Ryan D. Stancil, MD, Nathan W. Summers, PA-C, Navin D. Fernando, MD, Howard A. Chansky, MD, and Adam A. Sassoon, MD, MS
- Prophylactic Use Of Antibiotic Impregnated Calcium Sulfate Beads In Revision Hip And Knee Arthroplasty Procedures At High Risk For Prosthetic Joint Infection **56** Ryan D. Stancil, MD, Nathan W. Summers, PA-C, Navin D. Fernando, MD, Howard A. Chansky, MD, and Adam A. Sassoon, MD, MS

Service And Community Outreach

- Zhengzhou Orthopaedic Hospital Visit **60** Carlo Bellabarba, MDCM
- Bangladesh Spine Society Trip **61** Theodore A. Wagner, MD and Calvin Schlepp, MD
- Lessons From Complex Scoliosis Surgery In Sri Lanka **63** Vijay Yanamadala, MD and Rajiv Sethi, MD
- Orthopaedics In Bhutan **65** Samuel R. Baker, MD
- Overseas Experiences in Nicaragua **67** Gregory A. Schmale, MD
- UW Medicine And Intercollegiate Athletics: Partnering To Help Husky Athletes Compete At The Highest Level **69** Christopher Y. Kweon, MD and Albert O. Gee, MD

71

Harborview Medical Center Orthopaedics

73

Seattle Children's Hospital Orthopaedics

77

University of Washington Medical Center and Northwest Hospital Orthopaedics

79

Northwest Hospital Orthopaedics

80

VA Puget Sound Orthopaedics

82

Graduating Residents

84

Incoming Residents

86

ACEs and Fellows

88

Research Grants

90

Department Publications 2015-2016

97

Alumni

100

Endowments

102

Index

Foreword

This 2016 issue of Discoveries is filled with examples of the scientific and clinical talent in the Department of Orthopaedics and Sports Medicine. To best present the work of these talented faculty and alumni, for the first time we have employed the services of a group of Assistant Editors to bring more energy and focus to this publication. Drs. Chris Allan, Steve Kennedy and Adam Sassoon have ensured that this is what I believe to be our finest edition yet of Discoveries. Of course they were guided by the multitasking Fred Westerberg, a Program Operations Specialist in our Department who for many years has been the Managing Editor of the journal.

Another year brings another plethora of acronyms reflecting the great societal and economic pressures to change the practice of medicine. We have the JCHO, MACRA and CHIP, ACAs, ACNs, ICD-10, CJR, APMs and the list goes on and on, and on some more. While all of us are learning about the programs that these acronyms represent, what we really want to focus on are TKAs, ACLs, ACDFs, SCFEs, IMNs and all of the other procedures, techniques and diagnoses that make our jobs so rewarding and make orthopaedic patients as a group, perhaps the most grateful of all patients. As the Department and UW Medicine work feverishly to meet the imperatives and demands of these new government and insurance mandates, we continue to advance the science of orthopaedic surgery, deliver the best care for patients



Howard Chansky, MD (center) with two of our residents, Todd Blumberg, MD (left), who is graduating this year, and Calvin Schlepp, MD (right).

throughout the WWAMI region, and educate the most talented residents in the nation. This annual publication gives us an opportunity to dispense with the bureaucratic alphabet soup and focus on the work that we love. In addition to site updates by our hospital Chiefs Albert Gee (VA), Carlo Bellabarba (HMC) and Suzanne Yandow (SCH), in this issue of Discoveries you can read reflections on the lives of those in our orthopaedic family who have passed away in the past year, descriptions of some of our endeavors to contribute to global health care and of course a sampling of the clinical and scientific research that is the passion

of our incredibly talented faculty.

Please enjoy our 2016 edition of Discoveries and feel free to contact Fred Westerberg or myself with comments, reminiscences or suggestions for future issues.

Howard A. Chansky, MD
Professor and Chair

From The Assistant Editors: The Times They Are A Changin’

Changes in nature occur constantly. They provide opportunities for growth, development, and specialization. They range from events occurring on a molecular level expanding to those occurring over millions of years as organisms and the universe around them evolve. Changes may also represent overcoming difficulties. They are sometimes accompanied by an initial decrease in productivity and efficiency, before a change can demonstrate its positive impact. We see this in orthopaedic surgery surrounding new surgical procedures and commonly refer to it as “the learning curve.” It is during this period that the surgeon has the highest chance of making mistakes, incurring complications, moving slower and ultimately giving up on a potentially groundbreaking discovery. It is during periods where we challenge ourselves with change that we have the potential to discover the most about our art and ourselves.

In an ongoing pursuit of excellence, this past year has been one of substantial change within our department and represents an important chapter in its history. The editors tried to reflect on these changes in our edition of “Discoveries” this year. Much like the sculpture on the cover of this journal, our department stands chiseling a new image out of a solid, granite-like, core of fundamental principles that define our dedication to patient care, resident education, and research. This edition of Discoveries represents our emergence from the chrysalis of our own “learning curve” our eyes and hearts set on flight toward future horizons.

Embracing the theme of change, *Discoveries* has added a feature section to our layout this year, focusing on the UW Department of Orthopaedics and Sports Medicine’s efforts in community service. Along with our clinical work and highlighted research efforts, community service on local and global levels remains a central feature of our identity. Achievements in service from both residents and faculty are showcased along with narratives that demonstrate not only positive changes that occurred

externally as a direct result of their work, but also internal growth that occurred through a process that is often understatedly introspective.

The research showcased this year also reflects a response to significant changes occurring in healthcare. With bundled payments looming in the foreground, the cost efficiency of care delivery is emerging as an important topic in research. The article “More Bang for your Bundle” targets one aspect of cost efficiency in primary total knee arthroplasty in the form of using all-polyethylene tibial components over more traditionally used metal backed tibial base plates. Another topic increasing in popularity in Orthopaedic Surgery is the growing desire for unbiased patient reported outcomes. These are important not only for research but also in justifying the services we provide as well as the cost of those services. “Prospective Comparison of Patient-Reported Evaluation and Objective Measurement of Shoulder Function” identifies a new technological tool, which can be used to measure and correlate unbiased physical exam findings with patient reported outcomes.

The editorial staff is extremely excited about this edition of *Discoveries* and feels that it represents a litmus test of the healthy growth and changes that are occurring within the department in response to an uncompromising desire for excellence in care delivery, research, and service. We would like to give thanks for all the contributions that made this publication possible and hope that everyone enjoys reading *Discoveries 2016*.

Adam Sassoon, MD, MS
Stephen Kennedy, MD
Christopher Allan, MD

2016 Departmental Seed Grant Program

“An investment in knowledge pays the best interest.” - Benjamin Franklin

“Do not put all eggs in one basket.” - Warren Buffett

2016 Funded Applications:

1. Christopher Allan, MD, Ronald Kwon, PhD: Xenograft models of epimorphic regeneration
2. Steven Bain, PhD, Reza Firoozabadi, MD: Prevention of heterotopic ossification
3. Edith Gardiner, PhD, Lisa Taitzman, MD: β 2 adrenergic receptor antagonism and bone fracture healing in the mature skeleton
4. Albert Gee, MD: Epigenetic regulation of tendon healing
5. Albert Gee, MD: Pioneering the use of gaming technology to document and assess musculoskeletal function
6. Jason Hsu, MD: Identifying bacterial genetic virulence factors and patient characteristics associated with periprosthetic shoulder infections and propionibacterium
7. Stephen Kennedy, MD: Sleep symptom effects in patients undergoing carpal tunnel release.
8. Conor Kleweno, MD, Bruce Sangeorzan, MD: Patient reported outcome measures in pelvis and acetabular fracture patients using the PROMIS physical function test
9. Adam Sassoon, MD: The effects of total hip arthroplasty on sleep patterns and correlation of these effects with other outcome measures
10. Sundar Srinivasan, PhD, Reza Firoozabadi, MD, Steven Bain, PhD: Gut microbiome and fracture healing
11. Scott Telfer, PhD: Instrumented footwear for the measurement of plantar tissue material properties

Successful research in our field, as in all others, is increasingly reliant upon multi-disciplinary efforts.

This is equally true whether studying the molecular mechanisms underlying osteoarthritis or the cost-effectiveness of an innovative surgical solution to a previously intractable pathology. Multi-disciplinary science, by definition, relies upon collaboration by investigators of varied backgrounds. In this period of historically low extramural funding rates, the conceptual basis of successful proposals must be buttressed by substantial preliminary data. However, without the financial freedom and incentive to initiate non-traditional, multi-disciplinary collaborations, established investigators primarily focus on established areas of research. As a result, the innovation and risk-taking that are the hallmark of collaborative scientific advances are systemically minimized.

Under the leadership of Dr. Chansky, we have initiated a Departmental Seed Grant Program to begin to address these barriers at the departmental level. The goals of the program are to enable nascent innovative multi-faculty collaborations within the department, and to provide collegial peer feedback at various stages to enhance the projects, to fund as many projects as possible. It is our hope that successfully

achieving these goals will then lead to new innovative extramurally funded projects.

Following the program announcement, we received 20 applications – well in excess of what was anticipated and confirming the support for this type of program. All applications were blinded and reviewed by fellow faculty using a modified NIH rating rubric. None of the reviewers, who were assigned proposals based on their general knowledge of the field of study and a minimization of conflict of interests, assessed more than 3 applications. From this effort we were able to identify and fund 11 applications that received consistently strong scores across reviewers. The breadth of topics that will be explored is diverse, and includes using gaming technology to assess musculoskeletal function, the role of the gut microbiome in fracture healing, and the effect of sleep symptoms upon patients undergoing carpal tunnel release.

We will hold the first Seed Grant Symposium in early 2017 as a forum to present and receive feedback on initial data, and it is our hope that Discoveries 2017 will bring the first reports from these new projects.

Ted S. Gross, Ph.D.
Vice Chair for Research

In Memorium: D. Kay Clawson, MD

August 8, 1927 - March 11, 2016

The world is a better place because of Dr. D. Kay Clawson and his recent death leaves a void that cannot be filled. As Dr. Oliver Sachs said in his memoir "Gratitude", "...there is no one like anyone else, ever. When people die, they cannot be replaced. They leave holes that cannot be filled. For it is the fate-the genetic and neural fate-of every human being to be a unique individual, to find his own paths, to live his own life, to die his own death. "

Dr. Clawson had a modest upbringing in Utah as the only child of "older parents." His father died when he was 14 and at 18 he joined the Navy as a hospital corpsman. Through a series of people recognizing his potential, he was accepted to and completed his undergraduate degree at the University of Utah, medical school at Harvard University, and Orthopaedic residency at Stanford University. Finishing residency in 1957, he was granted a fellowship by the National Foundation for Infantile Paralysis and studied with Professor H.J. Seddon, at the Royal National Orthopaedic Hospital, University of London.

Dr. Clawson came to the University of Washington in 1958 as an Assistant Professor of Surgery and Head of the Division of Orthopaedic Surgery. By 1965 he was a Professor and the founding Chairman of the Department of Orthopaedic Surgery, a position which he held until 1975. Dr. Clawson noted in his autobiography *My Journey, Genes or Environment* that he was intent on "...creating an environment where the education of the student was the most important function, then stimulating and pushing each student I had direct contact with to reach their full and often unrecognized

potential." While at the University of Washington, Dr. Clawson modified the McKenzie sliding screw and convinced the Richards Company, then a small company in Memphis, Tennessee, to produce and market the screw. In a publication in 1964 in the *Journal of Trauma*, he promulgated the use of the sliding screw as the treatment of choice for intertrochanteric fractures. This treatment played a major role in reducing mortality and morbidity after



hip fractures by allowing patients to get out of bed and bear weight on the injured limb on the first day after surgery. Dr. Clawson also played a role in introducing to the U.S. the closed Kuntscher nailing and reaming treatment of femoral shaft fractures. Experience with the "K nail" was published in the *Journal of Bone and Joint Surgery* in 1971 with co-authors Sigvard T. Hansen and Robert Smith and began our reputation as the "Seattle School of Trauma." Dr. Clawson also established the first medical school Division of Sports Medicine. Always interested in quality patient care and musculoskeletal education, he trained the first Orthopaedic Physician Assistant in the country, Mr. Ivory Larry and co-authored the *Manual of Acute Orthopaedic Therapeutics* with then resident Dr. Larry Iversen. This handbook was published in three editions in 1977, 1982, and 1987. He also initiated the Musculoskeletal Core Course at the University of Washington School of Medicine, taught with Dr. Cornelius Rosse, from the Department of Biological Structure, and Dr. Walter Stolov, from the Department of Rehabilitation Medicine. The textbooks *Introduction to the Musculoskeletal System* and *The Musculoskeletal System in Health and Disease* were written with Dr. Cornelius Rosse and were widely used across the country for many years as the standard textbooks for musculoskeletal education.

In 1975, Dr. Clawson left Seattle to become the Dean of the College of Medicine at University of Kentucky, a position he served in until 1983. From 1983-1994, Dr. Clawson was the Executive Vice Chancellor for the University of Kansas Medical Center. A big believer



(Above) D. Kay Clawson and (below) with our department's faculty and residents in 1975.



D. Kay Clawson, MD, Chairman, 1965-1975, with Sigvard T. Hansen, Jr., MD, Chairman, 1981-1985.

in networking and learning from everyone you meet, he noted that Senator Henry "Scoop" Jackson taught him that the art of compromise could get things accomplished. *"If you can get 50 % of what you want and the other person can get 50 % of what he wants, you have a win-win situation."* Dr. Clawson never let go of the academic perspective and continued to publish on educational issues, workforce issues, and diversity in medicine. In total he published 93 journal articles, 9 books, and 10 book chapters. After retiring from the University of Kansas, Dr. Clawson returned to the University of Kentucky College of Medicine as Emeritus Professor of Orthopedics and Special Advisor to the Dean.

In addition to his impressive academic appointments, Dr. Clawson was chosen the Best Resident Teacher at Stanford, and twice awarded the Outstanding Teacher Award at University of Washington. In 1967, while Department Chair at UW, he was chosen as a 1967 ABC travelling fellow. He was elected to membership in the American Orthopedic Association and was a founding member of the American Orthopaedic Society for Sports Medicine. He served as President of the Association of Bone and Joint Surgeons and the Association of Orthopedic Chairmen. Recognized

nationally for his vision of academic medicine as well as his leadership skill, Dr. Clawson served as Head of both the Council of Deans and the Executive Committee of the Association of American Medical Colleges. For his service on numerous other committees the AAMC awarded him 4 distinguished service citations. His contributions were also recognized by dedication of the D. Kay Clawson Pavilion at the University of Kentucky and the Clawson Orthopaedic Library at Harborview Medical Center.

In all aspects of his work Dr. Clawson advocated strongly for what he believed to be right. His parents emphasized respect for people from varying backgrounds. He demonstrated this influence both in his Orthopaedics career, in his academic administrative roles, and in volunteer roles after "retiring" in Kentucky. Almost until the day he died, Dr. Clawson was a staunch supporter particularly of women, African Americans, and pre-medical students from rural backgrounds, serving as a dedicated member of the University of Kentucky College of Medicine Admissions Committee, an advisor to students enrolled in the BS/MD program, and a mentor to faculty and administrative staff.

Dr. Clawson delighted in and often sang the praises of his devoted wife

of 68 years, Jan, his daughter Dr. Kim Clawson, son Dr. D.R. Clawson, and 5 grandchildren. As someone who also benefitted from his teaching, friendship, mentorship and 43 years of consistent emotional support, I will miss him greatly. We can all learn from the wisdom he shared in his autobiography: *"Look to the past only for the lessons we can learn. Live today for the sheer joy of being alive. Plan for the future to ensure that what should be, will be."*

Carol C. Teitz, MD
Professor
Associate Dean for Admissions
School of Medicine

In Memorium: David M. Chaplin, MD, FRCS

1939 - 2016



David Morley Chaplin was born in Wakefield, England on May 5, 1939 but grew up in Birmingham, England where he later graduated from the University of Birmingham Medical School. After completing his general and orthopaedic training at the Royal College of Surgeons, he received his F.R.C.S. in 1967. David moved permanently to Seattle in 1974. He became the Resident Director in the Department of Orthopaedics and Sports Medicine while continuing his research in tendon surgery and rheumatoid arthritis and attending at both Children's and Harborview Medical Centers.

In 1978 he left the UW Department of Orthopaedics and Sports Medicine and joined Drs. Donald Gunn, Pete Toomey, and myself at Swedish Hospital, where he remained until his retirement in 2008. David was the ultimate polite, charming competitor whether the game was squash, cribbage, or Sudoku. In his spare time he climbed Mt. Rainier and ran the Seattle and London Marathons. He cherished his family time above all else. He fathered a child in five successive decades. He and his wife Dawn established the "Wakefield Farm" in Conway, WA where together their life bloomed in a horticultural hotbed. David and his family hand-built their family home, which remained a gathering oasis for family, friends, and the Board Members of the Skagit Symphony.

Good-bye to a great friend, surgeon, and lifelong learner.

Ted Wagner, MD
Clinical Professor

Franklin G. Alvine, MD

2016 Distinguished Alumnus

University of Washington School of Medicine

Dr. Frank Alvine was born and raised in Sioux Falls, South Dakota. He graduated from high school in 1957 and entered the three-year pre-medical program at the University of South Dakota. Upon completion of the then two-year medical school he transferred to the University of Washington, receiving his MD in 1964. Following three years in the United States Navy he entered the orthopaedic program at the University of Washington, graduating at the end of 1972. After a few months in Richland, WA an opportunity arose in Sioux Falls and Frank began his practice in July. At that time, while total joints replacements of both hips and knees were working out quite well, there was little success with total ankles. Many were on the market but the failure rate was very high and the procedures declined.

In 1978 an in depth study of world literature revealed twenty-three different total ankle designs, each with varying results. Following these findings, DePuy created an ankle prototype with Dr. Alvine that was used in a patient for the first time in 1984. The FDA approved this prototype in 1994 and over the next ten years, nearly 600 surgeons were trained, primarily at the American Academy of Orthopaedic Surgery's teaching center in Chicago, to perform the implantation of Depuy's ankle.

During his time practicing in Sioux



Dr. Franklin Alvine during his residency.

Falls, Dr. Alvine was one of the many surgeons whose patients were plagued by a condition called "post-operative ulnar nerve palsy." Many institutions had lawsuits filed against them claiming the surgeon and/or anesthesiologist was at fault. Dr. Alvine led a prospective study of 6,300 patients that revealed the medical team was not to blame in these circumstances. This condition is no longer compensable.

Dr. Alvine held the position of Professor of the orthopaedic division

of General Surgery at the University of South Dakota from 1990 – 1994. Prior to that he was the Chief of Staff of Sioux Valley Hospital from 1986 – 1988. Dr. Alvine was elected to the South Dakota Hall of Fame in 2010.

Dr. Alvine and his wife Marilyn just celebrated 53 years of marriage and are proud of their three children and nine grandchildren. They expressed sadness for the recent loss of Dr. D. Kay Clawson.

Of historical interest, Dr. Alvine was Dr. Ted Wagner's Chief Resident and Dr. Alvine's son, Greg, completed his Spine Fellowship with Dr. Wagner. Later, Greg returned to Sioux Falls to join his father.

On a personal note, Dr. Alvine has kept himself very entertained by his family and his many hobbies. He has been an accomplished instrument pilot since 1976 and restores old cars and motorcycles. He is also the founder and owner of one of the largest amusement parks west of the Mississippi River. As a proud citizen of South Dakota, he is active in wildlife and land conservation and frequently spends time on that same land taking his dogs hunting and fishing.

In June, Dr. Alvine received the Distinguished Alumnus Award for his career accomplishments as a researcher, administrator, teacher, and surgeon.

New Faculty



David M. Hudson, PhD

Research Assistant Professor
University of Washington Medical Center
Research
dmhudson@uw.edu

David M. Hudson, PhD joined the faculty at the Department of Orthopaedics and Sports Medicine on October 15, 2015. As a Research Assistant Professor he investigates the pathobiology of collagen modifications in soft connective tissues such as tendon and ligament.

He has expertise in several scientific disciplines and has published peer-reviewed research in the fields of orthopaedics, matrix biology, iron metabolism, blood coagulation, and marine biology. Dr. Hudson has presented at the American Society for Matrix Biology, Matrix Biology Europe, the Osteogenesis Imperfecta Scientific Meeting, and the Orthopaedic Research Society.

Dr. Hudson studied Biochemistry and Molecular Biology in Canada. He received a BSc at Memorial University of Newfoundland, a MSc at Dalhousie University, and a PhD at the University of British Columbia.

After graduating with his PhD, he joined Dr. David Eyre's research program in our department as a Visiting Scientist in 2008. Here he applied his expertise in protein biochemistry to the study of the collagen post-translational modification chemistry using mass spectrometry. Dr. Hudson has remained an integral part of the Burgess Chair Research Program, having been promoted to Senior Fellow in 2011, to Acting Instructor in 2012, and to Research Assistant Professor in 2015.



Nicholas P. Iannuzzi, MD

Assistant Professor
VA Puget Sound Health Care System
General Orthopaedics
iannuzzi@uw.edu


Dr. Nicholas P. Iannuzzi joined our department as a faculty member in 2015. He was born in Winston-Salem, North Carolina, completed his Bachelor of Arts at Princeton University, and his medical degree at the University of North Carolina School of Medicine, where he received an International Medical Fellow Scholarship and was a member of Alpha Omega Alpha, the medical equivalent of Phi Beta Kappa.

He isn't a stranger to us to as he completed his internship and residency here at the University of Washington. After Seattle, he moved to Baltimore, Maryland where he completed a fellowship in hand surgery at the Curtis National Hand Center.

Dr. Iannuzzi has published articles on tibial shaft fractures, comminuted olecranon fractures, and arterial thrombosis of the hand in publications such as Foot Ankle International, the Journal of Orthopaedic Trauma, and the Journal of Hand Surgery.

Dr. Iannuzzi is an Assistant Professor in our department in General Orthopaedics as well as Hand and Upper Extremity based at the VA and our Bone and Joint Center.

New Faculty



Christopher Y. Kweon, MD

Assistant Professor
University of Washington Medical Center
Sports Medicine
ckweon@uw.edu

Christopher Kweon, MD joined the University of Washington Department of Orthopaedics and Sports Medicine in February 2016. Dr. Kweon is from Federal Way, Washington and went to the University of Washington for his undergraduate degree in Biochemistry. He also attended the UW for his medical degree. He completed his residency at Banner Good Samaritan/Mayo Clinic Scottsdale in Arizona. A fellowship in Sports Medicine and Shoulder Surgery at the University of Michigan followed before he returned to the Pacific Northwest. Prior to joining our department he work at Skagit Valley Hospital in Mount Vernon, Washington.

Dr. Kweon has won numerous awards in his career. He is the winner of the Jeannette Wilkins Award for Basic Science Research, presented at the Musculoskeletal Infection Society annual meeting in Marina Del Rey, California August 6, 2010. He won first place for the Basic Science Research Presentation at the Banner Orthopaedic Resident Research Symposium in Phoenix, Arizona on June 18, 2010. As well, in 2008, he won the Douglas T. Harryman award for orthopaedics (named after a former faculty member of our department).

Dr. Kweon has published original research on rotator cuff repairs, outcomes research, ligament reconstruction, as well arthroscopic treatment of impingement of the hip.

New Faculty



H. Claude Sagi, MD

Professor
Harborview Medical Center
Trauma
claudes@uw.edu

Henry Claude Sagi was born in William's Lake, British Columbia, Canada. He graduated from the University of British Columbia with a B.Sc. in Physics and Chemistry in 1990, and his medical degree in 1994. Afterwards, he completed his residency in Orthopedic Surgery at the University of Ottawa under Dr. James G. Jarvis, MD. He has completed two post-residency fellowships: Orthopedic Trauma at the Florida Orthopaedic Institute/University of South Florida and then Spine Surgery at Upstate Medical University in Syracuse, NY.

Dr. Sagi was hired for his first faculty position as Chief of the Division of Orthopaedic Surgery at UCSF-Fresno Medical Education Program from August 2001 to May 2003. In 2003 he returned to Tampa, FL where he served as the Fellowship and Research Director for the Orthopedic Trauma Service, Florida Orthopaedic Institute and Clinical Associate Professor with the University of South Florida Orthopedic Surgery residency program until July of 2015.

In September of 2015, he joined the Department of Orthopaedics and Sports Medicine at the University of Washington as a Professor based at Harborview Medical Center. Dr. Sagi has received many awards in his career. Pediatric Orthopaedic Society Best Scientific Paper was awarded in 1998. In 2001, he was honored with the Cervical Spine Research Society Best Fellow Paper. In 2008, AO North America presented him with the Howard Rosen Teaching Award. He won the Resident Teaching Award at the University of South Florida in 2011, 2012, 2013, 2014, and 2015. He has been a member of the American Academy of Orthopaedic Surgeons since 2004. He has been a member of the Orthopaedic Trauma Association since 2000 – where he served on both the Evidence Based Medicine Committee and the Education Committee. In addition, he is a member of the American College of Surgeons, Foundation for Orthopedic Trauma, and the Western Trauma Association. His teaching history is quite extensive. Dr. Sagi has given invited lectures nationally and internationally at meetings of the Orthopaedic Trauma Association, North American Spine Society, AO North America, American Academy of Orthopaedic Surgeons, International Trauma Symposium, and the Emille Letourne! Annual Pelvic and Acetabular Course, to name but a few. Dr. Sagi's clinical and research focus is on treating fractures of the pelvis and extremities – for which he has published extensively. Finally, Dr. Sagi organizes an annual medical mission to Haiti since the devastating earthquake of 2010.

New Faculty



Nicholas T. Spina, MD

Assistant Professor
University of Washington Medical Center
Spine
spina@uw.edu

In September 2015, Dr. Nicholas Spina joined the Department of Orthopaedics and Sports Medicine as an Assistant Professor. Dr. Spina specializes in spine and sees patients at the Bone and Joint Center at our Roosevelt location and operates on patients at the University of Washington Medical Center.

Dr. Spina attended Boston College for his undergraduate degree in Biological Sciences. He received his medical degree from the University of Pittsburgh, where he also completed his residency. Following this, he completed a spine fellowship at the University of Utah Medical Center.

Dr. Spina has published manuscripts on post-compressive neuritis and a novel classification for functional lumbar stenosis. In addition, he has presented research on cervical spinal stenosis and acute proximal junctional failure at the North American Spine Society and the Scoliosis Research Society.



Scott Telfer, EngD


Acting Assistant Professor
University of Washington Medical Center
Research
telfers@uw.edu

Scott Telfer, EngD is the Department's newest Acting Assistant Professor. In February 2016, he joined our department. He works with Dr. Peter Cavanagh on gait analysis, biomechanics, orthotics, kinematics, and biomedical engineering.

He was born in Irvine, United Kingdom and was educated at the University of Glasgow and the University of Strathclyde. From 2009 to 2013, he was a research fellow at the Institute for Applied Health at Glasgow Caledonian University. After, he joined the Computational, Robotics and Experimental Biomechanics Laboratory at the University of Washington as a Marie Curie International Research Fellow. In the same capacity he returned to Glasgow from 2014 to 2016. Afterwards, he joined the University of Washington Department of Orthopaedics and Sports Medicine.

Dr. Telfer has most recently published original peer-reviewed research on "Simplified Versus Geometrically Accurate Models Of Forefoot Anatomy To Predict Plantar Pressures: A Finite Element Study" in the Journal of Biomechanics. He also has published on finite element analysis in PLoS One and simple finite element models for use in the design of therapeutic footwear in the Journal of Biomechanics.

New Faculty



Liu Yang, PhD

Acting Associate Professor
University of Washington Medical Center
Research
lyang@uw.edu

Dr. Liu Yang was born in the city of Wuxue, Hubei Province, China. His undergraduate education was in Chemistry at Wuhan University in China. He completed his Masters in Medicinal Chemistry at the Shanghai Institute of Materia Medica, Chinese Academy of Sciences. He received his DSc from the Department of Natural Product Chemistry from the College of Chemical Science at Beijing University. Next, he graduated in 1996 with a PhD from the Department of Biochemistry and Molecular Biology from Indiana University School of Medicine. Soon after he joined the University of Washington as a Post-Doctoral Fellow in the Department of Medicine/Oncology. He was appointed to the Department of Orthopaedics and Sports Medicine as Research Assistant Professor. In 2005, he left the UW for the University of Arkansas for Medical Sciences as an Associate Professor. In 2007 he returned to the UW as Director of Molecular Orthopaedics Laboratory. In November 2015, he was named Acting Associate Professor of the University of Washington Department of Orthopaedics and Sports Medicine.

Dr. Yang has been honored with a number of prestigious awards in his career. In 1990, he was awarded the Advancement in Science and Technology Award from the Chinese Ministry of Education. And most recently the National Leukemia Research Association presented him with its Research Award.

Dr. Yang is an active journal article reviewer for numerous publications such as *Experimental Cell Research*, *Blood*, *International Journal of Cancer*, and the *Journal of Orthopaedic Research*. He has served as a member of National Institutes of Health grant review committees.

Dr. Yang has an extensive publication history. He has published original research on ESET histone methyltransferase, EWS-Fli1 fusion protein in Ewing's sarcoma cells, collagen gene transcription, in addition to other aspects of medical biological and chemical research.

Department of Orthopaedics and Sports Medicine Faculty



Howard A. Chansky, MD
Professor and Chair
VA Puget Sound Health Care System
University of Washington Medical Center
Northwest Hospital
Adult Reconstructive Surgery
chansky@uw.edu



Stephen K. Benirschke, MD
Professor
Harborview Medical Center
Foot and Ankle
beniskb@uw.edu



Christopher H. Allan, MD
Associate Professor
Harborview Medical Center
Hand and Wrist
callan@uw.edu



Sarah D. Beshlian, MD
Clinical Associate Professor
Northwest Hospital
Hand and Wrist
sarah.beshlian@nwsea.org



Steven D. Bain, PhD
Research Associate Professor
Harborview Medical Center
Research
sdbain@uw.edu



Maryse Bouchard, MD
Assistant Professor
Seattle Children's Hospital
Pediatric Orthopaedics
maryse.bouchard@seattlechildrens.org



David P. Barei, MD
Professor
Harborview Medical Center
Trauma
barei@uw.edu



Michael E. Brage, MD
Associate Professor
Harborview Medical Center
Foot and Ankle
bragem@uw.edu



Daphne M. Beingessner, MD
Associate Professor
Harborview Medical Center
Trauma
daphneb@uw.edu



Richard J. Bransford, MD
Associate Professor
Harborview Medical Center
Spine
rbransfo@uw.edu



Carlo Bellabarba, MDCM
Professor
Harborview Medical Center
Spine and Trauma
cbella@uw.edu



Peter R. Cavanagh, PhD, DSc
Professor
University of Washington Medical Center
Research
cavanagh@uw.edu

Department of Orthopaedics and Sports Medicine Faculty



Robert S. Clawson, MD
Clinical Associate Professor
Northwest Hospital
Fractures & Trauma
robert.clawson@nwhsea.org



Russell J. Fernandes, MSc, PhD
Research Associate Professor
University of Washington Medical Center
Research
rjf@uw.edu



Ernest U. Conrad III, MD
Professor
Seattle Children's Hospital
University of Washington Medical Center
Orthopaedic Oncology
chappie.conrad@seattlechildrens.org



Navin D. Fernando, MD
Assistant Professor
Northwest Hospital
Hip and Knee
navinf@uw.edu



Mark C. Dales, MD
Clinical Associate Professor
Seattle Children's Hospital
Spine
mark.dales@seattlechildrens.org




Reza Firoozabadi, MD, MA
Assistant Professor
Harborview Medical Center
Trauma
rezaf2@uw.edu



Darin J. Davidson, MD, MHSc
Assistant Professor
University of Washington Medical Center
Orthopaedic Oncology
djavi@uw.edu



Edith M. Gardiner, PhD
Research Associate Professor
Harborview Medical Center
Research
edigar@uw.edu



Robert P. Dunbar, MD
Associate Professor
Harborview Medical Center
Trauma
dunbar@uw.edu



Albert O. Gee, MD
Assistant Professor
University of Washington Medical Center
VA Puget Sound Health Care System
Sports Medicine
ag112@uw.edu



David R. Eyre, PhD
Professor
University of Washington Medical Center
Research
deyre@uw.edu



Michael J. Goldberg, MD
Clinical Professor
Seattle Children's Hospital
Pediatric Orthopaedics
michael.goldberg@seattlechildrens.org

Department of Orthopaedics and Sports Medicine Faculty



John R. Green III, MD
Associate Professor
University of Washington Medical Center
Sports Medicine
jgreen3@uw.edu



Jerry I. Huang, MD
Associate Professor
University of Washington Medical Center
Hand and Wrist
jihuang@uw.edu



Ted S. Gross, PhD
Professor
Harborview Medical Center
Research
tgross@uw.edu



David M. Hudson, PhD
Research Assistant Professor
University of Washington Medical Center
Research
dmhudson@uw.edu



Douglas P. Hanel, MD
Professor
Harborview Medical Center
Hand and Wrist
dhanel@uw.edu



Nicholas P. Iannuzzi, MD
Assistant Professor
VA Puget Sound Health Care System
General Orthopaedics
iannuzzi@uw.edu



Sigvard T. Hansen, Jr., MD
Professor Emeritus
Harborview Medical Center
Foot and Ankle
hansetmd@uw.edu



Stephen A. Kennedy, MD
Assistant Professor
University of Washington Medical Center
Northwest Hospital
Hand and Wrist
sajk@uw.edu



M. Bradford Henley, MD
Professor
Harborview Medical Center
Trauma
bhenley@uw.edu



Conor P. Kleweno, MD
Assistant Professor
Harborview Medical Center
Trauma
ckleweno@uw.edu



Jason E. Hsu, MD
Assistant Professor
University of Washington Medical Center
Shoulder and Elbow
jehsu@uw.edu



Walter F. Kregel III, MD
Clinical Associate Professor
Seattle Children's Hospital
Spine
wally.kregel@seattlechildrens.org

Department of Orthopaedics and Sports Medicine Faculty



Christopher Y. Kweon, MD
Assistant Professor
University of Washington Medical Center
Sports Medicine
ckweon@uw.edu



Vincent S. Mosca, MD
Professor
Seattle Children's Hospital
Pediatric Orthopaedics
vincent.mosca@seattlechildrens.org



Ronald Y. Kwon, PhD
Assistant Professor
Harborview Medical Center
Research
ronkwon@uw.edu



Carol A. Mowery, MD
Clinical Associate Professor
Seattle Children's Hospital
Pediatric Orthopaedics
carol.mowery@seattlechildrens.org



Seth S. Leopold, MD
Professor
University of Washington Medical Center
Northwest Hospital
Adult Reconstructive Surgery
leopold@uw.edu



Sean E. Nork, MD
Professor
Harborview Medical Center
Trauma
nork@uw.edu



Antoinette Lindberg, MD
Acting Assistant Professor
Seattle Children's Hospital
Orthopaedic Oncology
antoinette.lindberg@seattlechildrens.org



H. Claude Sagi, MD
Professor
Harborview Medical Center
Trauma
claudes@uw.edu



Paul A. Manner, MD
Professor
University of Washington Medical Center
Northwest Hospital
Adult Reconstructive Surgery
pmanner@uw.edu



Bruce J. Sangeorzan, MD
Professor
Harborview Medical Center
Foot and Ankle
bsangeor@uw.edu



Frederick A. Matsen III, MD
Professor
University of Washington Medical Center
Shoulder and Elbow
matsen@uw.edu



Adam A. Sassoon, MD, MS
Assistant Professor
University of Washington Medical Center
Northwest Hospital
Hip and Knee
sassoon@uw.edu

Department of Orthopaedics and Sports Medicine Faculty



Gregory A. Schmale, MD
Associate Professor
Seattle Children's Hospital
Pediatric Orthopaedics
gregory.schmale@seattlechildrens.org



Carol C. Teitz, MD
Professor
University of Washington Medical Center
Sports Medicine
teitz@uw.edu



Douglas G. Smith, MD
Professor
Harborview Medical Center
Foot and Ankle
dgsmith@uw.edu



Scott Telfer, EngD
Acting Assistant Professor
University of Washington Medical Center
Research
telfers@uw.edu



Nicholas T. Spina, MD
Assistant Professor
University of Washington Medical Center
Spine
spina@uw.edu



Theodore A. Wagner, MD
Clinical Professor
University of Washington Medical Center
Spine
wagner@uw.edu



Sundar Srinivasan, PhD
Research Associate Professor
Harborview Medical Center
Research
sundars@uw.edu



Winston J. Warme, MD
Associate Professor
University of Washington Medical Center
Shoulder and Elbow
warmewj@uw.edu



Suzanne E. Steinman, MD
Clinical Assistant Professor
Seattle Children's Hospital
Pediatric Orthopaedics
suzanne.steinman@seattlechildrens.org



Klane K. White, MD, MSc
Associate Professor
Seattle Children's Hospital
Pediatric Orthopaedics
klane.white@seattlechildrens.org



Lisa A. Taitzman, MD, MPH
Associate Professor
Harborview Medical Center
Trauma
taitzman@uw.edu



Jiann-Jiu Wu, PhD
Research Professor
University of Washington Medical Center
Research
wujj@uw.edu

Department of Orthopaedics and Sports Medicine Faculty



Suzanne M. Yandow, MD
 Professor
 Seattle Children's Hospital
 Pediatric Orthopaedics
 suzanne.yandow@seattlechildrens.org



Liu Yang, PhD
 Acting Associate Professor
 University of Washington Medical Center
 Research
 lyang@uw.edu

Michael D. Taylor, PA

Senior Fellow
 Claire Watson, PhD

Acting Instructor
 Joshua B. Shatsky, MD
 Leah E. Worton, PhD

Residents

R5s:
 Todd Blumberg, MD
 Akash Gupta, MD
 Sean Haloman, MD
 Emily Harnden, MD
 Clifford Hou, MD
 Dayne Mickelson, MD
 Jessica Telleria, MD

R4s:
 Ahmad Bayomy, MD
 Christopher Domes, MD
 Kevin Hug, MD
 Alexander Lauder, MD
 Calvin Schlepp, MD
 Neil Tarabackar, MD
 Sara Shippee Wallace, MD

R3s:
 Kariline Bringe, MD
 Romie Gibly, MD, PhD
 David Ibrahim, MD
 Colin Kennedy, MD
 Lauren Meyer, MD
 Stuart Michnick, MD
 Adam Sangeorzan, MD
 Alan Swenson, MD

R2s:
 Zahab Ahsan, MD
 Matthew Baron, MD
 Kate Bellevue, MD
 Claudia Christman-Skieller, MD

Jonathan Kark, MD
 Erik Magnusson, MD
 Adam O'Brien, MD
 Mary Kate Thayer, MD

R1s:
 Prashoban Bremjit, MD
 Thomas Byrnes, MD
 Matthew Folchert, MD
 Boris Kovalenko, MD
 Eli Sayegh, MD
 Brett Schiffman, MD
 Cody Tipton, MD
 Anthony Yi, MD

Emeritus Faculty

Stanley J. Bigos, MD
 Professor Emeritus
 Roger V. Larson, MD
 Associate Professor Emeritus
 Lynn T. Staheli, MD
 Professor Emeritus

Joint Faculty

Anthony M. Avellino, MD
 Monique S. Burton, MD
 Randall M. Chesnut, MD
 Armagan Dagal, MD
 Jeffrey B. Friedrich, MD
 Kimberly Harmon, MD
 Mark A. Harrast, MD
 Stanley A. Herring, MD
 Virany H. Hillard, MD
 Thomas Jinguuji, MD
 John Lockhart, MD
 John W. O'Kane, Jr., MD
 John E. Olerud, MD
 Celeste Quitiquit, MD
 Trent L. Tredway, MD
 Nicholas B. Vedder, MD
 Fangyi Zhang, MD

Adjunct Faculty

Roger E. Bumgarner, PhD
 Jack W. Berryman, PhD
 Cora C. Breuner, MD
 Charles H. Chesnut III, MD
 Randal P. Ching, PhD
 Gregory C. Gardner, MD
 Daniel O. Graney, PhD
 Jason Ko, MD
 Grant E. O'Keefe, MD
 Susan M. Ott, MD
 Wendy H. Raskind, MD, PhD
 Michael L. Richardson, MD
 Miqin Zhang, PhD

Affiliate Faculty

William R. Ledoux II, PhD
 D. Michael Strong, PhD

Teaching Associate

Alexander L. Bertelsen, PA
 EChing V. Bertelsen, PA
 Carlos N. Caso, PA
 Lauren A. Colpo, PA
 Laura J. DesEnfants, PA
 Aaron J. Eusterbrock, PA
 Joseph L. Fiorito, DPM
 Peter C.A. Hall, PA
 Jennifer S. Hamilton, PA
 Douglas J. Ichikawa, DPM
 Connie U. Ly, PA
 Jason E. Maris, PA
 Katie L. Moore, ARNP
 Rockwell G. Moulton, DPM
 Janice M. Olivo, PA
 Nicole A. Patrick, PA
 Amanda L. Pedersen, PA
 Nathan W. Summers, PA

Visiting Lecturers

2016 LeCocq Lectureship

January 21-22, 2016

We were happy to host Dr. Graham J.W. King as our guest lecturer for the 2016 LeCocq Lectureship. On Thursday January 21st, he gave a presentation on “Radial Head Fractures: Current Concepts.” At the 52nd Annual John F. LeCocq Dinner that evening, he gave the featured lecture on “Working with Orthopaedic Industry: Experiences of a Surgeon Designer.” The following day he gave his final talk on “Management of Osteoporotic Distal Humeral Fractures.”

Dr. Graham J.W. King received his MD degree at the University of British Columbia. After completing a rotating internship at the University of Alberta he went to the University of Toronto to train in orthopaedic surgery. During a research year in Toronto he became interested in orthopaedic biomechanics and soft tissue healing. After qualifying as an orthopaedic surgeon in 1989 he completed a clinical fellowship in hand and wrist surgery and a Masters of Science degree at the University of Calgary. He then travelled to the Mayo Clinic to gain further clinical experience in wrist and elbow surgery



(Left to right) Graham J. W. King, MD, MSc, FRCSC, Daphne M. Beingessner, MD, and Howard A. Chansky, MD.

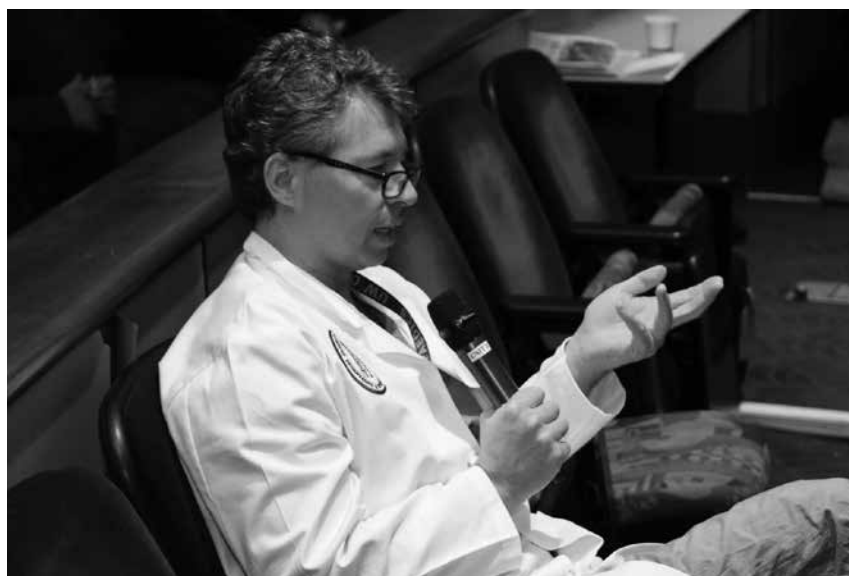and additional research experience in upper extremity bioengineering. In 1992 he joined the Department of Surgery at the University of Western Ontario. He established the Bioengineering Laboratory at the Hand and Upper Limb

Centre at St. Joseph's Health Centre. With his collaborators he has developed strong linkages with the Departments of Medical Biophysics and Mechanical Engineering. Over the past 20 years the laboratory has been successful



Graham J. W. King, MD, MSc, FRCSC and many of our residents in attendance at this year's lectureship.

in attracting extensive peer review funding including CIHR, CAS, CAN and NSERC and has numerous industry collaborations. His current research interests focus on the biomechanics of the wrist and elbow as well as computer and image guided surgery. He has received the Premier's Research Excellence Award from the Government of Ontario and the J. Edouard Samson Research Award from the Canadian Orthopaedic Research Society. He has represented the Canadian Orthopaedic Association as a North American Travelling Fellow and an American, British and Canadian Travelling Fellow. He has also served as the president of the Canadian Orthopaedic Research Society. He is currently a Professor in the Departments of Surgery, Medical Biophysics and Biomedical Engineering at the University of Western Ontario, Chief of Surgery and Director of the Roth McFarlane Hand and Upper Limb Centre at St. Joseph's Health Centre.



(Above) R3 Resident Lauren Meyer, MD giving her presentation at the 2016 LeCocq Lectureship. (Above right) Graham J. W. King, MD, MSc, FRCSC lecturing on "Radial Head Fractures: Current Concepts" at Harborview Medical Center on January 21, 2016. (Middle right) H. Claude Sagi, MD. (Lower right) R2 Residents Matthew Baron, MD, Jonathan Kark, MD, Zahab Ahsan, MD, Adam O'Brien, MD, Kate Bellevue, MD, Erik Magnusson, MD, and Claudia Christman-Skieller, MD.

Visiting Lecturers

2016 Resident Research Day

June 24, 2016



We were very happy to host Robert D. Zura, MD as the guest lecturer for our Resident Research Day on June 24, 2016. Dr. Zura gave a presentation on “Nonunions: What We Know and Can We Predict Them?”

Dr. Bob Zura is a native of Baltimore, Maryland. He attended the Gilman School and then the University of Virginia, where he played Varsity Lacrosse and lived on the Lawn, Thomas Jefferson’s original Academical Village. He returned to Baltimore to study medicine at Johns Hopkins, and back to UVa for his orthopaedic residency. He studied under Drs. Kellam, Sims, and Bosses at the Carolinas Medical Center in Charlotte, NC for his orthopaedic trauma fellowship. Dr. Zura spent 2 years on faculty at the Medical College of Georgia and a year in private practice in Fredericksburg, VA before going to Duke. Dr. Zura spent 12 years at Duke and was the Duke Health System director for orthopaedic trauma and director of the orthopaedic trauma fellowship. He has over 80 peer reviewed publications. His interests include powdered gloves, nonunions, and osteomyelitis.

Dr. Zura has published on novel techniques for treatment of calcaneal tuberosity fractures in the *Journal for Surgical Orthopaedic Advances*, a trial of wound irrigation in the initial management of open fracture wounds in the *New England Journal of Medicine*, treatment of chronic fracture nonunion in the journal *Injury*, and how surgeons make decisions when the evidence is inconclusive in the *Journal of Hand Surgery*. These articles are just a selection of his published work.

He has also given many presentations at meetings such as Osteosynthese International 2015 in Brussels, Belgium, PolyTrauma: XX Congreso de la Asociacion del Trauma Ortopedico in Buenos Aires, Argentina in 2014, AO Trauma Course – Advanced Principles of Fracture Management. Guangzhou, China in 2014, and the South Eastern Fracture Symposium in Durham, North Carolina.

Bob is married to Marianne Zura who is a non-practicing Pediatrician and a mother of 3 wonderful and goofy children. Conor is 16, Gavin is 13, and Adrienne, their little girl, is 8. Dr. Zura has recently relocated to New Orleans, LA where he is Professor and Robert D’Ambrosia Chair of Orthopaedics at the LSU Health Sciences Center.

Visiting Lecturers

2015 Austria-Swiss-German Traveling Fellows

June 20-23, 2015

The University of Washington Department of Orthopaedics and Sports Medicine hosted the Austria-Swiss-German (ASG) Traveling Fellowship June 20-23, 2015. The ASG tour promotes international travel for the exchange of medical ideas. During even years, two Americans, one Canadian, and one British orthopaedic surgeons tour orthopaedic centers in Austria, Switzerland and Germany for three to four weeks. During odd

Akash Gupta, Neil Tarabadkar and Ms. Julie Agel. Afterwards, they attended a Seattle Mariners baseball game. The next day, Drs. Tarabadkar and Domes took the Fellows on a tour of Pike Place Market where they also had lunch. A tour by water of Lake Union and the University of Washington followed. After, they visited the Ballard Locks and Golden Gardens. The day ended with dinner at University Village.

The Fellows gave their ASG

scrubbed in with Drs. Navin Fernando to observe hip and knee cases. Dr. Akash Gupta brought the Fellows to University Village for dinner with Drs. Howard Chansky, Navin Fernando, and Adam Sassoon. On Tuesday, the Fellows returned to Northwest Hospital - where they observed Dr. Sassoon in the OR - and the University of Washington Medical Center and visited with Dr. Darin Davidson at the Seattle Cancer Care Alliance.



(Left to right) Marcus Egermann, MD, Hermes Howard Miozzari, MD, Akash Gupta, MD, Christoph Zilkens, MD, and Philipp T. Funovics, MD.

years, one Austrian, one Swiss and two German orthopaedic surgeons tour orthopaedic centers in North America for a three to four week period. In 2015, we were happy to host Marcus Egermann, MD from Berlin, Germany, Philipp T. Funovics, MD from Vienna, Austria, Hermes Howard Miozzari, MD from Geneva, Switzerland, and Christoph Zilkens, MD from Dusseldorf, Germany.

Upon arrival the ASG Traveling Fellows had an early dinner with Drs. Carlo Bellabarba, Howard Chansky,

Presentations on Monday June 22nd. Dr. Zilkens lectured on "Value of advanced cartilage imaging in hip joint preservation surgery." Dr. Funovics spoke on outcomes and sarcoma. Dr. Miozzari discussed "Primary TKA in fractures of the tibial plateau." And Dr. Egermann gave his lecture on "Synthetic bone substitute in orthopaedic surgery." After the presentations, they toured Harborview Medical Center, University of Washington Medical Center and Northwest Hospital. At Northwest Hospital, the Traveling Fellows

In 2015, University of Utah, University of Arizona, University of California, San Diego, University of California, Irvine, University of California, San Francisco, Oregon Health and Science University, University of British Columbia, Children's Hospital Boston, and the University of Washington hosted the Austria-Swiss-German Traveling Fellowship. Drs. Sassoon, Fernando, Chansky, and Davidson were happy to host the fellows and hope their time in Seattle was a productive exchange of medical experience.

The background of the slide features a large, light gray watermark of the University of Washington Orthopaedics & Sports Medicine logo. The logo is circular and contains the text "UNIVERSITY OF WASHINGTON" at the top, "ORTHOPAEDICS & SPORTS MEDICINE" at the bottom, and a central emblem depicting a tree and a lighthouse.

Basic Science Articles

“We know what we are, but know not
what we may be.”

— William Shakespeare

Progenitor Cells In Adult Human Digits

Cristi Stoick-Cooper, PhD, Brent Fall, BS, Andy Zhou, BS, Ursula K. Holder, BS, Colin J. Teteak, BS, Ashley A. Jaeger, BS, Timothy A. Petrie, PhD, Randall T. Moon, PhD, and Christopher H. Allan, MD

We asked whether progenitor cells (which might participate in regeneration, with appropriate signals and environment) are present in adult human digit tips. Mesenchymal cells from five amputated, non-replantable adult human digits from four individuals were isolated, culture-expanded, and analyzed via PCR and/or immunochemistry revealing expression of multiple progenitor cell markers. Cells were also shown capable of differentiation into bone, cartilage and fat lineages using commercially available media. Adult human digit-derived cells therefore satisfy multiple criteria for progenitor cells, suggesting that regeneration-competent cells may persist into adulthood in human digits, and that our inability to regenerate after digit tip amputation may be due to barriers other than cellular incapacity. These findings provide the impetus for subsequent work to identify and overcome those barriers.

Introduction

Digit and limb injury and amputation are significant public health problems for both military and civilian populations. Recent reports indicate that over half of all survivable injuries in the conflicts in Iraq and Afghanistan have involved the extremities[1]. The World Health Organization's 2003 "Report on the Burden of Musculoskeletal Conditions at the Start of the New Millennium"[2] related a prevalence of severe limb trauma (fractures, dislocations, crushing injuries, open wounds, amputations, burns and neurovascular injuries) of 35.8 per 1000 people, representing 12% of all impairments from any cause and affecting almost ten million persons in the United States alone.

While not currently a therapeutic option, there is evidence that mammalian systems do retain some regenerative capacity. Digit and limb/appendage regeneration occurs perfectly in some organisms (axolotl; zebrafish), imperfectly in others (digit tips only—Xenopus; mouse; human children), and poorly in human adults[3]. The observation of digit tip regeneration in children[4,5,6] but not adults suggests that whatever regenerative capacity we possess declines with age. The reasons for this loss of regenerative capacity across the human lifespan are not known, but loss of cellular plasticity with age seems a likely contributor.

We asked 1) whether we could isolate a cell population from adult

human digits using mesenchymal stem cell culture media; 2) whether markers of progenitor cells are expressed by these cells; and 3) whether these cells could contribute to formation of bone, cartilage, and fat—defining characteristics of multipotent mesenchymal stromal cells[7,8,9] and necessary for rebuilding a lost part. If not, this first barrier to digit and limb regeneration will need to be overcome for the process to occur in adult humans. If such cells are present, then work can begin on overcoming barriers to human limb regeneration further along the pathway[10].

Materials and Methods

Establishing and Characterizing Human Distal Phalanx Cell Lines

Adult human digits traumatically amputated and found unsuitable for reattachment were obtained through the section of Surgical Pathology at Harborview Medical Center with full UW IRB approval. Five specimens from four individuals were obtained. Specimens were stored in serum-free digit transport medium for dissection under sterile laboratory conditions. Loose connective tissue mesenchyme was collected, removing the connective tissues beneath the nail and above the bone of the distal phalanx (P3). Excised phalangeal connective tissues were placed in dissection medium (2% FCS in DMEM supplemented with 2mM glutamine and 0.05mg/ml gentamicin) with Liberase Blendzyme (Roche Applied Science) in 35mm Petri dishes (with and without fibronectin) to dissociate cells overnight in 37°C in

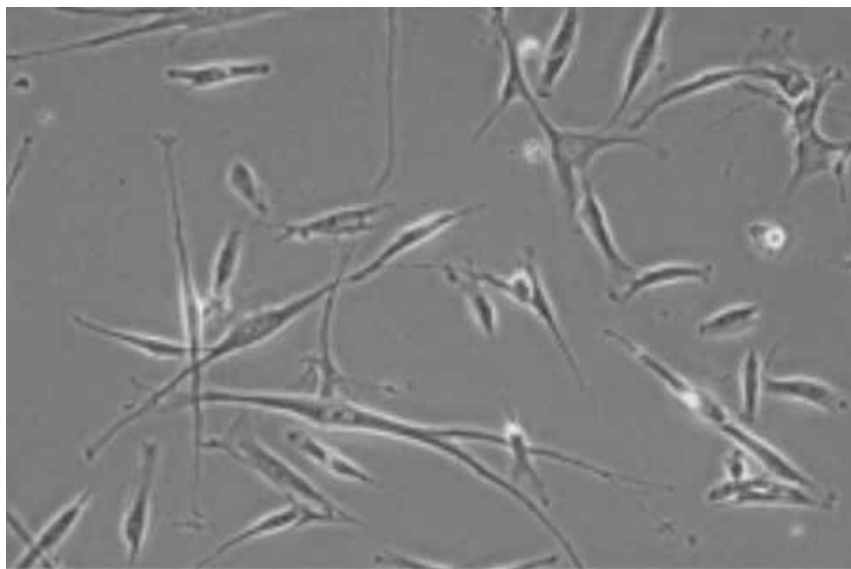


Figure 1: Adult human digit-derived cells demonstrate elongated nuclei and cellular processes after approximately ten days in culture.

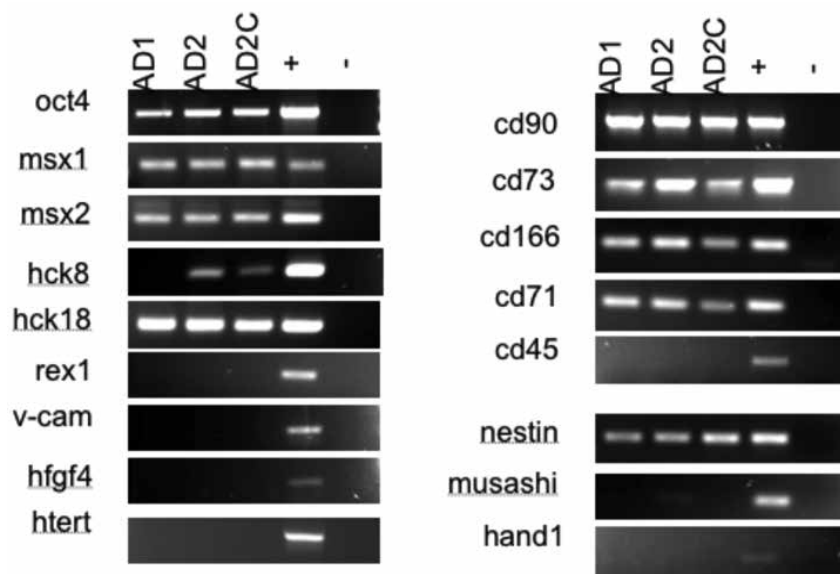


Figure 2: PCR gene expression profiling of cells cultured in MSC media document multiple progenitor markers including OCT4, MSX1, MSX2, CD71, CD73, CD90, CD166, and Nestin. (AD#: adult digit number 1 through 5; C: confluent; +: positive control; -: negative control).

a cell culture incubator with 5% CO₂. Medium was changed the next day to mesenchymal stem cell medium and changed every 4 days thereafter. Cells were grown to 50% confluence and then passaged with a split ratio of 1:3.

Reverse Transcriptase PCR/ Immunocytochemistry

Adult human digit-derived cells from beneath the nail matrix were cultured in MSC medium, grown to confluence, and maintained in culture, passaging when necessary, for a minimum of 10 days. Cells were lysed in TRIzol (Invitrogen) and RNA isolated. Samples were incubated and centrifuged. RNA pellets were washed in 75% ethanol, vortexed, centrifuged and air-dried. cDNA sequences were made following RevertAid RT Kit instructions (Thermo Scientific). SYBR-Green reagent (Sigma-Aldrich) was added to primer solution and cDNA and mixed, centrifuged and run using a Lightcycler (Roche) 96-well device and software. Amplification products were identified by size on a 2% agarose gel. Immunocytochemistry was performed with antibodies to CD90, CD 105, CD106, CD146, CD166 and Stro-1 (Sigma-Aldrich) using a FACS Canto flow cytometer and analyzed with FACS Diva software (BD Biosciences).

Differentiation Cultures

Cells isolated as above were cultured to mid-log growth phase confluence (60 to 80%) in 24-well fibronectin coated plates at 40% O₂,

37°C in Invitrogen Stempro Osteogenic, Adipogenic or Chondrogenic media (changed every 3-4 days) for 26 days. For chondrogenesis, micromass pellet cultures were established following the manufacturer's directions. Analyses were performed as follows:

Osteogenic differentiation: media was removed from wells, cells rinsed and fixed in 4% formaldehyde, and stained with 2% Alizarin Red S solution (pH 4.2) for 2 to 3 minutes to prepare for light microscopy and image capture.

Chondrogenic differentiation: cells were prepared and fixed as above, then stained with 1%

Alcian Blue solution prepared in 0.1 N HCL for 30 minutes for microscopy and imaging.

Adipogenic differentiation: cells were prepared and fixed as above, then stained with oil red O for imaging.

Results

Establishment and Characterization of Human Distal Phalanx Cell Lines

Cells were isolated & dissociated from the P3 region (distal phalanx) of adult human digits into single cell suspensions. Approximately 0.1% of cells survived dissociation. Cells proliferated and were frozen and passaged over 8+ passages and 60 days in culture. After initial plating, proliferative cells reached confluence in 30 to 36 hours. They were passaged every 5 to 7 days at a 1:10 to 1:20 split ratio. After cells were initially dissociated and plated they demonstrated elongate nuclei and short processes. After approximately 10 days in culture, cells displayed much longer processes characteristic of mesenchymal cells (Figure 1).

Progenitor Cell Marker Expression

Reverse transcriptase PCR (Figure 2) and immunocytochemistry (Figure 3) showed that after 10 days in culture, human P3 cells expressed multiple progenitor and mesenchymal stem cell markers [7,8, 9] including OCT4, Msx1 (required for digit regeneration in mice) [11], Msx2, V-CAM(CD106), CD73, CD90, CD105, CD146, CD166, Nestin, and Stro-1. They did not express Rex1, Sox2, Pax6, CD29 or CD45.

Differentiation Assays

Cells isolated from adult human P3 mesenchymal tissue, cultured in osteogenic, chondrogenic or adipogenic differentiation media, and stained for calcium deposits, sulfated proteoglycans, or fat respectively displayed histological characteristics typical of bone, cartilage, and fat as compared to control cultures (not shown) in standard non-differentiation media (Figure 4).

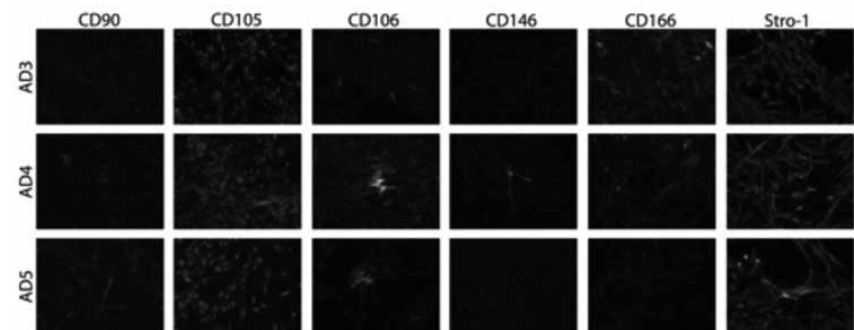


Figure 3: Immunocytochemistry shows multiple adult digit-derived cell lines are positive for multiple MSC markers including CD90, CD105, CD106, CD146, CD166 and Stro-1.

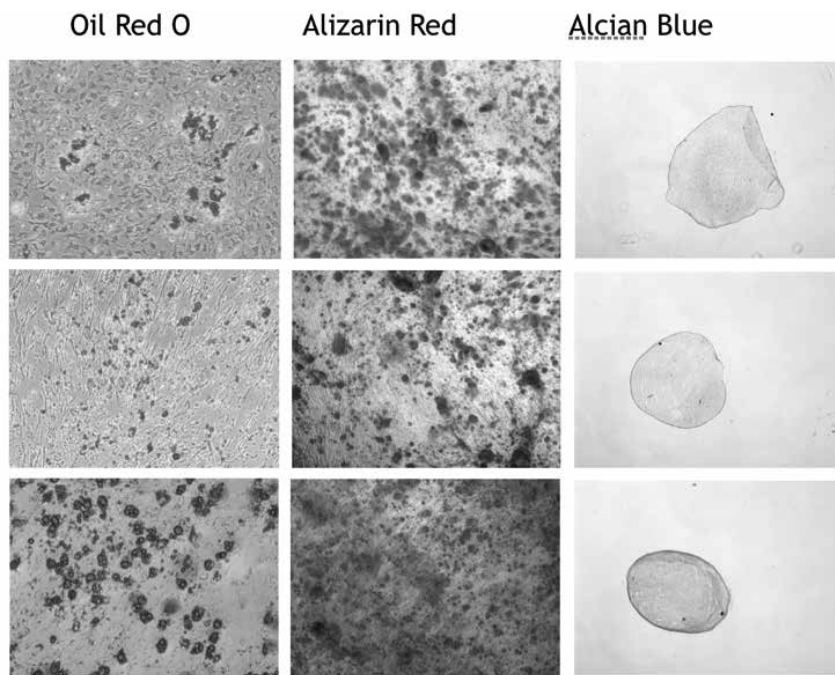


Figure 4: Differentiation tests of adult human digit-derived cells. Cells cultured in 24 well fibronectin coated plates at 40% O₂, 37°C in Invitrogen Stempro Adipogenic, Osteogenic and Chondrogenic media (changed every 3-4 days) for 26 days. Cells isolated from adult human digits can differentiate into fat, bone and cartilage.

Discussion

This study provides the first evidence we are aware of that adult human digits retain a population of cells that express progenitor cell markers and can differentiate into cell types of multiple tissues when appropriately directed. Our findings suggest that the failure of adult humans to regenerate even the simplest of appendages—the digit tip—may represent not a fundamental incapacity at the cellular level but rather another obstacle, e.g. inadequate numbers of regeneration-competent cells, unfavorable local conditions or absent signals. This work should stimulate future investigation to identify those downstream barriers, with the hope that we will one day overcome them and add ‘regeneration’ to the list of treatment options for patients losing digits and limbs to amputation.

Acknowledgments

This work was funded by the Army Research Office (ARO) under contract number 56970-LS-DRP.

References

1. Hinck D, Franke A, Gatzka F. Use of vacuum-assisted closure negative pressure wound therapy in combat-related injuries—literature review. *Mil Med.* 2010 Mar;175(3):173-81.

2. Global burden of musculoskeletal disease revealed in new WHO report. *Bull World Health Organ.* 2003;81(11):853-4.

3. Louis DS, Palmer AK, Burney RE. Open treatment of digital tip injuries. *JAMA.* 1980 Aug 15;244(7):697-8.

4. Illingworth CM. Trapped fingers and amputated finger tips in children. *J Pediatr Surg.* 1974 Dec;9(6):853-58.

5. Douglas BS. Conservative management of guillotine amputation of the finger in children. *Aust Paediatr J.* 1972 Apr;8(2):86-9.

6. Rosenthal LJ, Reiner MA, Bleicher MA. Nonoperative management of distal fingertip amputations in children. *Pediatrics.* 1979 Jul;64(1):1-3.

7. Dominici M, Le Blanc K, Mueller I, Slaper-Cortenbach I, Marini F, Krause D, Deans R, Keating A, Prockop Dj, Horwitz E. Minimal criteria for defining multipotent mesenchymal stromal cells. The International Society for Cellular Therapy position statement. *Cytotherapy.* 2006;8(4):315-7.

8. Pittenger MF, Mackay AM, Beck SC, Jaiswal RK, Douglas R, Mosca JD, Moorman MA, Simonetti DW, Craig S, Marshak DR. Multilineage potential of adult human mesenchymal stem cells. *Science.* 1999 Apr 2;284(5411):143-7.

9. Gonzalez R, Maki CB, Pacchiarotti J, Csontos S, Pham JK, Slepko N,

Patel A, Silva F. Pluripotent marker expression and differentiation of human second trimester Mesenchymal Stem Cells. *Biochem Biophys Res Commun.* 2007 Oct 19;362(2):491-7.

10. Endo T, Bryant SV, Gardiner DM. A stepwise model system for limb regeneration. *Dev Biol.* 2004 Jun 1;270(1):135-45.

11. Wu Y, Wang K, Karapetyan A, Fernando WA, Simkin J, Han M, Rugg EL, Muneoka K. Connective tissue fibroblast properties are position-dependent during mouse digit tip regeneration. *PLoS One.* 2013;8(1):e54764.

Localization Of Type IIA Collagen In Annulus Fibrosus Of Adult Intervertebral Disc

Jiann-Jiu Wu, PhD, Audrey McAlinden, PhD, David R. Eyre, PhD,
and Russell J. Fernandes, MSc, PhD

Significance

For next generation tissue-engineered constructs and regenerative medicine to succeed clinically, the basic biology and the composition of tissues these repair techniques seek to restore have to be fully determined and understood. Using the latest reagents coupled with tried and tested methodologies we continue to discover hitherto undetected structural proteins in mature intervertebral disc tissue.

Introduction

In the adult spine, the function of carrying and transmitting mechanical compressive load, as well as flexibility that allows bending and twisting, rests on the intervertebral discs that join adjacent vertebral bodies (1). Anatomically the mature disc consists of three distinct but integral regions: (i) the soft inner nucleus pulposus (NP) in the center of the disc; (ii) the tough sinewy outer annulus fibrosus (AF) that laterally encloses the NP; and (iii) the cartilaginous end plate that vertically encloses the NP (2). The main structural macromolecular components of all the regions are collagens (types I and II) and proteoglycans (aggrecan). Types III, IX, and VI collagens have also

been detected as has elastin, another structural protein. The collagens polymerize into fiber bundles in the AF lamellae that are concentrically formed around the NP. Degeneration of the disc almost always involves a compromised AF through which the NP exudes, resulting in acute and sometimes crippling pain.

The inter-lamellar architecture within the AF is of intense biochemical interest as it is accepted that sliding does not occur between annular layers (3). Confocal imaging of normal lamellae suggests that inter-lamellar connections involve a variety of molecular interactions (4). Radial cross-bridging elements have also been identified in sheep discs, bovine tails, and adult human discs that appear to be a consequence of vascular regression (5). During human intervertebral disc development, the type IIA isoform of type II collagen (+Exon 2, extra 69 amino acids) is primarily synthesized and there is a developmentally regulated splice out of the IIA domain within the nucleus pulposus and inner annulus. We hypothesize that type IIA collagen isoform is synthesized in mature intervertebral disc where it contributes to the organization of

the collagen bundles. Here we report on the biochemical presence and immunohistochemical localization of pN-type IIA and mature type II collagen in the adult bovine intervertebral disc.

Methods

Tissue Specimens: Normal adult steer tail intervertebral discs were obtained fresh from the local butcher and frozen at -80°C until use.

Collagen extraction: Clean white nucleus pulposus (NP) was dissected from the discs. The region between the NP and AF (inter-zone) was dissected next leaving the outer tough AF. Following PBS rinses, the tissues were extracted with Tris buffered 4M guanidine hydrochloride (GuHCl) for 24 hrs at 4°C. Following dialysis in distilled water, the extracts were lyophilized and aliquots dissolved in Laemmli sample buffer.

Western blots: Collagen in tissue extracts were resolved by Laemmli-SDS-PAGE, transferred to PVDF membrane and probed with monoclonal antibody to type II collagen (1C10) and polyclonal antibody to type IIA collagen which recognizes the exon 2 domain of type IIA collagen (6). Mouse type IIA collagen was used as control.

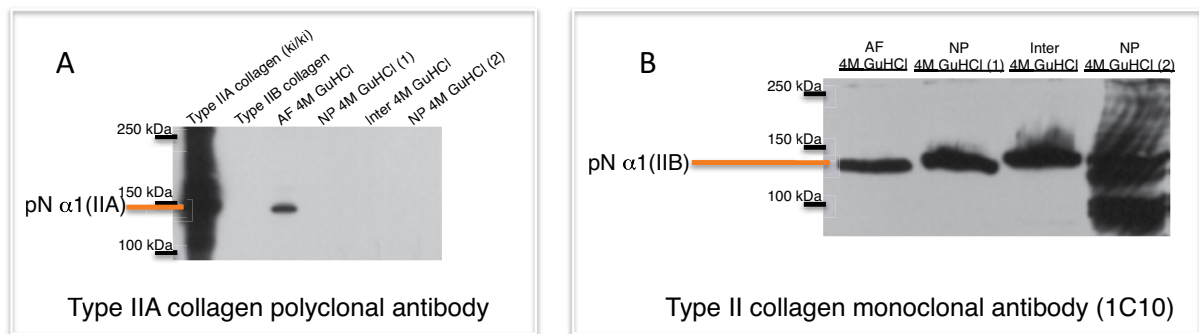


Figure 1: (A) Western blot analysis using antibodies specific to type IIA collagen of collagen extracted from adult bovine intervertebral disc. Lane 1, control type IIA collagen; Lane 2, Type IIB collagen; Lane 3, 4M GuHCl extract of annulus fibrosus (AF); Lane 4, 4M GuHCl extract of nucleus pulposus (NP); Lane 5, 4M GuHCl extract of AF-NP intermediate zone (Inter); Lane 6, 4M GuHCl extract of NP. A clear presence of only the pN- α 1(IIA) collagen chain, as a single band is seen in Lane 3, indicating the presence of type IIA collagen in AF but not in NP. (B) Immunoblot analysis using antibody to the helical region of type II collagen (1C10) of collagen extracted from adult bovine intervertebral disc. Lane 1, 4M GuHCl extract of annulus fibrosus (AF); Lane 2, 4M GuHCl extract of nucleus pulposus (NP); Lane 3, 4M GuHCl extract of AF-NP intermediate zone (Inter); Lane 4, 4M GuHCl extract of NP. A robust signal for pN- α 1(IIB) chains of type II collagen was found in NP, AF and the inter-zone, indicating that type IIB collagen is present in all extracts. Note the slower migration of the pN- α 1(IIA) chain (extra 69 amino acids) as compared to the pN- α 1(IIB) chain. Type IIA collagen is present only in the adult annulus fibrosus.

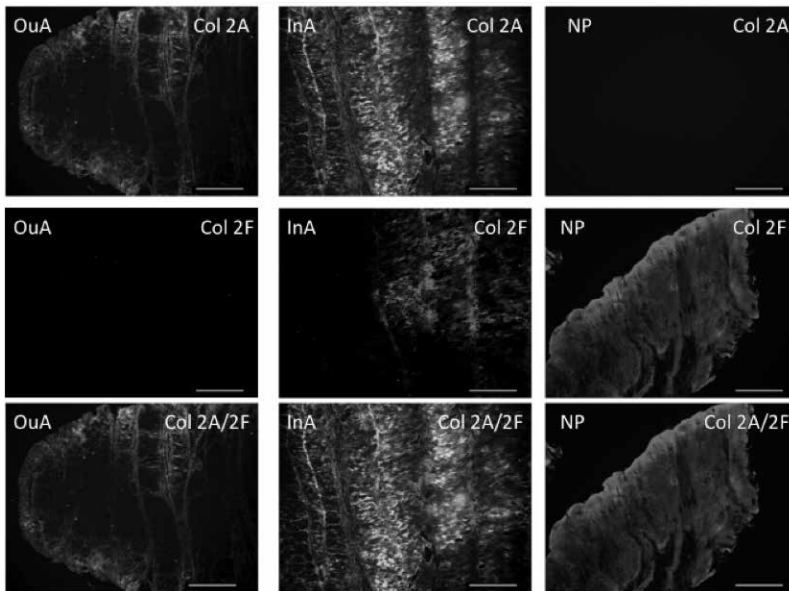


Figure 2: Immunohistochemical localization of type II collagen (Col2F, bright red, middle row) in sagittal sections of steer intervertebral disc clearly shows abundant type II collagen in the extracellular matrix of the NP, inner AF/inter-zone (InA) closer to the NP and to a lesser extent in the InA adjoining the outer AF. In this region type II collagen seemed to be concentrated within the inter-lamellar regions. No type II collagen was detected in the outer AF (OuA). Type IIA collagen (Col2A, bright green, upper row) was not detected in the NP and the inner AF closer to the NP but was clearly detected in the regions of the InA and in the OuA. When both the signals were merged (lower row), it was clear that the Col2F (bright red) signal was more localized to the inter-lamellar regions of the inner AF, and both Col2F (bright red) and Col2A (bright green) signals localized as together (yellow) within the lamellae. Bar=100 μ m.

Immunohistochemistry: Cryosections (8-10 μ m, sagittal orientation) of the AF and NP were cut in the laboratory of Dr. Audrey McAlinden, Dept. of Orthopaedics, Washington University, St. Louis, MO. Sections were then probed with type IIA rabbit polyclonal antibody (Col2A), rat polyclonal antibody to type II collagen full triple helix (Col 2F) and type I collagen antibody (Col 1) and detected using high-resolution fluorescence microscopy as we have done before (6). Alexa dye 488 for Col2A (bright green), Alexa dye 594 for Col2F (bright red).

Results

As seen in Figure 1A, western blot analysis using type IIA collagen antibodies, showed a clear presence of the pN- α 1(IIA) chain in the 4M GuHCl extract of AF but not in the two samples of NP and the AF inter-zone. A robust signal was observed for control type IIA as we have shown previously (6). Probing a blot with similar IVD extracts using the type II collagen antibody (1C10) revealed the presence of α 1(II) collagen chains in all the extracts (Figure 1B). Immuno-histochemical localization of type II collagen (Col2F,

red) in sagittal sections of intervertebral disc (Figure 2) clearly shows the presence of type II collagen in the NP, inter-zone of inner AF (InA), but not in the outer AP (OuA). Type IIA collagen (Col2A, green) was not detected in the NP, but was detected in the inner AF and in the outer AF. When both the signals were merged, it was clear that the Col2F signal (red) was more localized to the inter-lamellar regions of the inner AF, and both Col2F and Col2A signals localized together in the lamellae (yellow). Type I collagen localized primarily to the outer AF and very faintly in the inter-zone of the inner AF (results not shown).

Discussion

Using biochemical and immunohistochemical methods, we have discovered that type IIA collagen, usually viewed as a developmental collagen, is present in the AF of mature steer intervertebral disc and surprisingly absent in the NP. Triple helical collagen is present in all the regions of the disc confirming a fibrocartilage collagen phenotype. The localization of a proportion of type II collagen exclusively within the inter-

lamellae regions of the inner annulus is also an interesting finding and warrants a further investigation into intermolecular interactions to stabilize inter-lamellar adhesion.

The localization of type IIA in adult inner AF is novel and unlike that observed during development where the type IIA amino pro-peptide is processed and could not be detected (7). Knowledge as to whether type IIA collagen is assembled as an independent fibrillar network or incorporated into the existing collagen network conferring characteristic structural properties is relevant for future intervertebral disc tissue regeneration or engineering endeavors.

References

1. Yu, J et al., (2005) SPINE 30 (16), 1815-1820.
2. Yu, J et al., (2002) J. Anat. 201, 465-475
3. Michalek, et al., (2009) J. Biomech. 42, 2279-2285
4. Iatridis, JC., (2009) Nature Materials 8, 923-924
5. Smith, LJ and Elliott, DM., (2011) Matrix Biology 30, 267-274
6. Lewis, R et al., (2012) Matrix Biology 31, 214-226
7. Zhu, Y et al., (2001) Dev. Dyn. 220, 350-362

Acknowledgements

NIH grants AR057025 (RJF), AR053513 (AM), AR036794 (DRE). Soumya Ravindran, Geoffery Traeger and Bryan Carter for their technical expertise.

Developmental Modifications In Type I Collagen Highlight Tissue-Defining Variances Between Ligament And Tendon

David M. Hudson, PhD, Jyoti Rai, MS, Marilyn Archer, BS, MaryAnn Weis, BS, Jiann-Jiu Wu, PhD, and David R. Eyre, PhD

Introduction

Tendon degeneration often leads to rupture. After surgical repair, tendons fail to regain their native structure and function, which can lead to re-tear events [1]. Interestingly, fetal tendon maintains the capacity to completely remodel and regenerate after injury, with no scarring [2]. Collagen constitutes about 80% of the dry weight of tendons and ligaments. Collagen cross-linking is the definitive post-translational modification that imparts tensile strength to these connective tissues. As tendons and ligaments grow and develop, the collagen cross-links are known to mature, strengthen and change in profile [3]. Accordingly, changes in cross-linking are likely associated with tissue degeneration. Using mass spectrometry, we have investigated both the mature cross-links and cross-linking lysines of type I collagen from

fetal and adult tendon and anterior cruciate ligament to help understand the post-translational development of collagen during growth. We hypothesize that collagen from tendon and ligament will exhibit unique post-translational variances and distinct cross-linking features during development.

Methods

Anterior cruciate ligament (ACL), medial collateral ligament (MCL), lateral collateral ligament (LCL) and tendon (T) were isolated from adult and fetal bovine knees purchased from Sierra for Medical Science (Whittier, CA). Type I collagen was solubilised from the tissues by heat denaturation for 2 minutes at 100°C in Laemmli buffer. The glycosylation and 3-hydroxyproline content in collagen α -chains was analyzed by electrospray mass spectrometry using an LTQ XL linear

ion-trap mass spectrometer equipped with in-line liquid chromatography [4]. Molecular locations of posttranslational modifications were identified using MS/MS fragmentation. The collagen pyridinoline cross-link content (hydroxylysyl pyridinoline and lysyl pyridinoline) were determined in each tissue by fluorescence monitoring with reverse-phase HPLC.

Results

Type I collagen isolated from adult bovine tendon is known to contain higher levels of prolyl 3-hydroxylation compared to other connective tissues, such as bone and skin. This molecular phenotype, which was once thought unique to tendon, was also observed in adult bovine anterior cruciate ligament (Figure 1). Another commonality found between the two connective tissues was the post-translational increase in prolyl 3-hydroxylation that occurs during development. Indeed, multiple type I collagen substrate sites exhibited only minimal levels of the modification in fetal tissues compared to adult tissues. The cross-linking residue K87 from both α -chains of type I collagen from ligament and tendon were fully glycosylated in fetal tissue. A distinct feature of tendon development was the complete loss of glycosylation at the K87 residues in adult tissue. The adult ligaments investigated in this study varied significantly in the degree of modification at the K87 residues. These results are summarized in Table 1.

Discussion

Why do only some ligaments heal? How do fetal tendons regenerate? It appears likely that the distinctive post-translational phenotypes of ligament and tendon collagens and how they change with development are related to these properties. It is becoming increasingly clear that as connective tissues develop and mature, their collagen molecular

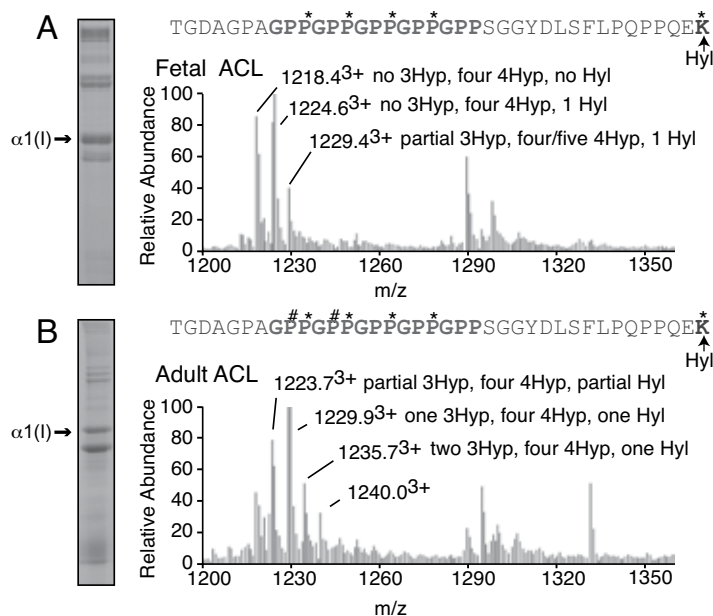


Figure 1: Type I collagen from anterior cruciate ligament exhibits unique age-dependent 3-hydroxyproline profile. LC-MS profiles of in-gel trypsin digests of the collagen α 1(I) chain from fetal and adult bovine ACL. (A) MS profile of fetal bovine ACL shows only partial 3-hydroxylation (~10%) at the C-terminal GPP motif of α 1(I); (B) MS profile at the same site of adult bovine ACL shows a hydroxylation similar to bovine tendon 3-hydroxylation (~60%). The trypsin digested peptide is shown with P* indicating 3Hyp, P# indicating 4Hyp and K* indicating Hyl.

Adult	Modification				
	Tissues	Lys	Hyl	G-Hyl	GG-Hyl
$\alpha 1(I)K87$	Tendon	20%	80%	-	-
	ACL	-	-	-	100%
	LCL	-	33%	22%	45%
	MCL	90%	-	-	10%
$\alpha 2(I)K87$	Tendon	-	100%	-	-
	ACL	-	25%	7%	68%
	LCL	-	36%	13%	50%
	MCL	-	80%	5%	15%
Fetal					
$\alpha 1(I)K87$	Tendon	-	-	-	100%
	ACL	-	-	-	100%
	LCL	-	-	-	100%
	MCL	-	-	-	100%
$\alpha 2(I)K87$	Tendon	-	-	-	100%
	ACL	-	-	-	100%
	LCL	-	-	-	100%
	MCL	-	-	-	100%

Table 1: Glycosylation patterns on type I collagen cross-linking residues from tendon diminish with age. Modifications on lysine 87 from both α -chains of type I collagen were measured in adult and fetal bovine tissues using mass spectrometry. Lysine modifications include unmodified lysine (Lys), hydroxylysine (Hyl), galactosyl-hydroxylysine (G-Hyl) and glucosylgalactosyl-hydroxylysine (GG-Hyl). Tissues included were tendon, anterior cruciate ligament (ACL), lateral collateral ligament (LCL) and medial collateral ligament (MCL). The percentages were determined based on the ratio of the m/z peaks of each post-translational variant as previously described [4].

phenotype also changes. The unique molecular features observed between the collagens of these tissues likely highlights subtle yet distinct structural properties of each tissue (Figure 2). A greater understanding of collagen cross-linking during tendon and ligament development will provide insight into the pathobiology that leads to rupture and incomplete healing of mature tendon.

Significance

Unlike adult tendons, injured fetal tendons are capable of tissue repair possibly through effectively restoring the native collagen fibrillar architecture. Is this related to their presumed increased cellularity? Defining developmental variances in collagen post-translational modifications may be used diagnostically in the understanding of healthy tendon and ligament development and regeneration.

References

1. Duquin T. et al., *Am J Sports Med* (2010). 38; 835-841.
2. Andarawis-Puri N. et al., *J Orthop Res* (2015). 33; 780-784.
3. Frank C. *J Musculoskel Neuron Interact* (2004). 4; 199-201.
4. Weis M. et al., *J Biol Chem* (2010). 285; 2580-2590.

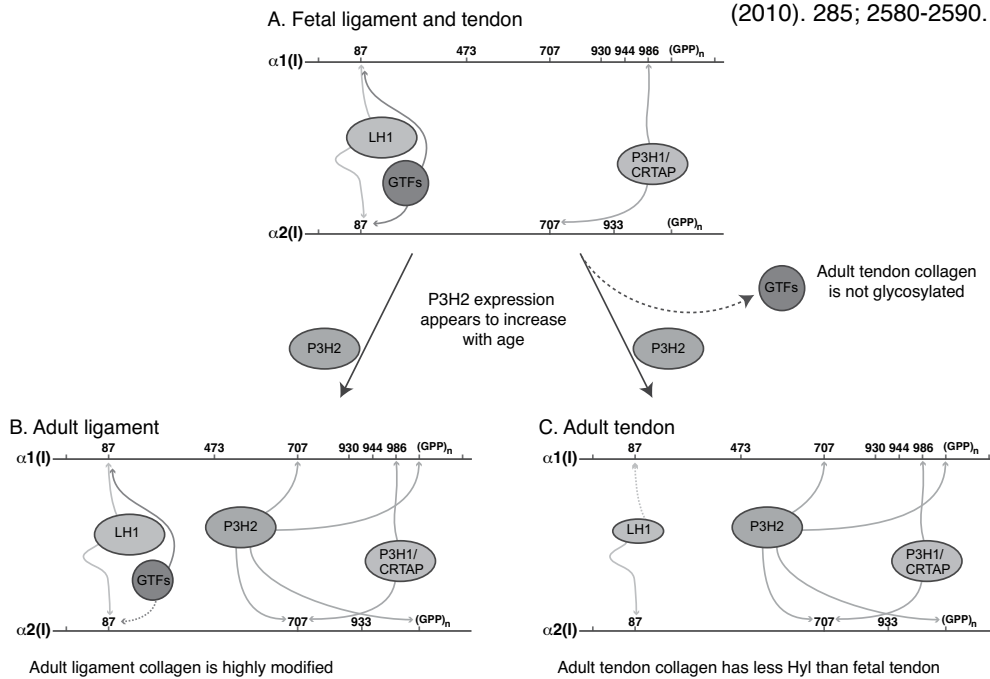


Figure 2: Model for the post-translational variances observed between ligament and tendon type I collagen during development. Mass spectrometric evidence suggests that type I collagen from fetal tendon and ligament are posttranslationally indistinguishable (A). Specifically, fetal type I collagen from tendon and ligament has full prolyl 3-hydroxylation at $\alpha 1(I)986$ and $\alpha 2(I)707$, but significantly lower levels of modification at the known substrate sites of prolyl 3-hydroxylase 2 (P3H2). Fetal tissue also has full lysyl 5-hydroxylation and glycosylation (glucosyl-galactosylhydroxylysine) on cross-linking Lys87 residues from both α -chains. P3H2 and glycosyltransferase (GTF) appear to be uniquely regulated in ligament and tendon. For example, adult tendon does not have the glycosylations found in fetal tissue (C). Adult tendon was also found to have slightly lower levels of Hyl than ligament. High levels of prolyl 3-hydroxylation were found in both adult ligament and adult tendon (B,C).

FishBone 2015: Advancing The Use Of Fish For Skeletal Research -- A Meeting Report

Ronald Y. Kwon, PhD and Matthew P. Harris, PhD*

On October 8, 2015, the University of Washington Department of Orthopaedics and Sports Medicine cosponsored FishBone 2015, the first US workshop dedicated to advancing zebrafish, medaka, and other laboratory fish models for skeletal research. This symposium gathered international leaders from the zebrafish community with bone biologists attending the American Society for Bone and Mineral Research Annual Meeting as a first step toward incorporating fish as a standard model for bone biomedical research.

Background

Fishes have become key experimental models in which to address gene function during development in part due to the ease of genetic analysis and real time imaging during development. Seminal research into patterning and differentiation of the skeleton in both the zebrafish and medaka has served as a foundation for understanding the genetic basis of skeletogenesis and conservation of mechanisms across vertebrates. With the establishment of precision genomic editing in these models, many clinical investigators and translational researchers have started to incorporate these models in their work. The objective of the FishBone workshop is to bring together established and potential fish researchers with those from different disciplines to present up-to-date findings, foster collaborations, and broaden awareness. The first workshop meeting was designed to define the key areas in which fishes can be useful for analysis of skeletogenesis and function of candidate disease genes, as well as where future progress needs to be made to extend the utility of fishes in comparative analysis of skeletogenesis.

Overview

Currently, there are meetings at which research centering on skeletal biology of fishes is discussed within and among a broader community. Meetings such as *Interdisciplinary Approaches in Fish Skeletal Biology* (IAFSB) or species-specific meetings such as the *International Zebrafish Meeting* have provided an important medium for discussion of skeletal research

in fishes. However, rarely are these findings integrated with the broader skeletal research community. As small laboratory fishes such as the zebrafish are becoming more frequently utilized as models for vertebrate development, the benefits and limitations of using fishes to investigate vertebrate skeletogenesis need to be discussed extensively within the broader community.

The annual meeting of the *American Society of Bone and Mineral Research* brings together experts investigating both clinical and experimental questions in bone and mineralization with a focus on facilitating translation of basic research. The use of fish models historically has been underrepresented at these gatherings. The aim of the FishBone workshop is to help introduce current work in fishes into a broader research community to facilitate integration within the skeletal field. For the first inaugural workshop, leading experts were invited to provide overview and specific case analyses highlighting the strength of fish models in comparative analysis among vertebrates. To promote discussion of current research by younger investigators and to show breadth of research in the area, each session had short rapid-fire oral poster presentations; these sessions were referred to as 'Science Slam'. Below, we highlight topics of the presentations made during the first FishBone workshop.

Oral Session I - Comparative Skeletal Biology: Development and Regeneration

Fishes are quite diverse with over 30,000 different species known to date. This diversity is also manifest

in the variation of skeletal tissue types observed among fishes and the mechanisms by which they form. Dr. Eckhard Witten (Ghent University, Belgium, Dept. of Biology) began the symposium with the first keynote talk discussing the current understanding of the diversity and evolutionary relationships among skeletal tissues. Dr. Witten explained the evolutionary relationships between teleosts and mammals. Noted differences include the fact that teleosts maintain two differentially regulated skeletal systems (the dermal and the endoskeleton), abundance of intermediate skeletal tissue types, differential possession of osteocytes in more basal (zebrafish) and advanced (medaka) species, and a reduced role in calcium metabolism. This overview proved to be a valuable introduction to provide context and motivate the rest of the talks to follow.

As a species-rich and morphologically diverse group, teleosts are ideal to identify evolutionary principles underlying bone shape. This was highlighted by Dr. Charles Kimmel (University of Oregon, Dept. of Biology) who presented findings testing a morphogenetic model of skeletal form. Using the operculum as a case study, Dr. Kimmel asked if morphologies are constrained to certain forms through developmental constraints. Unexpectedly, morphological analysis of opercles and subopercles from ~100 teleost families revealed morphospace distributions inconsistent with constraint. Morphometric analysis revealed extreme diversification among the acanthomorph clade of fishes, suggesting that this group may be susceptible to shape morphological

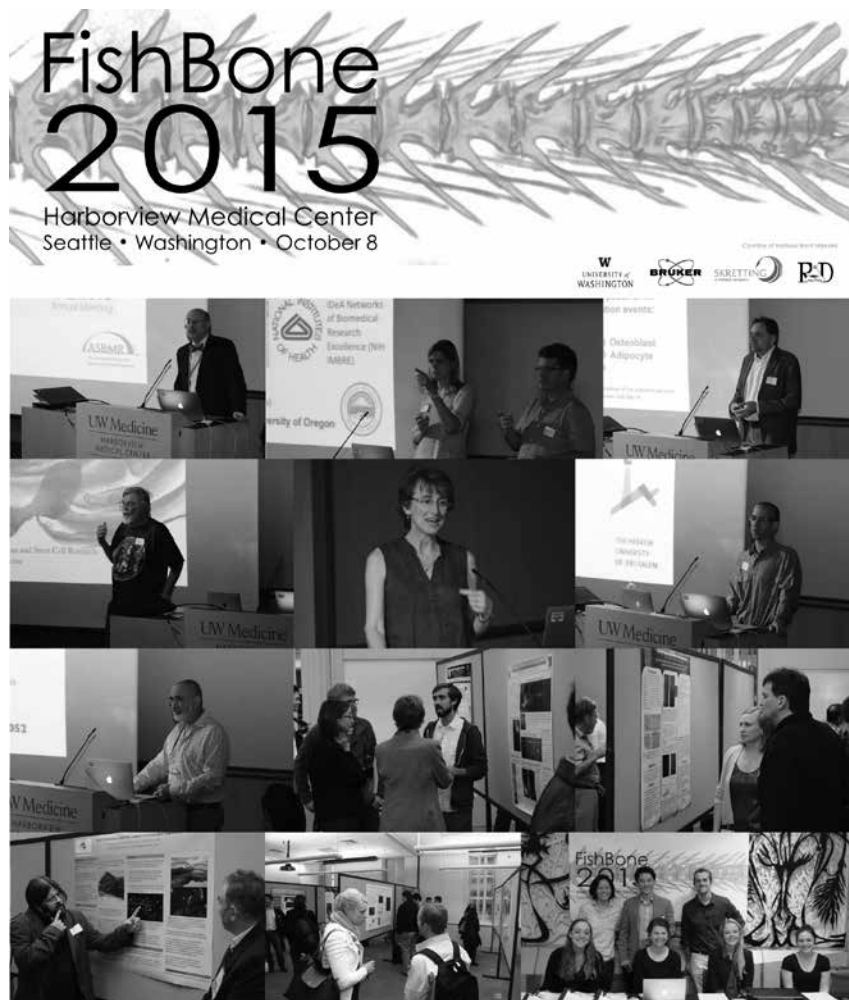

Figure 1: Images from the inaugural FishBone workshop.

reconfiguration.

A disease of interest to model in zebrafish is osteoarthritis, a leading cause of disability in humans. However, a lasting question is whether zebrafish possess comparable synovial joints as mammals. Dr. Gage Crump (University of Southern California, Center for Regenerative Medicine) presented new findings demonstrating that a specialized joint in the zebrafish jaw displays characteristics of mammalian synovial joints. These characteristics include specialized articular chondrocytes, a synovial cavity, and ligament attachment points. Expression of orthologs of mammalian synovial joint-specific genes was observed in this joint. Additionally, these genes were expressed in sticklebacks and the evolutionarily distant bony fish spotted gar suggesting that these processes represent a conserved mechanism of joint formation.

Differentiation of bones in fishes is

quite diverse as well. Unlike more basal teleosts such as zebrafish, advanced teleosts such as medaka do not possess osteocytes. This may be exploited to uncover previous undefined regulatory mechanisms within an anosteocytic (i.e., osteocyte-depleted) environment. Dr. Ron Shahar (Hebrew University, Dept. of Veterinary Surgery) showed that the heavily loaded bills of billfish which do not possess osteocytes, possess numerous secondary osteons -- direct evidence of remodeling in anosteocytic bone. Following this line of evidence, Dr. Shahar described his work on bone of the anosteocytic tilapia which was found to actively adapt to the application of controlled mechanical loads. This work demonstrates the potential within comparative analysis to challenge established ideas within the field and to characterize novel mechanisms underlying skeletal formation and remodeling.

Science Slam I: The high degree of

regenerative competence in zebrafish may be exploited for both comparative and translational purposes. In the first talk of the Oral Poster Session, Dr. Sandeep Paul (University of California, Center for Regenerative Medicine) described a novel model for large-scale bone regeneration in the lower jaw of the adult zebrafish. In contrast to intramembranous bone regeneration that occurs in the fins, lower jawbone regeneration is characterized by robust induction of cartilage-like cells, suggesting that the intrinsic ability for large-scale bone regeneration is not limited to bone that is intramembranous in nature. In the second talk, Dr. David Karasik (Bar Ilan University, Medicine) presented a model of bone regeneration in adult zebrafish induced by partial amputation of the endoskeletal caudal complex. Amputated neural spines exhibited a progressive widening of the stump, suggesting the viability of this approach to investigate regeneration

in the posterior endoskeleton. Finally, Mr. Brandon Douglass (University of Washington, Dept. of Orthopaedics and Sports Medicine) presented a new xenograft model of epimorphic bone regeneration. In these studies, murine osteoblastic cells were directly injected into the blastema of the adult zebrafish tail fin. Injected cells exhibited clear cellular engraftment and stability, indicating that they are fundamentally capable of surviving in an epimorphic regenerative environment. These studies exemplify the versatility of the zebrafish as an experimental model for bone growth and regeneration.

Oral Session II - Genetics Of Skeletogenesis

The broad utilization of fish in modeling gene functions during vertebrate development arose from the results of systematic forward mutagenesis screens and identification of mutants with specific phenotypes. One of the key characters analyzed in these systematic screens is the pattern and differentiation of the larval head skeleton. Through analysis of mutants stemming from these screens, developmental mechanisms of skeletogenesis have been broadly defined. The work of Dr. Tom Schilling (University of California Irvine, Dept. of Developmental and Cell Biology) has been key to the identification and characterization of early patterning of the zebrafish larval skeleton. In the second keynote talk, Dr. Schilling led the session presenting recent findings in his group looking at how cartilage shape is attained through polarization of the chondrocytes. Interestingly, spatial analysis of microtubule organizing centers in differentiated chondrocytes reveals unexpected modules of polarity throughout the craniofacial skeleton. These polarity modules prefigure the locations of later ossification suggesting that, in addition to stacking, another function of polarity is to establish zones of growth, cartilage replacement and bone deposition.

Though in its relative infancy, genome editing techniques such the CRISPR/Cas9 system have already begun to accelerate the ability to explore human genetic landscapes in laboratory fish models. In his talk, Dr. Christoph Winkler (National University of Singapore, Dept. of Biological Sciences) presented findings in which

this system was used to generate *osterix* (*osx*) knock-out mutants in medaka. Interestingly, while mineralization of arches and fins was strongly disrupted in *osx* mutants, mineralization of the vertebrae centra was mostly intact. These data suggest that like its mammalian ortholog, medaka *osx* plays a crucial role in osteoblast maturation and skeletogenesis. Further, they suggest the existence of both *osx*-dependent and *osx*-independent mineralization pathways.

In humans, mutations of *HDAC4* are associated with non-syndromic oral clefts and craniofacial abnormalities. Mimicking the human phenotype, Dr. April DeLaurier (University of South Carolina Aiken, Dept. of Biochemistry) demonstrated that in zebrafish, knockdown of *hdac4* results in larvae with palatal defects including shortened, clefted, or missing ethmoid plates -- cartilaginous elements that are associated with homologous early morphogenetic events as palatogenesis. Evidence was presented suggesting that repression of *mef2ca* by *hdac4* normally keeps the repression of bone formation "in check", allowing bone to form correctly.

Science Slam II: The functional examination of mammalian skeletal orthologs continued in the Oral Poster Session. In the first talk, Dr. Joanna Caetano-Lopes (Boston Children's Hospital and Harvard Medical School) used a new bone resorption assay in scales to demonstrate that mutant zebrafish lacking functional *colony stimulating factor 1 receptor a* (*csf1ra*) exhibit decreased number of TRAP+ osteoclasts. She demonstrated the utility of quantitative resorption assays in the zebrafish for detailing the effect of skeletal mutants having unbalanced bone remodeling. In the second talk, Dr. Claire Watson (University of Washington, Dept. of Orthopaedics and Sports Medicine) examined the role of zebrafish *trichorhinophalangeal syndrome 1 gene* (*trps1*), whose ortholog underlies the human bone disorder of the same name (TRPS), in the context of adult tail fin regeneration. High levels of *trps1* were detected in the joints between unamputated rays as well as in newly forming joints of the regenerate, suggesting that *trps1* plays a role in both joint formation and maintenance. Lastly, Dr. Masahiro Chatani (Tokyo Institute

of Technology, Dept. of Biological Information) used *rankl/opg* double knockout medaka to demonstrate cooperative actions in these factors in regulating bone resorption in the whole body. Interestingly, while both genes affect osteoclast induction, *rankl/opg*-independent pathways of osteoclast differentiation are present that preferentially induce osteoclasts at specific anatomical sites.

Oral Session III - Imaging in the Fish Skeleton

A particular strength of the zebrafish model is the ability to visualize development in real time. However, imaging of skeletogenesis beyond the larval stages requires special techniques. In the third keynote talk, Dr. Shannon Fisher (Boston University, Dept. of Pharmacology) detailed her recent work to visualize skeletal growth of the zebrafish cranium and analysis of mutants with defective suture formation. Using dual-colored transgenic zebrafish labeling genes expressed during bone formation, Dr. Fisher showed the explanatory potential of detailed imaging to understand patterns of growth and the mechanistic causes of mutant phenotypes. Dr. Claire Watson (University of Washington, Dept. of Orthopaedics and Sports Medicine) followed in this session detailing her work in bimodal imaging of gene expression and mineralization using the regenerating zebrafish fin as a case study. Through use of a novel integrated imaging method, coupled analysis of mineralization and signaling during bone formation can be assessed contemporarily *in vivo*. These imaging approaches are a strength of the zebrafish and other small laboratory fish models as the optical clarity of the developing and adult fish lends itself to such detailed analysis.

Dr. Julia Charles (Brigham & Women's Hospital, Rheumatology) addressed the question as to how can we translate between zebrafish and mammalian models to specifically address problems of skeletal biology. Using an example of analysis of differential gene expression in osteoclastogenesis, she addressed her work in attempts to systematically analyze gene function in the mouse and zebrafish models. Using genomic editing in both organisms, Dr. Charles pointed to the strengths of the zebrafish

model as well as limitation in analysis methods. Towards this end, she outlined recent efforts to define specific micro-computed tomography (microCT) and experimental assays to provide robust means to look at osteoclast function, but also to support a comparative approach in which to use both vertebrate models in skeletogenesis research.

Science Slam III: Dr. Phil Salmon (Bruker, Switzerland) continued the discussion of the use of microCT technologies in the study of zebrafish skeletogenesis. Bones of commonly used laboratory fish models are a challenge for radiography. However, Dr. Salmon detailed the accuracy and variability of different metrics derived from microCT analysis showing the robustness of this technique in studying skeletal biology in fish. Unlike larval fish, analysis of adult stages is much harder to analyze long-term, as continual imaging over extended time in anesthesia is often lethal. This is a considerable difficulty as the majority of the skeleton is formed in the zebrafish during juvenile to adult stages. Mr. Brenen Wynd (University of Washington, Dept. of Orthopaedics and Sports Medicine) tackled this limitation by identifying a dynamic perfusion technique allowing prolonged anesthesia and imaging in adult zebrafish for up to 8 hours. This finding enhances the strength of imaging to extend from larval stages through adults allowing for in depth and unparalleled visualization of skeletogenesis in vertebrates.

Oral Session IV - Translational Approaches: Tankside to Bedside

Zebrafish and medaka are frequently being used to address the function of candidate genes identified in genetic analyses of many disorders and disease. In the last keynote talk, Dr. Matthew Harris (Boston Children's Hospital, Harvard Medical School) led off the oral session addressing how comparative work in fishes can provide a useful foundation to understand not only potential causes of gene dysfunction in the etiology of disease but also how it can promote a broader understanding of the plasticity within the developing skeleton. Using examples from the work in his lab on microcephaly and PIK3CA-mediated skeletal overgrowth, he addressed how fish models are revealing novel insight

to how disorders affecting skeletal form are manifest. Ms. Charlotte Gistelink (Ghent University, Belgium, Center for Medical Genetics) presented her work in understanding the molecular basis of collagenopathies, specifically mutations in PLOD2 underlying osteogenesis imperfecta. She presented detailed anatomical analyses of a loss-of-function *plod2* zebrafish mutant demonstrating the zebrafish accurately recapitulated the clinical phenotypes of patients with Bruck syndrome.

The discussion was followed by Dr. Ronald Kwon (University of Washington, Dept. of Orthopaedics and Sports Medicine) who presented his work comparing transcriptional programs of fish and mammal skeletogenesis by assessing shared gene expression profiles during bone formation. Dr. Kwon discussed his current work in systematic expression profiling of zebrafish and rat bone to identify homologous expression modules and their variation during the process of bone regeneration. Future work of this methodology can help establish concordance of zebrafish mutant as models of specific disease as well as establish mechanistic hypotheses for etiology.

Science Slam IV: Dr. Kristen Gorman (Université de Montreal, Musculoskeletal Diseases and Rehabilitation) led off the final oral poster session by discussing her analysis of idiopathic scoliosis using genetic analysis of spontaneous mutants identified in the guppy and medaka. Comparison between structural defects in these models and that of idiopathic scoliosis indicates similar pathologies. Overlaying genes linked to scoliotic phenotypes of these mutants with identified genetic changes in a novel cohort of patients with idiopathic scoliosis refined a set of candidate signaling mechanisms underlying this skeletal deformity. Next, Mr. Adrian Monstad-Rios (University of Washington, Dept. of Orthopaedics and Sports Medicine) discussed his work capitalizing on the utility of adult zebrafish fin regeneration as a means to systematically screen for chemical compounds for bioactive reagents affecting skeletogenesis. Through creation of a novel dosing chamber, Mr. Monstad-Rios showed efficient strategies that allowed for sensitive analysis of the effect of

small molecules on fin regeneration. Mr. Joseph Saelens (Duke University, Molecular Genetics) followed describing his work modeling *mycobacterium tuberculosis* bone infections in the zebrafish. He demonstrated efficiency of *M. tuberculosis* infection and the generation of an *in vivo* model to study the progression of colonization. Lastly, Dr. Simon Tang (Washington University, Dept. of Orthopaedics) detailed a unique model to look at age-related osteoporosis and spinal deformation in the short lived Turquoise Killifish, *Nothobranchius fuzerii*. This naturally-short lived fish shows progressive deterioration of the vertebrate that presents an interesting model comparable to vertebral defects in older people.

Future Prospects

The FishBone workshop was successful in starting a dialogue. Not only among researchers focused on fish skeletal biology, but also with those new to these models. The presentations and discussions were important to herald the attributes of fishes that make them such powerful and intriguing models for comparative research in skeletal biology - but also to acknowledge those areas in which are potentially limiting or need more refinement. As an initial meeting, it was a grand success. Future integrative meetings will need to continue promoting efforts to effectively integrate fish models such that the findings in these experimental systems can be easily put in context with broader vertebrate skeletogenesis on the whole. Success of such integration will allow efficient, and accurate, analysis of cross-species analysis in efforts to test gene function and creation of disease models.

Acknowledgements

This workshop was supported by the University of Washington Orthopaedics and Sports Medicine, Skretting, Bruker, R&D Aquatics, and Cryogenetics Inc. The scientific organizing committee consisted of Drs. David Karasik, Ronald Kwon, and Matthew Harris.

*Department of Orthopaedic Research, Boston Children's Hospital; Department of Genetics, Harvard Medical School.

Skeletal Defects In Mice With Mesenchyme-Specific Deletion Of The Entire ESET Histone Methyltransferase Protein

Liu Yang, PhD, Albert O. Gee, MD, John W. McCornack, BS, and Howard A. Chansky, MD

The ESET protein contains a C-terminal SET domain to catalyze methylation of histone H3 at lysine 9 (H3-K9) and an N-terminal tudor domain for interaction with other epigenetic enzymes. Since conventional knockout of exon 4 (eliminating the entire ESET protein) causes early embryonic lethality at the implantation stage in mice, we have generated a conditional ESET allele by flanking the exon 4 with two loxP sites. Mating with Prx1-Cre mice and analysis of the resultant embryos revealed that mesenchyme-specific knockout of exon 4 results in a frame-shift mutation that has profound defects in both the flat bones and long bones. In addition, exon 4-deletion also causes accelerated hypertrophy of growth plate chondrocytes. These findings demonstrate that both the intrinsic histone methyltransferase activity of ESET and its protein-interacting tudor domain are both important to the control of chondrocyte hypertrophy and skeletal development.

Introduction

Mouse ESET (an ERG-interacting protein with a SET domain) was originally cloned by our group and shown to methylate histone H3 at lysine 9 [1]. ESET protein is encoded by a single copy gene that is evolutionarily conserved and ubiquitously expressed. Mouse ESET is 36 kb in length and consists of 22 exons, giving rise to a full-length ESET protein with 1307 amino acids (Figure 1a, top). In addition to the catalytic SET domain, the N-terminal tudor domain of ESET protein interacts with other histone enzyme complexes such as mSin3-HDAC1/2 [2].

We previously studied deletion of the catalytic SET domain from ESET protein through deletion of exons 15-16 [3], and we are also interested in whether deletion of the entire ESET protein gives a similar phenotype. Since deletion of exon 4 results in a frame shift mutation that eliminates the entire ESET protein, and conventional knockout of exon 4 results in embryonic lethality around the stage of implantation, we generated a conditional ESET allele in which exon 4 is flanked by two LoxP sites (Figure 1a). To examine the effects of conditional ESET knockout on skeletal development, we used Prx1-Cre mice as the deleter strain to drive mesenchymal cell-specific Cre expression. At embryonic stage E9.5, Cre activity first appears in the forelimb mesenchyme, followed by appearance in the hind limb bud within one day. By E16.5, Cre is uniformly active in the limb

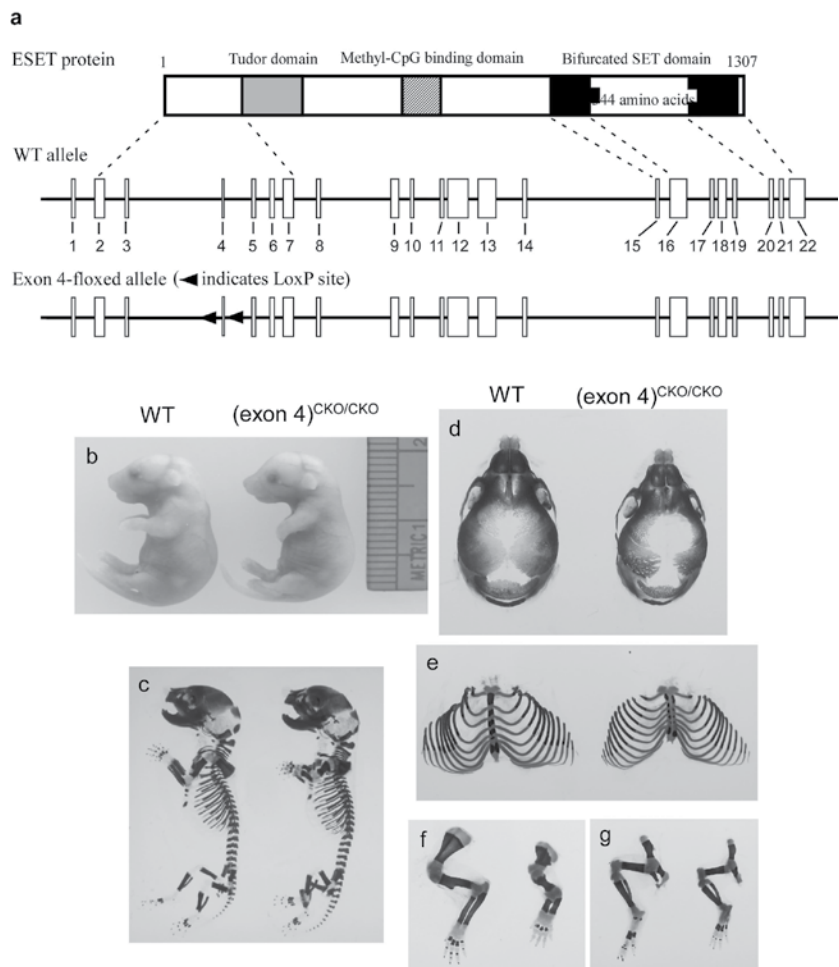


Figure 1: Skeletal defects in E18.5 mouse embryos harboring mesenchymal cell-specific deletion of ESET exon 4. a, diagrams of ESET protein domains, gene structure and exon 4-floxed allele. b, photograph of E18.5 wild-type embryo and (exon 4)^{CKO/CKO} mutants. c, newborn skeletal preparations were stained with alizarin red for comparison of bone elements. Double staining with alizarin red (bone) and alcian blue (cartilage) was carried out for calvaria (d), rib cages (e), forelimbs (f) and hind limbs (g). Genotypes of the embryos are indicated on the top.

buds, the interlimb flank mesoderm and in a subset of craniofacial mesenchyme while sparing the sclerotome mesoderm which gives rise to the vertebrae and ribs [4].

Materials and Methods

Generation of conditional ESET-null mice --- Mice harboring the ESET(exon 4)^{Flox} allele were generated from the European Mouse Mutant Archive strain B6NDnk;B6N-Setdb1<tm1a(EUCOMM)Wtsi>/leg. Prx1-Cre mice were obtained from the Jackson Laboratory. Mouse embryos were fixed in 4% paraformaldehyde overnight, decalcified in 14% EDTA for at least 24 hrs before further treatments for embedding. Immunohistostaining was carried out with a rabbit polyclonal anti-type X collagen antibody. Alizarin red and alcian blue staining were performed as described [3].

Results

Our repeated attempts at mating ESET(exon 4)^{Flox/WT} and ESET(exon 4)^{Flox/WT}; Prx1-Cre failed to produce viable ESET(exon 4)^{Flox/Flox}; Prx1-Cre newborn pups. Post mortem examination indicated that these mutant mice died shortly after birth due to respiratory failure. To circumvent this problem, we carried out a timed mating experiment and analyzed embryos at the E18.5 stage (one day before birth). DNA analysis of more than 80 embryos revealed that distribution of various possible genotypes largely followed the Mendelian ratio among these embryos. ESET(exon 4)^{Flox/Flox}; Prx1-Cre embryos, referred to as (exon 4)^{CKO/CKO}, were slightly smaller than wild-type littermates but easily recognizable due to their shortened forelimbs (Figure 1b). In whole mount skeletons stained with alizarin red (for bone), none of the skeletal elements were missing from (exon 4)^{CKO/CKO} embryos (Figure 1c). For a better comparison between wild-type and mutants, additional embryos were doubled stained with alizarin red and alcian blue (for cartilage). Examination of the mutant skeleton revealed that the frame shift mutation downstream of exon 4 had led to significant widening of the sagittal suture of the skull, delayed ossification of the sternum and a wider-than normal xiphoid process, deformed scapulae, shortened digits and forelimbs, as well as lack of the deltoid tuberosity (Figure 1d-f). While

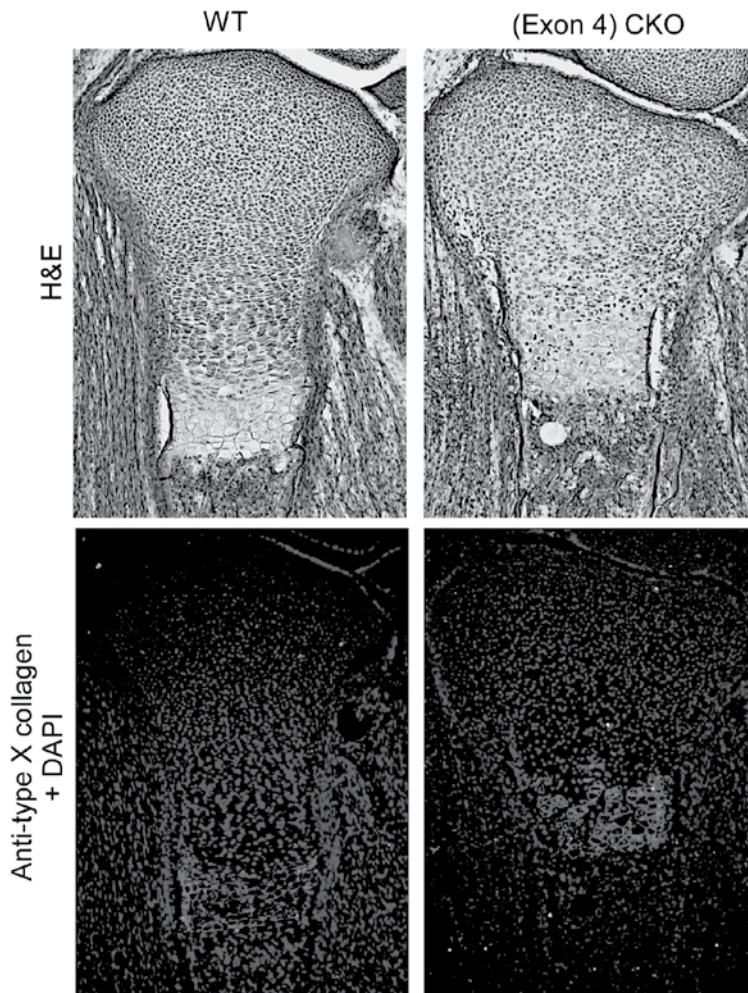


Figure 2: Accelerated expression of type X collagen in (exon 4)^{CKO/CKO} embryos. Growth plates in proximal tibia from E18.5 embryos were stained with H&E to show morphology (top panels), and with an antibody against type X collagen to show hypertrophic chondrocytes (bottom panels). DAPI was used to stain nuclei. Note that type X collagen-positive hypertrophic zone is significantly further away from the knee joint in wild-type embryos than the type X collagen-positive hypertrophic zone in (exon 4)^{CKO/CKO} mutants.

hind limbs of (exon 4)^{CKO/CKO} embryos did not show overt signs of gross defects, they were slightly smaller than those of wild-type littermates (Figure 1g).

Flat bones of the skull are formed through intramembranous ossification whereby mesenchymal stem cells directly differentiate into osteoblasts. In contrast, formation of the long bones occurs through endochondral ossification, a process that requires formation of growth plates by chondrocytes in different stages of differentiation. To investigate how deletion of ESET in mesenchymal cells affects endochondral ossification, we carried out immunohistostaining for type X collagen (a specific marker for hypertrophic chondrocytes) in the

developing long bones in embryos. At embryonic stage E18.5, as shown in Figure 2, type X collagen-positive hypertrophic chondrocytes were restricted within the well-defined hypertrophic zone in wild-type embryos, whereas type X collagen-positive hypertrophic cells in (exon 4)^{CKO/CKO} mice were significantly advanced and much closer to the articular joint. These are clear signs of accelerated hypertrophic differentiation of chondrocytes.

Discussion

In this study we have demonstrated that deletion of the entire H3-K9 histone methyltransferase ESET (through deletion of exon 4) disrupts the tightly regulated control of hypertrophic differentiation of growth

plate chondrocytes, and provided clear in vivo evidence that embryonic development of the skeletal system requires the H3-K9 methyltransferase activity of ESET protein. Skeletal defects caused by exon 4 deletion are similar to mutants with deletion of exons 15-16, but phenotypes associated with exon 4 deletion are more severe as evidenced by the fact that (exon 4) ^{CKO/CKO} newborns are not viable. Since ESET protein is both an H3-K9 methyltransferase and a platform to recruit other chromatin modification enzymes in growth plate chondrocytes, it has the potential to fine tune the potency of other key regulators of growth plates such as the Runx2-HDAC4 pair [3]. As ESET expression itself could be regulated by different extracellular stimuli, we believe that ESET plays a critical role in the control of an orderly process of endochondral bone formation.

References

1. Yang, L. et al. Molecular cloning of ESET, a novel histone H3-specific methyltransferase that interacts with ERG transcription factor. *Oncogene* 21, 148-152 (2002)
2. Yang, L. et al (2003). An ERG (ets-related gene)-associated histone methyltransferase interacts with histone deacetylases 1/2 and transcription co-repressors mSin3A/B. *Biochem J* 369, 651-657 (2003)
3. Yang, L. et al. ESET histone methyltransferase is essential to hypertrophic differentiation of growth plate chondrocytes and formation of epiphyseal plates. *Dev. Biol.* 380, 99–110 (2013).
4. Logan, M., et al. Expression of Cre Recombinase in the developing mouse limb bud driven by a Prxl enhancer. *Genesis* 33, 77-80 (2002)

The background features a large, light gray watermark of the University of Washington Orthopaedics & Sports Medicine logo. The logo is circular and contains the text "UNIVERSITY OF WASHINGTON" at the top, "ORTHOPAEDICS & SPORTS MEDICINE" at the bottom, and a central emblem depicting a tree and a building.

Clinical Science Articles

“Our doubts are traitors, and make us
lose the good we oft might win, by
fearing to attempt..”

— William Shakespeare

Prospective Comparison Of Patient-Reported Evaluation And Objective Measurement Of Shoulder Function

Jason E. Hsu, MD, Anna Tang, BS, and Frederick A. Matsen III, MD

Background

Surgeons and clinical investigators need tools for assessing the functional status of shoulders before and after treatment. The absence of practical and efficient tools that are applied routinely leaves surgeons without reliable knowledge of the effectiveness of their treatment efforts. Some outcome methods are referred to as 'subjective' because they rely on the interpretation of shoulder function by the patient. Others are referred to as 'objective' in that surgeons or their designees make measurements of passive motion, active motion, or strength. In the selection of a practical preoperative and postoperative assessment approach that is useful for routine clinical practice as well as for research, it is important to understand the relationship between patient-reported function on one hand and the objective measurement of function on the other. This study tested the hypothesis that patient self-assessed shoulder function was closely, but incompletely, related to objective

measurements of active shoulder motion.

Methods

We prospectively evaluated 49 consecutive consenting patients (age 62 ± 10 years, 65% male) who presented to our Shoulder and Elbow service for elective shoulder arthroplasty. Patients completed the Simple Shoulder Test (SST) self-assessment of their ability to perform twelve shoulder functions for both the intended arthroplasty shoulder and the contralateral shoulder. At the same clinic visit, the active range of motion of each shoulder was measured using a Kinect sensor. The ranges of active shoulder abduction, flexion and cross body adduction were correlated with the overall SST score and the correlation coefficients calculated. The ranges of motion were then determined for the shoulders that were able and those that were unable to perform each of the twelve individual functions of the SST.

Results

There was a strong correlation between the total number of SST functions performable by each shoulder and the active range of abduction ($R = .834$, R squared = $.696$) (Figure 1). The correlation was not as strong between the total number of SST functions and the range of active flexion ($R = .729$, R squared = 0.531) or the range of active cross body adduction ($R = .557$, R squared = $.310$). The percentage of these shoulders able to perform each of the twelve SST functions ranged from 32% for throwing 20 yards overhand to 76% for comfort at rest by the side (Figure 2). More demanding shoulder functions (such as throwing) tended to be associated with greater average range of shoulder abduction. The average active abduction range for shoulders unable to perform each of the 12 SST functions was typically less than 85 degrees in comparison to the more than 120 degree abduction range typical of the shoulders able to perform the function. The difference in active

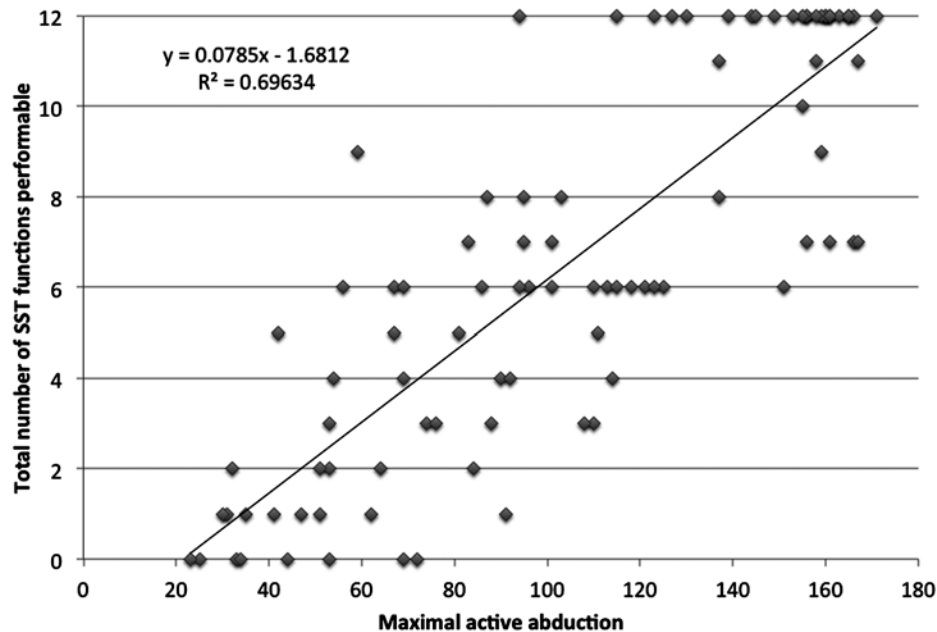


Figure 1: A strong correlation between the total number of SST functions performable by each shoulder and the active range of abduction.

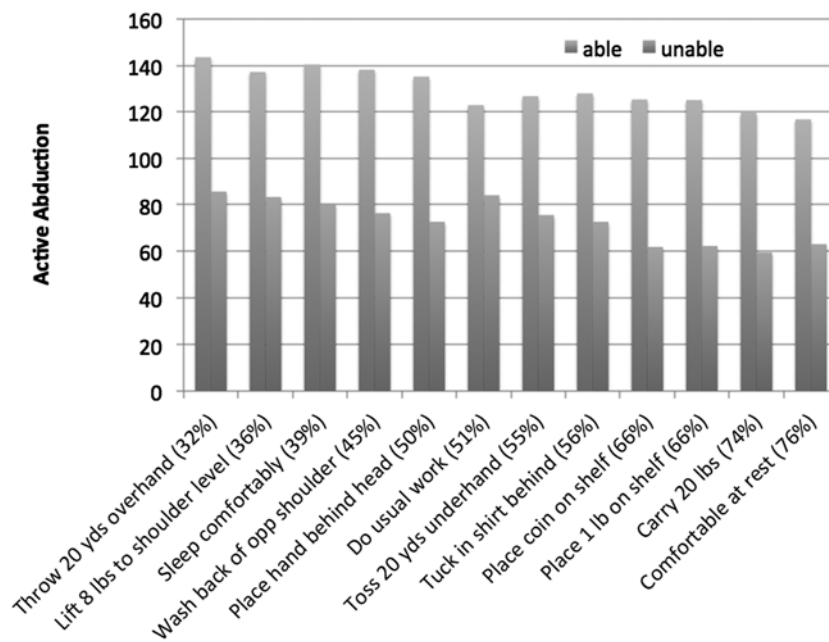


Figure 2: The percentage of these shoulders able to perform each of the twelve SST functions ranged from 32% for throwing 20 yards overhand to 76% for comfort at rest by the side.

range of abduction between shoulders able and those unable to perform each of the functions of the SST was highly significant ($p < .00001$ for each). The Kinect was not effective in measuring the range of rotation in shoulders that could not be abducted to 90 degrees, so that we were unable to evaluate the relationship of rotational motion to shoulder function.

Conclusion

This study documented a close relationship between self-assessed function and objective measurement of motion: the range of active abduction was associated with 70% of the variance in the number of SST functions performable. More demanding functions, such as throwing overhand, were associated with greater active abduction than less demanding functions, such as carrying 20 pounds at the side. There is a highly significant, but incomplete correlation between patient self-assessed function and objectively measured active range of motion. This suggests that an efficient and practical approach to the routine clinical assessment of shoulder function might be the combination of a brief patient questionnaire, such as the SST, and the measurement of an active motion, such as abduction.

Single Stage Revision For Failed Shoulder Arthroplasty With Positive Cultures For Propionibacterium

Jason E. Hsu, MD, Jacob D. Gorbaty, BA, Ian J. Whitney, MD,
and Frederick A. Matsen III, MD

Background

A significant number of revision shoulder arthroplasties performed for pain, stiffness, and loosening are associated with positive *Propionibacterium* cultures. Due to the low virulence of this bacteria, periprosthetic shoulder infections do not present with classic signs of infection such as erythema and wound drainage but rather with pain, stiffness, and component loosening, often long after index arthroplasty. Typical pre-operative and intra-operative signs and symptoms are lacking, and often the presence of bacteria is not known until weeks after the revision surgery. Because no point of care technique for identifying these low-virulent organisms exists at the time of revision surgery, the surgeon is faced with the difficult decision of whether to treat these revision as “infected” or not. Given that 40-50% of revision shoulder arthroplasties will be associated with positive cultures, the safest course may be to treat all patients as if bacteria were present. While some surgeons advocate a two-stage revision in cases suspicious for low grade infection, our practice is to treat these patients with complete prosthetic exchange and antibiotics until negative cultures are confirmed. The objective of this study

was to present the minimum two-year clinical outcomes of this approach by comparing revisions with positive cultures to a control group.

Methods

A standardized specimen collection protocol was utilized, with a minimum of five cultures from explants and tissue from each shoulder. All patients were treated with a one stage revision. Specimens were held for a minimum of 21 days. All patients having revision arthroplasty were placed onto one of two initial postoperative antibiotic protocols based on the surgeon’s index of suspicion for infection. In cases where there was a high index of suspicion, the patient was maintained on IV antibiotics. If the cultures were negative at three weeks, all antibiotics were discontinued. In cases where there was a low index of suspicion for infection, patients were placed on oral antibiotics until either cultures were negative at 21 days or until cultures became significantly positive. With either initial postoperative protocol, if two or more cultures became positive, intravenous antibiotics were administered through a peripherally inserted central catheter for 6 weeks followed by oral antibiotics for a minimum of 6 months. Demographic,

pre-operative Simple Shoulder Test (SST), and post-operative SST, Single Assessment Numeric Evaluation (SANE), and VAS pain scores were collected. Patients with two or more positive *Propionibacterium* cultures (“Positive Culture” group) were compared to patients with less than two positive *Propionibacterium* cultures (“Control” group).

Results

Demographics are summarized in Table I. The Simple Shoulder Test (SST) scores for the 26 culture-positive shoulders (88% male, age 63±7 years) improved from 3.3±2.8 before surgery to 7.9±3.3 at 46±12 months after surgery (p<0.001) - an average improvement of 53% of the maximal possible improvement. The SST scores for the 29 control shoulders (39% male, age 67±8 years) improved from 2.6±1.9 to 6.1±3.4 at an average of 50±12 months (p<0.001) - an average improvement of 37% of the maximum possible improvement. Subsequent revision for persistent pain or stiffness was required in 3 patients (12%) in the culture-positive group and 3 patients (11%) in the control group. One patient in the control group had one positive specimen out of 8 collected. Clinical

TABLE I. DEMOGRAPHICS OF COHORT

	<u>Entire cohort</u>		<u>Culture positive</u>		<u>Control</u>		<u>p-value</u>
# of patients	54		26		28		
Age	65.2 ± 7.8		63.1 ± 7.0		67.1 ± 8.1		0.056
Sex							
Male	34	63%	23	88%	11	39%	<0.001
Female	20	37%	3	12%	17	61%	
Follow-up (months)	48.0 ± 11.7		46.3 ± 11.6		49.6 ± 11.8		0.303
# of previous surgeries	1.6 ± 0.8		1.7 ± 0.9		1.5 ± 0.7		0.295
Procedure							
Conversion to hemi	34	63%	21	81%	13	46%	
Conversion to TSA	16	30%	5	19%	11	39%	
Conversion to reverse TSA	4	7%	0	0%	4	14%	

TABLE II. CLINICAL OUTCOMES

	Entire cohort (n=54)		Culture positive (n=26)		Control (n=28)		p-value
Revision surgery required	7	13%	3	12%	3	11%	1
SST pre-op	2.9	± 2.4	3.3	± 2.8	2.6	± 1.9	0.239
SST post-op	7.0	± 3.5	7.9	± 3.3	6.1	± 3.4	0.060
SST improvement	4.1	± 3.6	4.5	± 4.0	3.7	± 3.2	0.427
SANE post-op	64.0	± 24.4	65.3	± 23.3	62.8	± 25.8	0.715
VAS pain post-op	3.2	± 2.7	3.2	± 2.5	3.2	± 3.0	0.958

outcomes are summarized in Table II. Fourteen patients reported side effects to antibiotics, including gastrointestinal (9), light sensitivity (2), rash or swelling (2), and leukopenia (1).

Conclusion

At a mean of four years after revision surgery, clinical outcomes after single-stage revision for *Propionibacterium* culture-positive shoulders were at least as good as outcomes in revision procedures for control shoulders. Two-stage revision procedures may not be necessary in the management of these infections. Patients should be advised of the potential adverse effects to antibiotic administration.

Clinical Prediction Of Pyogenic Flexor Tenosynovitis From Other Infections Of The Finger – Kanavel’s Cardinal Signs

Colin D. Kennedy, MD, Alexander S. Lauder, MD, Jonathan R. Pribaz, MD,
and Stephen A. Kennedy, MD

Background: Hospital transfer decisions regarding pyogenic flexor tenosynovitis (PFT) can be made difficult by emergency department presentations similar to other finger infections, with pain, redness, and functional limitation. Our objectives were to 1) Determine diagnostic sensitivity and specificity of Kanavel signs and 2) Identify existing factors most predictive of PFT during initial presentation.

Methods: Adult patients who underwent surgical consultation for concern of PFT over a 5-year period were identified retrospectively. Bivariate screening identified clinical criteria for differentiation, and multivariate logistic regression was performed to control for confounding.

We then created a prediction algorithm for diagnosis of PFT. Receiver operating characteristic (ROC) curve analysis was used to evaluate diagnostic accuracy.

Results: Patients with PFT differed significantly from those with non-PFT finger infections in regard to the four Kanavel signs, duration of symptoms less than five days, and Erythrocyte Sedimentation Rate. Sensitivity of the Kanavel signs ranged from 91.4% to 97.1%. Specificity ranged from 51.3% to 69.2%. Logistic regression identified independent predictors for PFT as tenderness along the flexor tendon sheath, pain with passive extension, and duration of symptoms less than five days. A prediction algorithm incorporating these 3 factors showed an area under the ROC curve of 0.91 (0.840-0.979 95% CI).

Conclusions: Kanavel’s signs have high sensitivity for detecting PFT but have poor specificity on an individual basis. Clinical prediction algorithms that combine the relevant factors may be helpful in the development of clinical prediction tools and educational materials for optimization of emergency hand care systems. Further prospective study is needed.

Introduction

Pyogenic flexor tenosynovitis (PFT) is an infection of the flexor tendon sheath of the finger that represents approximately 9.4% of hand infections [3]. (See example Figure 1). Without treatment, it may result in infectious spread, tendon necrosis, and digit devitalization [9,10]. Modern surgical management and antibiotics have reduced serious sequelae secondary to PFT, but functional outcome remains influenced by the timing of diagnosis and treatment. Differentiation of PFT from other infections such as finger abscesses and cellulitis is essential for safe and cost effective emergency hand transfer systems, but can be made difficult by similar presentations of pain, redness, and functional limitation [9,10].

In 1912, Dr. Allen B. Kanavel described three cardinal signs of PFT: (1) exquisite tenderness over the course of the sheath, (2) flexion posture of the finger, and (3) exquisite pain on extending the finger [4]. He noted also “the whole of the involved finger is uniformly swollen,” which later became a fourth cardinal sign: fusiform swelling [4,5]. Despite the

lack of systematic validation for their use, these four Kanavel signs have

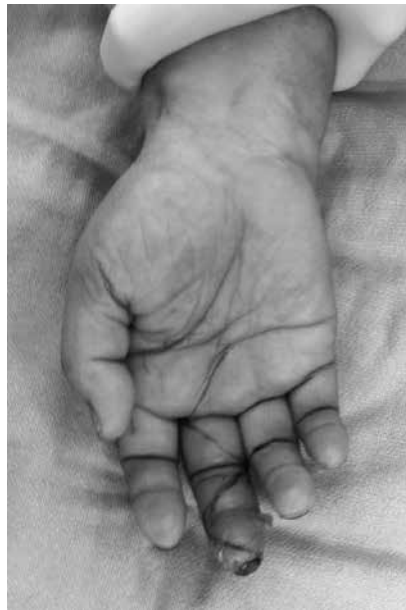

Figure 1: Example of advanced case of pyogenic flexor tenosynovitis. Note the flexed posture and uniform swelling of the middle finger (fusiform swelling). There is also finger tip necrosis, with blackening of the most distal tip of the finger. This finger was exquisitely painful to passive extension and palpation along the tendon sheath. (Photo credit Mary Claire Manske, MD)

remained the primary diagnostic tool for PFT [6]. There are differing opinions in the literature regarding which Kanavel signs are more suggestive of a PFT diagnosis than others [1, 7-8]. Moreover, additional variables independent of the cardinal signs are yet to be identified.

Better understanding of features that differentiate PFT from other finger infections can aid development of optimal emergency hand care systems. The purpose of this study is to (1) determine the diagnostic accuracy of the four Kanavel Signs, and (2) identify existing clinical and laboratory criteria for differentiating between PFT and abscess/cellulitis of the finger for adults presenting to the emergency department. We also aimed to develop an evidence-based clinical prediction algorithm for future validation.

Materials and Methods

Institutional Review Board approval was obtained for this retrospective review and the authors adhered to the STROBE (Strengthening the Reporting of Observational studies in Epidemiology) guidelines. Our institutional coding database was

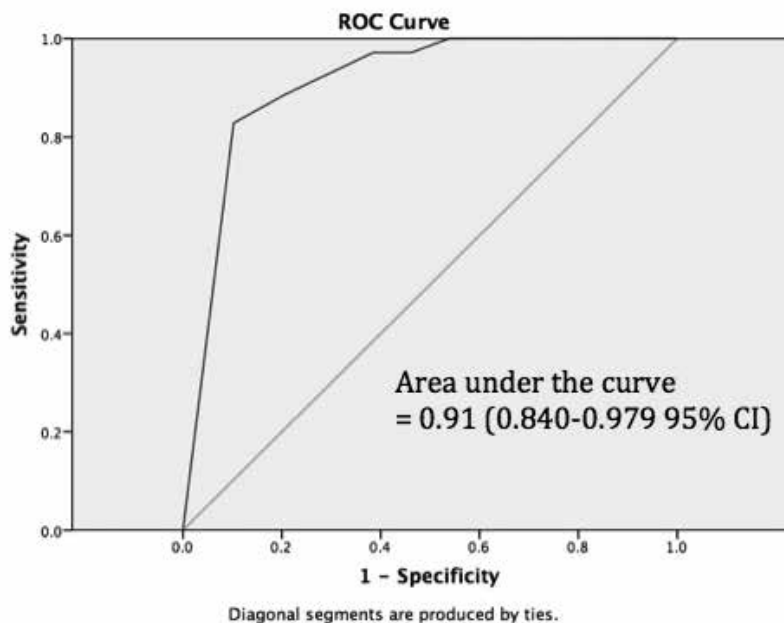


Figure 2: ROC Curve of Clinical Prediction Tool developed from the study.

queried to identify all patients with a finger infection referred to hand surgery consultation at a large academic medical center during a 5-year period from September 26, 2008 to September 26, 2013. Diagnoses included tenosynovitis, felon, paronychia, abscess, cellulitis, or other non-specified infection of digits. Patient medical record numbers were retrieved from this query to create a de-identified research database on a secured password-protected file. A medical chart review was performed to verify that patients met inclusion criteria for the study and to divide patients into a PFT group and a group with other infections (i.e. “non-PFT group”).

Study Population and Inclusion Criteria

Ninety-eight patients were identified for analysis. After exclusion of 20 patients with incomplete recordings of Kanavel signs and 4 pediatric patients, 74 patients were analyzed. Patient characteristics are displayed in Table 1. All adult patients were included in the study if there was hand surgery consultation, entirety of treatment at our institution, and complete medical records.

PFT was diagnosed with visible infection in the flexor tendon sheath upon surgical drainage (purulence and/or fluid discoloration) or with culture growth from flexor tendon sheath fluid collected operatively. Otherwise, all

cases that did not meet these criteria were classified as the absence of confirmed PFT (non-PFT). Patients treated outside of the operative theater with either bedside drainage or antibiotic management alone were excluded from the diagnosis of PFT. Exclusion criteria were patients younger than 18 years of age, those who had incomplete operative findings regarding definitive diagnosis, or incomplete records.

Data Collection

The following data were collected from the medical record of each patient: patient demographics (age, sex, smoking status, history of IVDU), pertinent history (reported fevers, duration of symptoms from onset to presentation), presence and type of penetrating trauma (cat bite, dog bite, human bite, thorn, splinter, nail, glass, crush, injection), pre-operative serum laboratory studies that are routinely obtained in patients with concern for a hand infection and are utilized in other infection prediction algorithms (white blood cell count, C-reactive protein, erythrocyte sedimentation rate, sodium level) [11], presence of each of Kanavel signs (tenderness along the flexor tendon sheath, fusiform swelling, digit resting in flexed position, pain with passive extension of the digit), and operative or microbiological findings confirming or excluding a diagnosis of PFT.

Analysis and Study Groups

Study groups were (1) PFT as defined above, or (2) non-PFT diagnosis that included cellulitis or abscess not communicating with the flexor tendon sheath. Statistical analysis was done with the assistance of a biomedical statistician. IBM SPSS version 19.0.0.2 (Armonk, NY) was used. Descriptive statistics were completed with two-sample Student t-test for comparison of means, and Fisher’s Exact test for proportions. The sensitivity, specificity, and positive predictive value of the various clinical features were calculated.

To identify clinical predictors, bivariate analysis was performed with the use of two-sample Student t-test for continuous variables between the PFT group and the non-PFT group (abscess and cellulitis). The distribution of continuous variables between the two groups was evaluated using scatter diagrams, and Receiver Operating Characteristic (ROC) curves were constructed to develop binary cut-off values for use in clinical prediction algorithms.

Logistic regression was then used to control for confounding and model potential relationships identified by the screening bivariate comparison. Variables with a P value of less than 0.20 in the bivariate screening analysis were chosen as candidates for the multivariate model. Adjusted odds ratios with ninety-five percent confidence intervals were calculated.

We used the relevant predictors from the multivariate analysis to determine likelihood ratios and construct a prediction algorithm for the diagnosis of PFT.

Results

Patient characteristics and presenting exam findings are shown in Table 1. No significant difference between groups was found with regard to age, sex, pain, animal bite mechanism, serum WBC count, CRP level, sodium level, IVDU status, or history of subjective fever.

Significant differences were noted in regard to the four Kanavel signs. Other differences between the PFT and non-PFT groups included the rate of penetrating trauma, tobacco use, duration of symptoms in days prior to presentation, and ESR level at hospital presentation. Scatter diagrams were performed for continuous variables

	Group		P-value	Statistical Test
	PFT (N=35)	Other digit infection (N=39)		
Age (N=35+39)	44.3 yrs	45.4 yrs	0.745	Independent Samples T-test
Male Sex	24/35 (69%)	27/39 (69%)	1.000	Fisher's exact test
Tender to palpation of tendon sheath	32/35 (91%)	12/39 (31%)	<0.001	Fisher's exact test
Pain with passive extension	34/35 (97%)	18/39 (46%)	<0.001	Fisher's exact test
Flexed posture of the digit	32/35 (91%)	19/39 (49%)	<0.001	Fisher's exact test
Fusiform swelling of the digit	33/35 (94%)	19/39 (49%)	<0.001	Fisher's exact test
Presence of penetrating trauma	26/35 (74%)	20/39 (51%)	0.056	Fisher's exact test
Tobacco Use	12/35 (34%)	23/39 (59%)	0.039	Fisher's exact test
Duration of symptoms in days	2.8 +/- 2.3	6.2 +/- 11.6	0.097	Independent Sample T-test
Pain /10	7.85 +/- 2.2	7.56 +/- 3.0	0.65	Independent Samples T-test
Animal bite	6/35 (17%)	5/39 (13%)	0.747	Fisher's exact test
WBC	13.1 +/- 8.9	10.8 +/- 4.5	0.16	Independent Samples T-test
ESR	22.3 +/- 21.3	38.0 +/- 32.9	0.027	Independent Samples T-test
CRP	46.4 +/- 63	71.0 +/- 77	0.17	Independent Samples T-test
Na	136 +/- 2	136 +/- 3	0.33	Independent Samples T-test
IVDU	5/35	9/38	0.380	Fisher's exact test
Subjective fevers	11/33	7/39	0.175	Fisher's exact test

Table 1: Patient characteristics, with comparison between groups and bivariate screening for differentiating factors.

Sensitivity	Sensitivity	Specificity	PPV
Passive extension pain	97.1%	53.8%	65.4%
TTP Sheath	91.4%	69.2%	72.7%
Held in flexion	91.4%	51.3%	62.7%
Fusiform swelling	94.3%	51.3%	63.5%

Table 2: Sensitivity, Specificity and Positive Predictive Value of Kanavel Signs.

Multivariate predictor	Regression coefficient	Likelihood ratio	P value	Adjusted Odds Ratio	Ninety-Five Percent Confidence Intervals
Pain with extension	3.36	1.89	0.005	28.9	2.8 - 300
Tenderness of the flexor tendon sheath	3.00	2.67	<0.001	20.0	3.9 - 103
Duration less than 5 days	2.81	1.38	0.004	16.6	2.4 - 114

Table 3: Results of the multivariate analysis for the three independent predictors of pyogenic flexor tenosynovitis in the model.

with significant differences ($P < 0.05$). Based on ROC curve analysis and Youden's index, the selected cutoff for

the duration of symptoms was 5 days (i.e. PFT was more likely to be present if onset of symptoms was < 5 days from

presentation). For the ESR, a measure of < 19 mm/hour was associated with PFT. These cut-off values were then used for the multivariate regression.

The sensitivity, specificity, and positive predictive value Kanavel signs each showed sensitivities ranging from 91.4% to 97.1% for detection of PFT, and had specificity ranging from 51.3% to 69.2% (Table 2). Positive predictive values were in the range of 62.7% to 72.7%.

Multivariate regression was performed to reduce confounding and model potential relationships. Three independent predictors of PFT were identified: 1) tenderness along the flexor tendon sheath, 2) pain with passive extension, and 3) duration of symptoms less than five days. The Hosmer-Lemeshow goodness-of-fit test revealed no significant departure from good model fit ($p = 0.996$). The other two Kanavel signs, flexion posture of the digit and fusiform swelling, did not appear to be independently predictive within the model. ESR similarly did not contribute significantly to the prediction model. Regression coefficients, likelihood ratios, P values, adjusted odds ratios, and 95 percent confidence intervals are presented in Table 3.

Using the three binary independent predictors identified by the multivariate regression, a total of eight combinations are possible ($2 \times 2 \times 2$, presented in Table 4). The probability of diagnosis PFT increased with the number of predictive variables present. A patient with all three factors present was 87.9% likely to have PFT, whereas a patient with no factors present was 0% likely to have PFT. The ROC curve for the prediction algorithm is presented in Figure 2. A prediction algorithm incorporating these 3 factors showed an area under the ROC curve of 0.91 (0.840-0.979 95% CI). Each variable was similar in regard to predictive value, so a simplified clinical algorithm was constructed based on the number of predictive variables and is presented in Table 5.

Discussion

Kanavel's four cardinal signs have contributed greatly to our ability to diagnose pyogenic flexor tenosynovitis, despite the lack of formal validation studies. Many hand surgeons "know it when they see it." However, decisions regarding management can be made

Multivariate Predictor			
Pain with extension	Tenderness of the flexor tendon sheath	Duration less than 5 days	Predicted probability of flexor tenosynovitis
Yes	Yes	Yes	87.9%
Yes	Yes	No	33.3%
Yes	No	Yes	30.0%
No	Yes	Yes	25.0%
Yes	No	No	0.0%
No	Yes	No	0.0%
No	No	Yes	0.0%
No	No	No	0.0%

Table 4: Predicted probability of pyogenic flexor tenosynovitis for the eight various combinations of the three independent predictive factors (2x2x2).

Number of predictors	Flexor tenosynovitis (N=35)	Other infection (abscess, cellulitis, etc) (N=39)	Predicted probability of flexor tenosynovitis
3	29 (82.9%)	4 (10.3%)	87.9%
2	6 (17.1%)	14 (35.9%)	30.0%
1	0 (0%)	14 (35.9%)	0.0%
0	0 (0%)	7 (17.9%)	0.0%

Table 5: Simplified algorithm for the predicted probability of flexor tenosynovitis.

difficult when other providers are performing the examination, findings are overlapping or inconsistent, and/or decisions for transfer can significantly increase the cost of care. In this retrospective study, we aimed to evaluate the sensitivity and specificity of the Kanavel signs, and identify any features that best predict PFT and differentiate it from other digit infections, to help develop evidence-based algorithms and optimize care. We found that Kanavel's signs have high sensitivity for detecting PFT, but individually have poor specificity. Identifying the independently significant predictors and combining them with clinical prediction algorithms improves the diagnostic accuracy.

Kanavel described excessive tenderness along the tendon sheath as the most important cardinal sign [4], and our analysis concurred with this finding. We found that tenderness to the flexor

tendon sheath and pain with passive extension are independent predictors of PFT. Flexion posture and fusiform swelling, although frequently present in patients with the condition, do not appear to independently differentiate it from other finger infections. Symptom duration less than five days may be an independent predictor of PFT, but further studies are needed to evaluate whether this might be a spurious result from our population sample or a true independent predictor. Kanavel's four cardinal signs should not themselves be used as a clinical prediction rule, as doing so assumes that each Kanavel sign is independently significant and that each Kanavel sign is equal to another in terms of diagnostic utility. Based on our results, this is not the case.

Our initial bivariate comparison also showed that PFT patients had lower ESR levels at hospital presentation

than non-PFT patients. However, when incorporated into the logistic regression analysis, ESR level did not contribute significantly to the prediction model. ESR is inconsistently obtained in the evaluation of acute finger infection, and is more often used as a mid- to long-term marker of inflammation, so a low ESR in patients with acute PFT infections may simply be due to short duration of symptoms and relatively small area of infection. It may be worthy of more study, but we expect that ESR level is unlikely to be of significant utility in a PFT prediction model.

Although we found that fusiform swelling was not of high diagnostic utility, Pang et al. analyzed 75 patients with PFT and found that of the Kanavel signs, fusiform swelling was the most sensitive sign and was present in 97% of patients [8]. Semi-flexed posture was found in 69% of patients, pain on passive extension in 72%, and tenderness along the flexor sheath in 64% of patients. They devised a three-tier classification system of PFT based on preoperative clinical assessment and identified preoperative risk factors associated with worse outcomes and higher risk of amputation. They found that tenderness along the tendon sheath was a late sign of proximal extension, suggesting that the lack of this Kanavel sign should not exclude a diagnosis of PFT.

Neviasser and Gunther found that the inability to flex the finger to touch the palm was an additional sign of PFT, and suggested that the most reliable early Kanavel sign is pain on passive extension of the digit [7]. Dailiana et al. performed a retrospective review of 41 patients with PFT and found that only 54% of patients demonstrated all four signs [1]. They noted that all patients in their series had tenderness along the tendon sheath and pain with passive extension. These studies illustrate the discord in published literature regarding the reliability of Kanavel's Signs in predicting PFT.

Limitations of the present study include its retrospective design and use of institutional coding for the identification of patients. This increases the risks of bias in regard to patient selection and documentation, and limits the ability to identify new clinical criteria that could be used to accurately and efficiently diagnose PFT. Surgical and microbiological findings were used to

confirm a diagnosis of PFT, which may lead to under-diagnosis of the PFT group. Patients with early PFT may not develop visible infection, and antibiotics may alter culture growth. Patients who were treated with antibiotics alone or with bedside irrigation and debridement in the emergency department were not included in this study. Thus, a subset of patients that may have had PFT were also not included in the study. There is also subjectivity and intra- and inter- observer variation with physical exam findings such as fusiform swelling or tenderness localized to the flexor tendon sheath. These variations may cause inaccuracy defining the presence or absence of each finding.

Despite these limitations, we feel that this study provides valuable information worthy of future validation and prospective study. Our study validates the Kanavel signs as a sensitive tool for evaluating a patient with potential PFT, but reveals their limited specificity on an individual basis. Diagnostic algorithms that combine the relevant factors may be more helpful in predicting need for hospital transfer or other treatment decisions. Future studies explicitly defining each of the Kanavel signs, such as size measurement or contralateral digit comparison for assessing fusiform swelling would be beneficial to combat limitations in inter- and intra-observer variations. Use of photography to help confirm the presence or absence of a finding in an objective manner may be helpful. Future research on this topic would be strengthened by a prospective, longitudinal design with appropriate measures of functional outcome to further determine the pre- and post-diagnostic value of predictive variables for PFT.

Conflict of Interest

The Authors declare that they have no conflict of interest.

Funding

This research received no specific grant from any funding agency in the public, commercial, or not-for-profit sectors.

References

1. Dailiana ZH, Rigopoulos N, Varitimidis S, Hantes M, Bargiotas K, Malizos KN. Purulent flexor tenosynovitis: Factors influencing the

functional outcome. *J Hand Surg Eur Vol.* 2008;33:280-285.

2. Draeger RW, Bynum DK. Flexor tendon sheath infections of the hand. *J Am Acad Ortho Surg.* 2012;20:373-382.

3. Glass KD. Factors related to the resolution of treated hand infections. *J Hand Surg.* 1982;7:388-94.

4. Kanavel AB. The symptoms, signs, and diagnosis of tenosynovitis and fascial-space abscesses. In *Infections of the Hand.* 1st ed. Philadelphia, PA: Lea & Febiger; 1912:201-226.

5. Kanavel AB. *Infections of the Hand: A Guide to the Surgical Treatment of Acute and Chronic Suppurative Processes in the Fingers, Hand and Forearm.* 7th ed. Philadelphia, PA: Lea & Febiger; 1939.

6. Kennedy CD, Huang JI, Hanel DP. In Brief: Kanavel's signs and pyogenic flexor tenosynovitis. *Clin Orthop Relat Res.* 2016;474: 280-284.

7. Neviasser RJ, Gunther SF. Tenosynovial infections in the hand: Diagnosis and management. *Instr Course Lect.* 1980;29:108-128.

8. Pang HN, Teoh LC, Yam AKT, Lee JYL, Puhaindran ME, Tan ABH. Factors affecting the prognosis of pyogenic flexor tenosynovitis. *J Bone Joint Surg Am.* 2007;89:1742-1748.

9. Stern PJ, Staneck JL, McDonough JJ, Neale HW, Tyler G. Established hand infections: a controlled, prospective study. *J Hand Surg.* 1983;8:553-559.

10. Stevanovic MV, Sharpe F. Acute Infections. In: Wolfe SW, Hotchkiss RN, Pederson WC, and Kozin SH eds. *Green's operative hand surgery.* 6th ed. Philadelphia, PA: Elsevier Churchill Livingstone; 2011:53-57.

11. Wong CH, Khin LW, Heng KS, Tan KC, Low CO. The LRINEC (Laboratory Risk Indicator for Necrotizing Fasciitis) score: a tool for distinguishing necrotizing fasciitis from other soft tissue infections. *Crit Care Med.* 2004;32: 1535-1541.

Impaction Autografting: Bone-Preserving, Secure Fixation Of A Standard Humeral Component Without Ingrowth Or Cement

Robert M. Lucas, MD, Jason E. Hsu, MD, Albert O. Gee, MD,
Moni Blazej Neradilek, MS, and Frederick A. Matsen III, MD

Background

The intramedullary anatomy of the humerus varies widely among patients. In an individual shoulder the variable endosteal cross sectional anatomy of the humerus cannot be matched by the cylindrical shape of prosthetic stems. (Figure 1). These variations create a challenge in securing the humeral component. When fixed with bone ingrowth, a tight diaphyseal press-fit or cement, the humeral component of a shoulder arthroplasty may present problems of malposition (Figure 2), stress-shielding, periprosthetic fracture or difficulty with removal at revision arthroplasty. We have avoided the need for these fixation methods by using impaction cancellous autografting of the humeral stem, minimizing contact between the prosthetic stem and the humeral cortex (Figure 3). This study presents the radiographic survivorship of impaction autografted humeral implants using component subsidence as the primary end point.

Methods

We reviewed 286 primary anatomic

shoulder arthroplasties having an average follow-up of 4.9 +/- 2.7 years. Two different implants (HRP (Figure 4) and Global Advantage (Figure 5) were used). In each case, the prosthesis was fixed using impaction autograft harvested from the resected humeral head (Figure 6). Initial post-operative x-rays and minimum two-year follow-up x-rays were evaluated by three observers to assess subsidence.

Results

267 of 286 stems (93.4%) had not subsided. The Global Advantage had a subsidence-free survival 98.5% at five years (Figure 7). The stiffer-stemmed HRP used early on during the study had a higher rate of subsidence compared to the currently used Global Advantage stem (hazard ratio = 5.6, $p = 0.001$) (Figure 8). Radiolucent lines $\geq 2\text{mm}$ were less common for the Global Advantage than for the HRP in each of seven zones ($p < .001$). Total shoulder arthroplasty was associated with a higher rate of subsidence compared to hemiarthroplasty (hazard ratio = 2.6, $p = 0.12$).

Conclusions

Impaction autografting provides a secure, durable and bone-preserving means of humeral component fixation in anatomic shoulder arthroplasty.

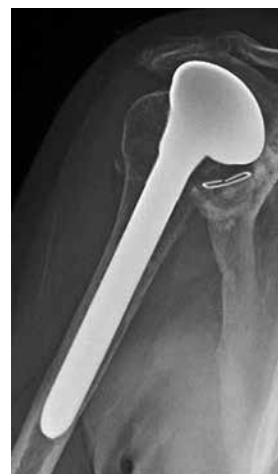

Figure 2: Humeral component malposition from a too-tight diaphyseal press fit.

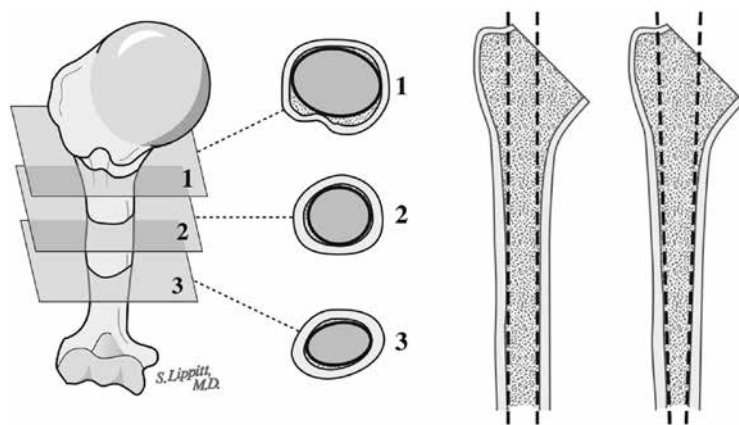


Figure 1: The variable endosteal cross sectional anatomy of the humerus cannot be matched by the cylindrical shape of prosthetic stems.



Figure 3: Impaction cancellous autografting of the humeral stem, minimizing contact between the prosthetic stem and the humeral cortex.

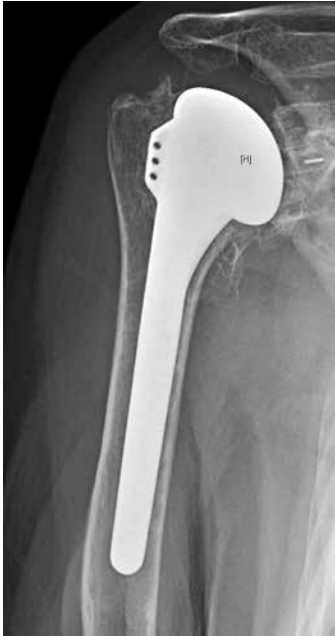

Figure 4: HRP Implant.

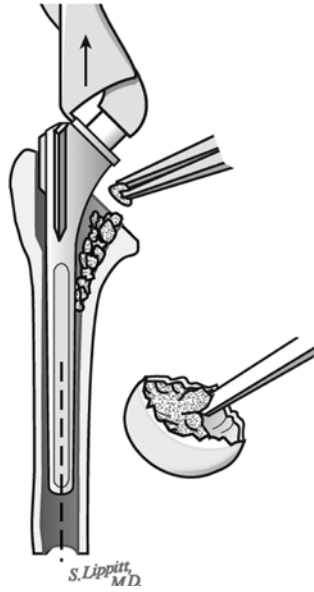


Figure 6: Prosthesis fixed using impaction autograft harvested from the resected humeral head.

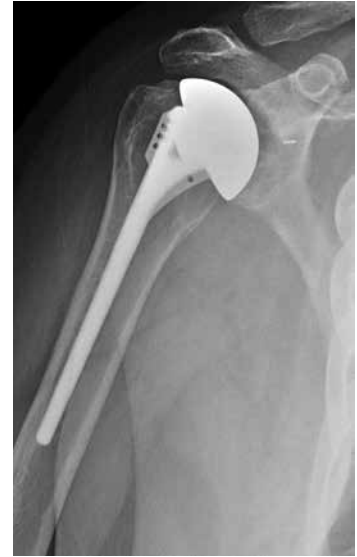

Figure 7: Global Advantage implant after five years.

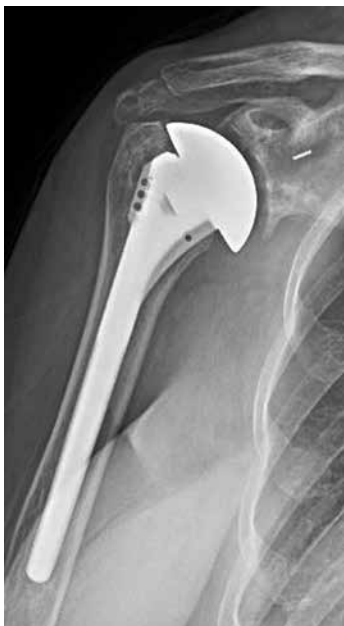

Figure 5: Global Advantage Implant.

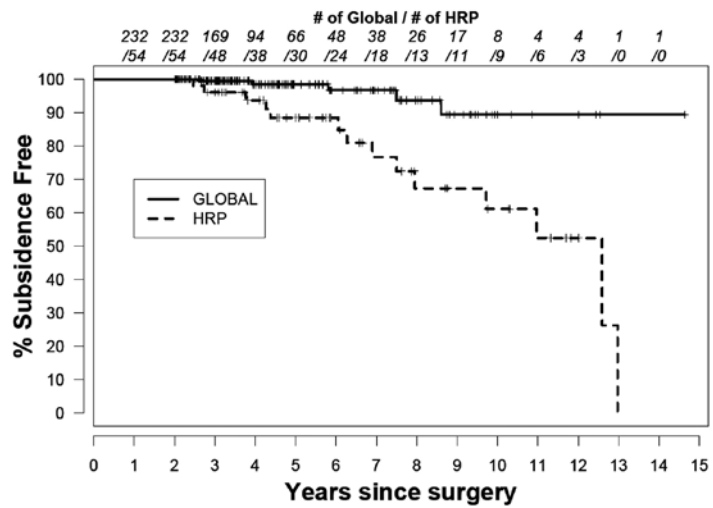


Figure 8: The stiffer-stemmed HRP used early on during the study had a higher rate of subsidence compared to the currently used Global Advantage stem (hazard ratio = 5.6, $p = 0.001$).

Treatment Of Irreparable Cuff Tears By Smoothing The Humeral Side Of The Humeroscapular Motion Interface: Patient-Reported Outcomes For 151 Shoulders With An Average Of 7.5 Year Followup

Jason E. Hsu, MD, Jacob D. Gorbaty, BA, Robert M. Lucas, MD, Stacy M. Russ, BA, and Frederick A. Matsen III, MD

Background

Rotator cuff repairs are frequently unsuccessful in restoring the anatomical integrity of the rotator cuff, yet patients with failed repairs are often improved clinically. This observation suggests the possibility that clinical improvement may be achieved in shoulders with irreparable cuff tears by a simple procedure that includes smoothing the interface between the proximal humeral convexity and the concave undersurface of the intact coracoacromial arch combined with a gentle manipulation to restore range of motion – the ‘smooth and move’ procedure.

Hypothesis

The authors tested the hypothesis that the self-assessed comfort and function of patients with irreparable rotator cuff tears can be significantly improved by the smooth and move procedure.

Study Design

Retrospective case series.

Methods

The smooth and move procedure is considered for stable, non-arthritis shoulders with symptomatic irreparable

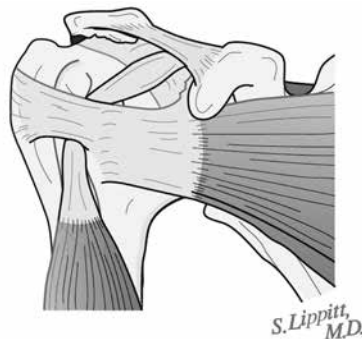


Figure 1: The smooth and move procedure is considered for stable, non-arthritis shoulders with symptomatic irreparable cuff tears and active elevation of the shoulder above 90 degrees.

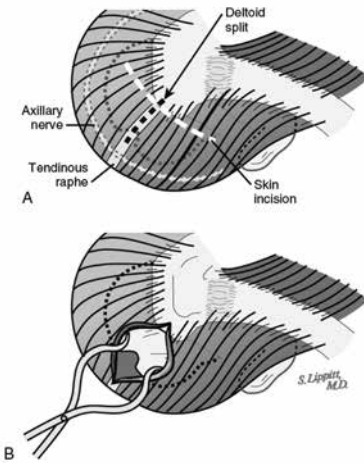


Figure 2: The shoulder is approached through a superior ‘deltoid-on’ incision.

cuff tears and active elevation of the shoulder above 90 degrees (Figure 1). The shoulder is approached through a superior ‘deltoid-on’ incision (Figure 2). The acromion and coracoacromial arch are preserved to avoid the problem of

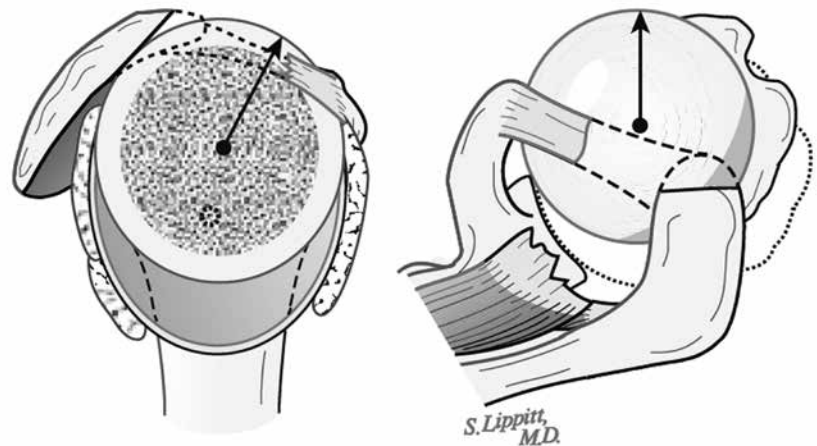


Figure 3: The acromion and coracoacromial arch are preserved to avoid the problem of anterosuperior escape.

anterosuperior escape (Figure 3). In cases of failed prior cuff repair attempts (Figure 4A), there is often residual suture in the humeroscapular motion interface (Figure 4B) which is debrided along with hypertrophic bursa and scar. The prominence of the exposed greater tuberosity is debrided (Figure 5). The deltoid split is securely closed (Figure 6) so that it is unnecessary to protect the repair, enabling immediate passive and active motion.

We report the two-year minimum patient self-assessed clinical follow-up on 151 patients having the smooth and move procedure for irreparable primary cuff tears or irreparable failed cuff repairs (Table I).

Results

For the 77 previously unrepaired tears, the mean Simple Shoulder Test (SST) score improved from 4.6 ± 3.3 to 8.5 ± 2.9 ($p < .001$) at an average of 7 years after surgery. Fifty-four (70%) patients improved by at least the Minimal Clinically-Important

Difference (MCID) of 2 SST points and 52 (68%) improved by at least 30% of the maximal possible improvement.

For the 74 failed prior repairs, the mean SST score improved from 4.0 ± 2.7 to 7.5 ± 3.3 ($p < .001$) at an average of 8 years after surgery. 54 (73%) patients improved by the MCID of 2 SST points and 44 (60%) improved by at least 30% of the maximal possible improvement (Table II). Patients are often able to return to high levels of activity, even though the rotator cuff is unrepaired (Figure 7).

Conclusions

The smooth and move procedure is a simple and effective procedure for managing the clinical symptoms of patients with irreparable cuff tears and irreparable failed cuff repairs. It has the advantage of enabling resumption of active use of the shoulder immediately after surgery and does not preclude subsequent more complex procedures should it be unsuccessful.

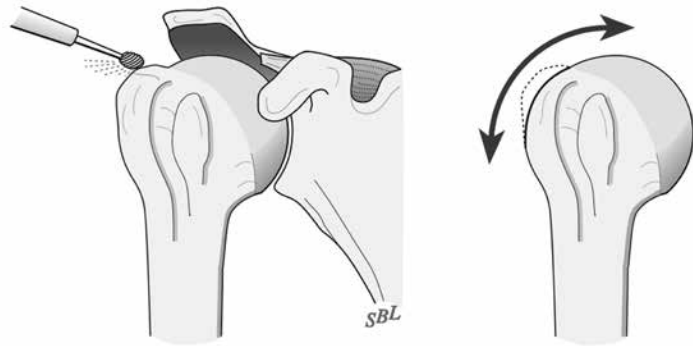


Figure 5: The prominence of the exposed greater tuberosity is debrided.

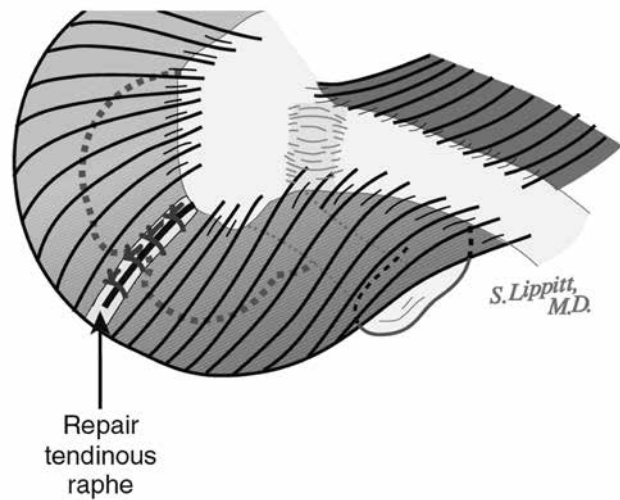


Figure 6: The deltoid split is securely closed.

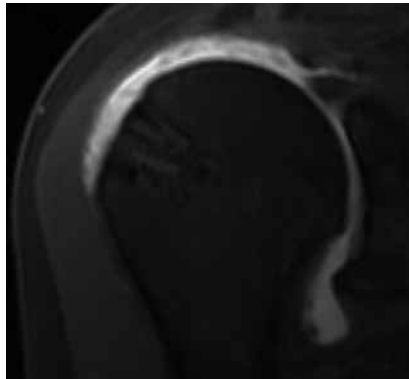


Figure 4A: Failed prior rotator cuff attempt.

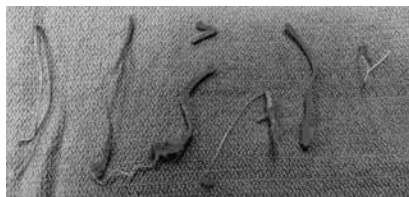


Figure 4B: Residual suture in the humeroscapular motion interface.



Figure 7: Patients are often able to return to high levels of activity, even though the rotator cuff is unrepaired.

	Irreparable primary cuff tear	Irreparable failed cuff repair
Number of Patients	77	74
Age	64.5 ± 8.5	62.3 ± 11.1
Length of Follow-Up (years)	6.9 ± 4.2	7.8 ± 4.9
Sex		
Male	28 (36%)	21 (28%)
Female	49 (64%)	53 (72%)
Prior Surgery		
Yes	13 (17%)	74 (100%)
No	64 (83%)	0 (0%)
ASA		
ASA 1	4 (7%)	4 (9%)
ASA 2	39 (72%)	22 (51%)
ASA 3	11 (20%)	15 (35%)
ASA 4	0 (0%)	2 (5%)
Diabetes		
Yes	11 (17%)	9 (15%)
No	55 (83%)	51 (85%)

Smoking		
Yes	7 (12%)	10 (17%)
No	51 (88%)	48 (83%)
Pre-op Narcotic Use		
Yes	18 (25%)	12 (18%)
No	53 (75%)	53 (82%)
Insurance		
Worker's Comp	8 (11%)	8 (13%)
Non-Worker's Comp	65 (89%)	56 (88%)
Cuff Integrity		
Supraspinatus torn	76 (99%)	54 (73%)
Infraspinatus torn	50 (65%)	34 (46%)
Teres minor torn	1 (1%)	3 (4%)
Subscapularis torn	15 (19%)	15 (20%)
Biceps torn	22 (29%)	20 (27%)

Table I: The two-year minimum patient self-assessed clinical follow-up on 151 patients having the smooth and move procedure for irreparable primary cuff tears or irreparable failed cuff repairs.

Group	# of Patients	Pre-SST	Post-SST	SST Change ≥ 2 points	SST Change ≥ 30% max
Irreparable primary cuff tear	77	4.6 ± 3.3	8.5 ± 2.9 ¹	54 (70%)	52 (68%)
Irreparable failed cuff repair	74	4.0 ± 2.7	7.5 ± 3.3 ²	54 (73%)	44 (60%)

Table II: For the 74 failed prior repairs, the mean SST score improved from 4.0 ± 2.7 to 7.5 ± 3.3 (p<.001) at an average of 8 years after surgery. 54 (73%) patients improved by the MCID of 2 SST points and 44 (60%) improved by at least 30% of the maximal possible improvement.

More Bang For Your Bundle? Oxinium Femurs On All-Polyethylene Tibial Components: Early Results And Hospital Cost Savings

Ryan D. Stancil, MD, Nathan W. Summers, PA-C, Navin D. Fernando, MD,
Howard A. Chansky, MD, and Adam A. Sassoon, MD, MS

Background: Bundled payments are motivating cost efficiency in total joint arthroplasty. All-polyethylene tibial components (APTCs) have demonstrated excellent survivorship and decreased cost compared to modular components. Recent opponents of APTCs criticize their conventional, rather than highly cross-linked, polyethylene composition. One implant addresses this tribological concern by mating an APTC with an Oxinium femoral component (OFC). The aims of this study were to report early patient reported outcomes (PROs) following TKA using OFCs on APTCs, and highlight the cost savings that results from their use.

Methods: A retrospective review of a single surgeon's (AS) series of TKAs using OFCs on APTCs was performed. Patient demographics and intraoperative data were recorded from the medical record. Range of motion and PROs were gathered at the most recent clinical follow-up. Implant costs were obtained directly from the surgeon's hospital.

Results: Between February and December 2015, 22 TKAs were performed in 20 patients with a mean age of 62.1 years. Fourteen (64%) TKAs were performed in females. The mean pre-operative BMI was 31 kg/m². TKA was performed for osteoarthritis in 17 patients, rheumatoid arthritis in 2, and psoriatic arthritis in 1. The mean postoperative length of stay was 2.6 days. At final follow-up the mean knee arc of motion was 116°. The mean post operative UCLA Activity Score: 5.3, KOOS JR: 73, and overall satisfaction: 91 out of 100. No revisions were required. Implant cost savings were estimated via comparison to the two other most commonly utilized implants in our hospital, both utilizing modular tibial components. Hospital savings per TKA were \$1,400, yielding a total implant savings in this series of \$33,500 for 22 arthroplasties.

Conclusion: This study demonstrates that TKA using OFCs on APTCs has acceptable short-term PROs with a demonstrable cost savings. Further investigation is needed to obtain mid- and long-term follow-up.

Introduction

Bundled care is becoming increasingly prevalent as a model of healthcare reimbursement, resulting in more cost conscious health care decisions. One factor over which the surgeon has direct control is the choice, and therefore the cost, of arthroplasty implants. All-polyethylene tibial components (APTCs) have shown excellent survivorship as far out as 10 years at a decreased cost compared to modular components.[1-3] Several studies have also shown comparable knee range of motion, functional outcome, and patient satisfaction.[4, 5] Some concern over use of APTCs comes from the fact that they employ conventional polyethylene instead of highly cross-linked polyethylene, increasing the rate of wear, osteolysis and therefore aseptic implant loosening. Optimizing wear characteristics of the components is vital as polyethylene wear and aseptic loosening cause 25% and 24.1% of TKA failures, respectively. [6]

One implant on the market mitigates

this risk by mating the APTC with an oxinium (oxidized zirconium) femoral component (OFC) to improve wear characteristics.[7] Biomechanical studies of oxinium components have shown increased scratch resistance, decreased roughness, and an 80% reduction in polyethylene wear when compared to standard cobalt-chrome components.[8] Oxinium also has the added benefit of high biocompatibility. Studies have shown that 55-60% of patients with poorly functioning arthroplasties have a metal allergy to either nickel, cobalt, or chrome.[9]

The aims of this study were to report early patient reported outcomes (PROs) following TKA using OFCs on APTCs, and highlight the cost savings that results from their use.

Methods

A retrospective review of a single surgeon's (AS) consecutive series using OFCs on APTCs was performed. Patient demographics and intraoperative data were gathered from the medical record. Post-operative

outcome scores (UCLA Activity Score, Knee Injury and Osteoarthritis Outcome Score for Joint Replacement (KOOS, JR.) [10], and overall satisfaction (0-100 scale) were gathered at the most recent clinical follow-up. Implant costs were obtained directly from the surgeon's hospital.

Results

Between February and December 2015, 22 TKAs were performed in 20 patients. Patient demographics included a mean age of 62.1±9.8 years, 14 (64%) TKAs in 12 (60%) females, mean pre-operative body mass index (BMI) of 30.9±4.9 kg/m² and ASA physical status score of 2±0.5. The indication for TKA was osteoarthritis except in 2 patients with rheumatoid arthritis and 1 with psoriatic arthritis. Implant characteristics decided on intra-operatively include 17 (77%) cruciate retaining components and 5 (23%) posterior stabilized components, with 13 of 22 (59%) patellas being resurfaced. The mean length of inpatient hospital stay was 2.6±1.2 days.

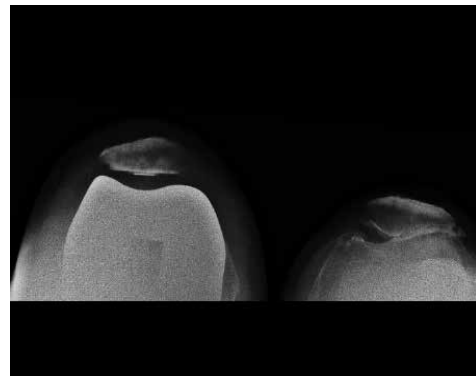
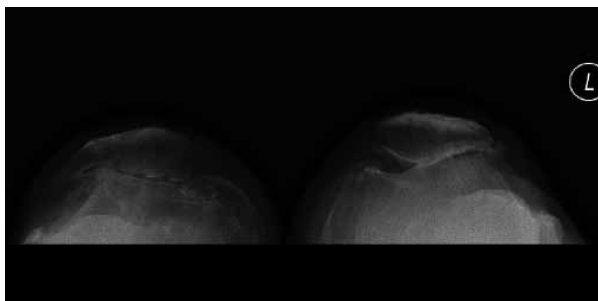
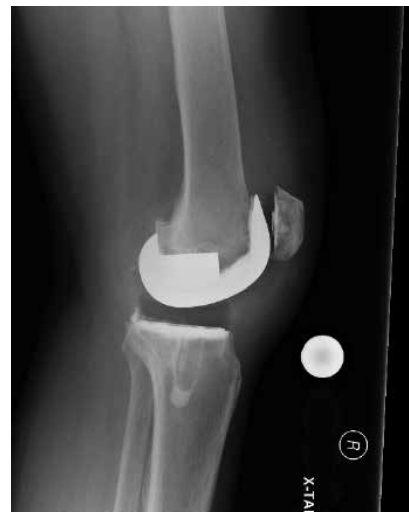
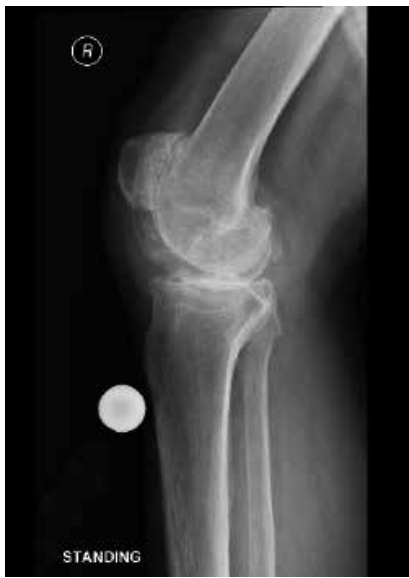
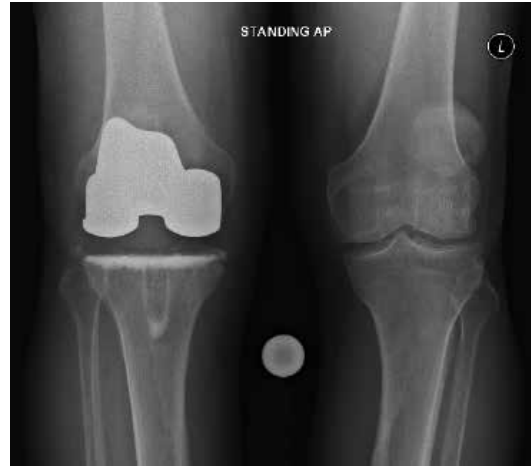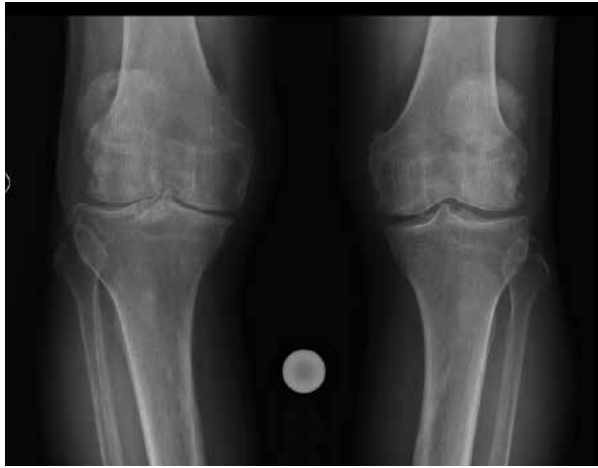Figure 1(a-c): Preoperative AP (a), lateral (b), and Merchant (c) radiographs demonstrating end-stage tricompartmental osteoarthritis.

Figure 2(a-c): Postoperative AP (a), lateral (b), and merchant (c) radiographs demonstrating treatment of patient shown in Figure 1 with a posterior stabilized total knee arthroplasty using an Oxinium femoral component and all-polyethylene tibial component.

Post-operative follow up data was obtained from 3-13 months after surgery, with a mean follow-up of 8 months. Mean knee range of motion was 116 ± 8 degrees. Mean outcome scores were as follows; UCLA Activity Score: 5.3 ± 1.8 , KOOS, JR: 73.4 ± 11.1 ,

and overall satisfaction 91.6 ± 9.2 . There have currently been no revision surgeries required. There were two complications: an intraoperative medial femoral condyle fracture requiring screw fixation and no further intervention or weight bearing restriction and one case

of arthrofibrosis, which was successfully treated with a closed manipulation under anesthesia.

To determine implant cost savings, the study looked at the two most commonly used knee implants in our hospital (Persona and Triathlon, both



Figure 3: Intraoperative photograph of an Oxinium femoral component on all-polyethylene tibial component.

modular components with a highly cross-linked polyethylene insert each costing \$4,900) and compared it the OFC on APTC components which cost \$3,500 with patellar resurfacing, \$3,200 without. Institutional savings per TKA were therefore between \$1,400 and \$1,700. Total implant savings in this series of 22 TKAs was \$33,500.

Conclusions

The results of this study show that total knee arthroplasty using oxinium on all-polyethylene components in a primary arthroplasty patient population has acceptable short-term functional and patient satisfaction outcomes at a demonstrable cost savings to the surgeon's institution. This study suffers from several limitations including those inherent to its retrospective design. Additionally, there was no control group and follow-up is limited. Further investigation is needed to obtain long-term functional and patient satisfaction outcomes.

References

1. Voigt, J. and M. Mosier, Cemented all-polyethylene and metal-backed polyethylene tibial components used for primary total knee arthroplasty: a systematic review of the literature and meta-analysis of randomized controlled trials involving 1798 primary total knee implants. *Journal of bone and joint*

surgery. 2011. 93(19): p. 1790-1798.

2. Kremers, H.M., et al., Comparative Survivorship of Different Tibial Designs in Primary Total Knee Arthroplasty. *Journal of bone and joint surgery*. 2014. 96(14): p. e121-e121.

3. Murray, D.W., et al., A randomised controlled trial of the clinical effectiveness and cost-effectiveness of different knee prostheses: the Knee Arthroplasty Trial (KAT). *Health technology assessment*. 2014. 18(19): p. 1-235, vii.

4. Toman, J., R. Iorio, and W.L. Healy, All-polyethylene and Metal-backed Tibial Components Are Equivalent With BMI of Less Than 37.5. *Clinical Orthopaedics and Related Research*. 2012. 470(1): p. 108-116.

5. Kalisvaart, M.M., et al., Randomized clinical trial of rotating-platform and fixed-bearing total knee arthroplasty: no clinically detectable differences at five years. *Journal of bone and joint surgery*. 2012. 94(6): p. 481-489.

6. Sharkey, P.F., et al., Insall Award paper. Why are total knee arthroplasties failing today? *Clinical orthopaedics and related research*. 2002(404): p. 7-13.

7. Spector, B.M., et al., Wear performance of ultra-high molecular weight polyethylene on oxidized zirconium total knee femoral components. *Journal of bone and joint surgery*. 2001. 83-A Suppl 2 Pt 2: p. 80-86.

8. Lee, J.K.L., et al., Increased force simulator wear testing of a zirconium oxide total knee arthroplasty. *The knee*, 2009. 16(4): p. 269-274.

9. Hallab, N., K. Merritt, and J.J. Jacobs, Metal sensitivity in patients with orthopaedic implants. *Journal of bone and joint surgery*., 2001. 83-A(3): p. 428-436.

10. Lyman, S., et al., Validation of the KOOS, JR: A Short-form Knee Arthroplasty Outcomes Survey. *Clinical orthopaedics and related research*. 2016.

Prophylactic Use Of Antibiotic Impregnated Calcium Sulfate Beads In Revision Hip And Knee Arthroplasty Procedures At High Risk For Prosthetic Joint Infection

Ryan D. Stancil, MD, Nathan W. Summers, PA-C, Navin D. Fernando, MD,
Howard A. Chansky, MD, and Adam A. Sassoon, MD, MS

Background: Periprosthetic joint infections (PJI) are a devastating complication after total hip or knee arthroplasty (THA or TKA). Risk factors for PJI include previous PJI or osteomyelitis, revision arthroplasty for aseptic indications, a history of previous surgery, and patient-host factors. Most PJIs present within the first two years after index surgery. Local antibiotic delivery may be a reasonable strategy to mitigate this risk for high-risk individuals. One such technique uses antibiotic impregnated calcium sulfate beads (Stimulan™) placed in the surgical field after component implantation. The aims of this study are to report early results for post-operative complications and PJI recurrence in high-risk THA and TKA patients that received Stimulan™ beads.

Methods: A retrospective review of high-risk THA and TKA performed with Stimulan™ by two surgeons (NF, AS) was completed. Patient demographics, operative details, and outcomes were gathered from the medical record.

Results: Between 08/2014 and 02/2016, Stimulan™ was used in 45 patients (mean age = 63.4, 23 females). The procedures were categorized as follows: 20 aseptic THA revisions, 8 aseptic TKA revisions, 5 THA re-implantations (for treated PJI), 4 TKA re-implantations, 3 THA explantations, 3 primary THAs, and 2 primary TKAs. No patients have experienced new or recurrent PJI at a mean follow-up of 5 months (range: 1-20). There were 2 (4.4%) wound complications; a draining wound that required irrigation and debridement (THA re-implantation), and a superficial dehiscence that required local wound care (TKA revision). There were 4 (8.8%) additional, likely, unrelated complications: psoas tendonitis, a perioperative PE, a chronic draining wound from a flap donor site remote from the beads, and knee arthrofibrosis.

Conclusions: These results demonstrate encouraging short-term outcomes with respect to wound healing and recurrent PJI in high-risk THA and TKA procedures employing Stimulan™. Additional long-term follow-up is required to determine the efficacy of Stimulan™ in PJI prophylaxis.

Introduction

Periprosthetic joint infections (PJI) after total hip or knee arthroplasty (THA or TKA) occur at 1-2% within the first 2 years after surgery and have significant effects on patient functional outcomes, morbidity and mortality. [1] Conservative estimates place the cost of treating a PJI at \$50,000, placing a tremendous burden on the hospital system.[2] Risk factors for PJI include: previously treated PJI or osteomyelitis, revision arthroplasty for aseptic indications (loosening, fracture, wear, etc.), a history of previous non-arthroplasty surgery in the same joint, as well as patient-host factors such as morbid obesity, corticosteroid use, inflammatory arthritis, and/or immunosuppression.[3]

The standard of care for infection prophylaxis in all arthroplasty procedures includes proper techniques in operating room management, skin preparation, staphylococcus aureus carrier screening, and pre-operative parenteral antibiotic dosing.[4-6] Identifying additional prophylactic

measures for arthroplasty patients at higher risk of infection remains controversial. Several strategies include local antibiotic delivery through non-biodegradable drug delivery implants such as antibiotic laden polymethylmethacrylate (PMMA) cement, or bio-absorbable calcium sulfate beads. While antibiotic laden PMMA use in the form of cemented components or beads is widespread in treatment of PJI and other orthopedic infections, its use and cost-effectiveness in PJI prophylaxis is controversial.[7-9] Antibiotic laden PMMA cemented components may have altered biomechanical properties, and permanent beads may cause mechanical symptoms or result in a nidus for infection, requiring removal.

Antibiotic impregnated calcium sulfate beads (Stimulan™) avoid the above-mentioned problems by being bio-absorbable. Antibiotic elution occurs at concentrations that exceed the minimum inhibitory concentration for common periprosthetic joint infection pathogens for up to 42 days, with no

effects on polyethylene wear rates in in vitro studies.[10-12] Preliminary studies have shown that similar products have equivalent rates of infection eradication in infected non-union and osteomyelitis patients with fewer reoperations compared to patients that received PMMA. [13] They have additionally demonstrated the ability to prevent bacterial colonization and biofilm formation in periprosthetic infections.[14]

The aims of this study are to report early results for post-operative complications and PJI recurrence in high-risk THA and TKA patients that received Stimulan™ beads for either PJI treatment or prophylaxis.

Methods

A retrospective review was done of high-risk THA and TKA performed with Stimulan™ by two surgeons (NF, AS). Patient demographics, operative details, and outcomes were gathered from the medical record. Patients were categorized as follows: THA and TKA revisions for aseptic indications,

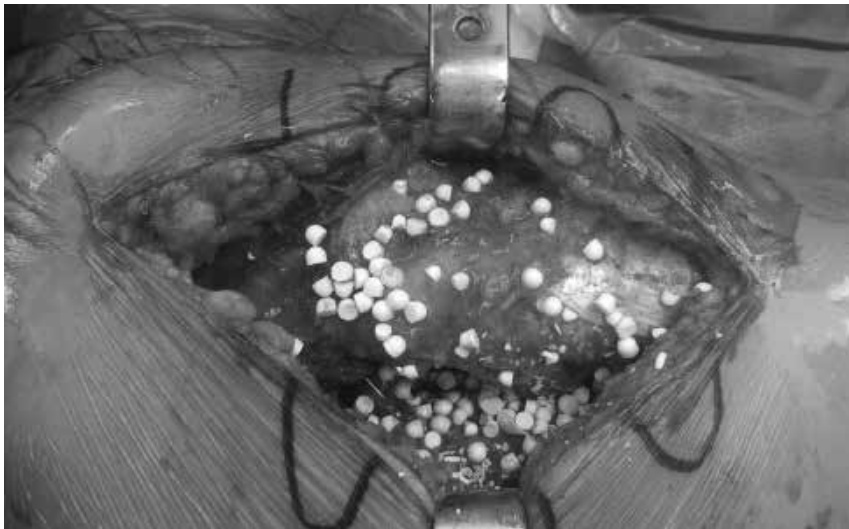


Figure 1: Intraoperative photo of Stimulan Beads being used during a high risk hip arthroplasty procedure.

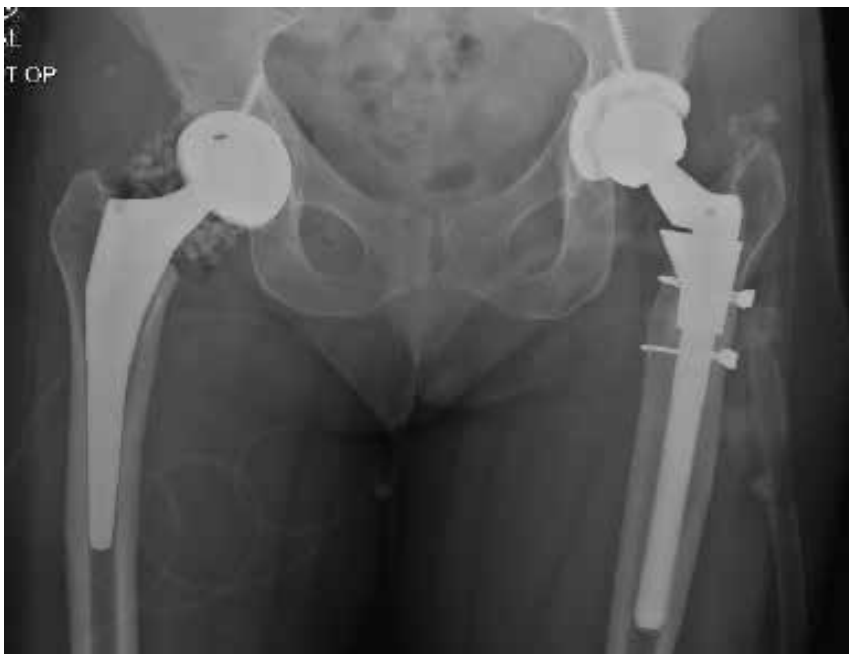

Figure 2: Immediate post op x-rays following a R THA, in the setting of previously treated periprosthetic infection complicating her L THA done at an outside facility.

THA and TKA re-implantations (for PJI treated in a 2-stage manner), THA explantations for initial PJI treatment, and primary THA and TKA. Except for 1 patient that had had a prior PJI in a contralateral THA, the high-risk primary arthroplasties in which Stimulan™ was used had a history of prior surgery in the same joint.

Results

Between August 2014 and February 2016, Stimulan™ was used in 45 patients (mean age = 63.4, 23 females).

The procedures were categorized as follows: 20 aseptic THA revisions, 8 aseptic TKA revisions, 5 THA re-implantations, 4 TKA re-implantations, 3 THA explantations, 3 primary THAs, and 2 primary TKAs.

No patients to date have experienced new or recurrent PJI at a mean follow-up of 5 months (range: 1-20 months). There were 2 (4.4%) wound complications; a draining wound that underwent irrigation and debridement (THA re-implantation), and a superficial wound dehiscence that required local

wound care (TKA revision), both of which healed without the need for subsequent intervention. There were 4 (8.8%) additional, likely, unrelated complications: psoas tendonitis treated successfully with corticosteroid injection, a perioperative PE treated with therapeutic anticoagulation and no further sequelae, a chronic draining wound from a rotational rectus flap donor site remote from the beads in which eventual skin grafting is planned, and knee arthrofibrosis in a patient poorly compliant with post-operative rehabilitation.

Discussion

These results demonstrate encouraging short-term outcomes with respect to wound healing and recurrent PJI in high-risk primary and revision THA and TKA procedures employing Stimulan™. The low rate of wound complications could result from several factors including wound closure methods and the high prevalence of incisional vacuum-assisted wound closure devices in this population.

One factor unique to Stimulan™, which may aid in lower wound drainage complication rates, is its manufacturing process. Stimulan™ is synthetic calcium sulfate, which means it is free from impurities that may result from conventionally mined calcium sulfate products. This may result in less local soft tissue reaction and less particulate effects on polyethylene wear rates. [10] Long-term follow-up is required to determine the clinical and cost-effectiveness of Stimulan™ in PJI prophylaxis.

This study suffers from several limitations, including its retrospective design and lack of a control group. Additional studies should also be aimed at assessing potential side effects, including hypercalcemia reported with bio-absorbable calcium sulfate beads in revision arthroplasty [15] and the development of antibiotic resistant organisms similar to that reported with the use of antibiotic laden PMMA. [7]

References

1. Kurtz, S.M., et al., Prosthetic joint infection risk after TKA in the Medicare population. *Clinical orthopaedics and related research*, 2010. 468(1): p. 52-56.
2. Kurtz, S.M., et al., Economic burden of periprosthetic joint infection

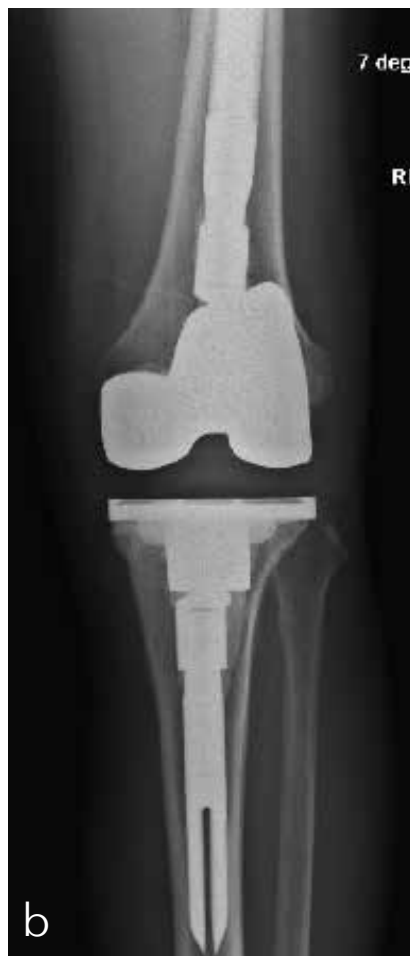
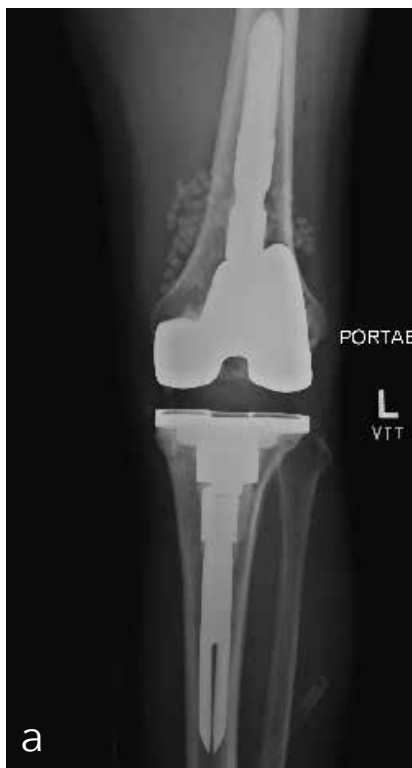
Figure 3 a & b: Reimplantation L TKA immediate post op films (a) and at the 6-week postoperative time point (b), demonstrating bead reabsorption.

in the United States. *The journal of arthroplasty*. 2012. 27(8 Suppl): p. 61-5.e1.

3. Haynes, J.A., et al., Contemporary Surgical Indications and Referral Trends in Revision Total Hip Arthroplasty: A 10-Year Review. *The journal of arthroplasty*. 2016. 31(3): p. 622-625.

4. Bosco, J.A., et al., Principles of Antibiotic Prophylaxis in Total Joint Arthroplasty: Current Concepts. *Journal of the American Academy of Orthopaedic Surgeons*. 2015. 23(8): p. e27-e35.

5. Ricciardi, B.F., et al., Prevention of surgical site infection in total joint arthroplasty: an international tertiary care center survey. *HSS J*. 2014. 10(1): p. 45-51.

6. Illingworth, K.D., et al., How to minimize infection and thereby maximize patient outcomes in total joint arthroplasty: a multicenter approach: AAOS exhibit selection. *Journal of bone and joint surgery*. 2013. 95(8): p. e50-e50.

7. Hansen, E.N., et al., Routine use of antibiotic laden bone cement for primary total knee arthroplasty: impact on infecting microbial patterns and resistance profiles. *The journal of*

arthroplasty. 2014. 29(6): p. 1123-1127.

8. Qadir, R., et al., Risk stratified usage of antibiotic-loaded bone cement for primary total knee arthroplasty: short term infection outcomes with a standardized cement protocol. *J Arthroplasty*. 2014. 29(8): p. 1622-4.

9. Jiranek, W.A., A.D. Hanssen, and A.S. Greenwald, Antibiotic-loaded bone cement for infection prophylaxis in total joint replacement. *Journal of bone and joint surgery*. 2006. 88(11): p. 2487-2500.

10. Lewicki, K., et al. Calcium Sulfate Does Not Increase Wear of Polyethylene in Total Joint Arthroplasty. in *American Academy of Orthopaedic Surgeons Annual Meeting*. 2015. Las Vegas, NV: American Academy of Orthopaedic Surgeons.

11. McConoughey, S.J., et al., Comparing PMMA and calcium sulfate as carriers for the local delivery of antibiotics to infected surgical sites. *Journal of biomedical materials research*. 2015. 103(4): p. 870-877.

12. Aiken, S.S., et al., Local release of antibiotics for surgical site infection

management using high-purity calcium sulfate: an in vitro elution study. *Surgical infections*. 2015. 16(1): p. 54-61.

13. McKee, M.D., et al., A prospective, randomized clinical trial comparing an antibiotic-impregnated bioabsorbable bone substitute with standard antibiotic-impregnated cement beads in the treatment of chronic osteomyelitis and infected nonunion. *Journal of orthopaedic trauma*. 2010. 24(8): p. 483-490.

14. Howlin, R.P., et al., Antibiotic-loaded synthetic calcium sulfate beads for prevention of bacterial colonization and biofilm formation in periprosthetic infections. *Antimicrobial agents and chemotherapy AAC*. 2015. 59(1): p. 111-120.

15. Kallala, R. and F.S. Haddad, Hypercalcaemia following the use of antibiotic-eluting absorbable calcium sulphate beads in revision arthroplasty for infection. *The bone & joint journal*. 2015. 97-B(9): p. 1237-1241.

The background features a large, light gray watermark of the University of Washington Orthopaedics & Sports Medicine logo. The logo is circular and contains the text "UNIVERSITY OF WASHINGTON" at the top and "ORTHOPAEDICS & SPORTS MEDICINE" at the bottom. In the center of the logo is a stylized illustration of a lighthouse on the left and a tree on the right.

Service And Community Outreach Articles

“The best way to find yourself is to lose yourself in the service of others.”

— Mahatma Gandhi

Zhengzhou Orthopaedic Hospital Visit

Carlo Bellabarba, MDCM

In November of 2015, various members of the University of Washington's Spine Surgery team visited the Zhengzhou Orthopaedic Hospital (ZOH), in Zhengzhou, Henan Province, China as part of an ongoing collaboration between the UW and ZOH. The goal of this project, overseen by Fangyi Zhang, MD (UW Associate Professor of Neurological Surgery and Joint Associate Professor of Orthopaedics & Sports Medicine), is to help enhance the delivery of spine care at ZOH through an exchange of ideas, knowledge, and experience. The UW contingent consisted of a multidisciplinary team comprised of a neurosurgeon, Fangyi Zhang, MD, two orthopaedic surgeons, Ted Wagner, MD (Professor of Orthopaedics & Sports Medicine, Joint Professor of Neurological Surgery) and Carlo Bellabarba, MD (Professor of Orthopaedics & Sports Medicine, Joint Professor of Neurological Surgery), and an electrodiagnostic technologist, Mark Klein (Supervisor, Harborview neuromonitoring team, Dept. of Physical Medicine & Rehabilitation). This three-day event consisted of a series of didactic lectures from both ZOH and UW faculty members, clinical evaluation of complex patients by the UW faculty with ensuing case discussion with our Chinese colleagues, observation of surgical procedures and processes, and practical instruction on intraoperative neuromonitoring techniques by Mark Klein. These educational activities were bracketed by ceremonial events that included highly respected local spine surgeons and political dignitaries, and were interspersed with various cultural and social events. Along with the ability to share experiences with our Chinese colleagues, among the highlights of our trip were the personal concert of traditional ancient 'Chinese Music of Huaxia,' performed for our contingent after a guided tour of the Henan Provincial Museum, one of China's oldest museums, in which are displayed innumerable cultural treasures from the 3,000 recorded years of civilization of Henan Province, China's birthplace.



Dr. Fangyi Zhang responds to questions during spine surgery symposium at Zhengzhou Orthopaedic Hospital.



Dr. Ted Wagner lecturing with Mark Klein (foreground) and Fangyi Zhang, MD (with microphone) in attendance.

We look forward to continuing this collaborative effort with our Chinese spine colleagues at the Zhengzhou Orthopaedic Hospital for years to come.

Bangladesh Spine Society Trip

Theodore A. Wagner, MD and Calvin Schlepp, MD

Dr. Ted Wagner and Dr. Calvin Schlepp were fortunate to be invited to attend the International Scientific Study Conference hosted by the Bangladesh Spine Society in Dhaka, Bangladesh. During their travels, they also visited local areas' hospitals to gain a better understanding for the current conditions of orthopaedic care.

After a 20-hour flight to Dhaka via Dubai, we were put up in a modest hotel in a bustling city. The hospitality was exceptional and special recognition should go out to Dr. Hoque, the secretary of Health and Human Welfare, and Dr. Shah Alam, a prominent member for the Bangladesh Spine Society, who arranged our security and transportation for the week.

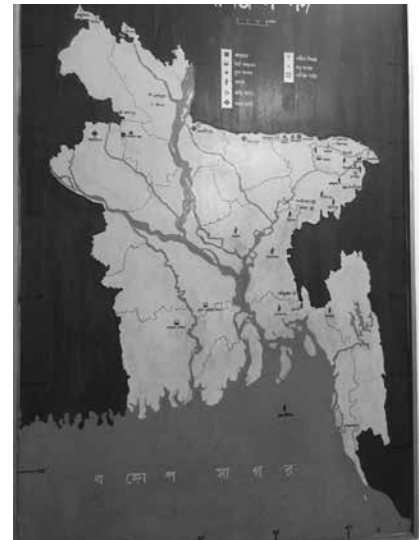This trip included observation and educational sessions at NITOR Hospital (National Institute of Trauma and Orthopedic Rehabilitation), a public, 500 bed (soon to be 1,000 bed) orthopaedics-only hospital in Dhaka. Mornings started with a formal version of morning sign-out, focused on resident presentations of the following day's operative cases. Most of the cases performed are related to trauma, i.e. hip fractures, pediatric elbow, long bone fractures, spine trauma, and infections, but occasional elective cases are performed at the hospital including ACL reconstructions and deformity correction surgeries.

We observed surgeries, clinics, and care on the wards at NITOR for three days. They have 7 ORs and a couple of additional procedure rooms. Due to anesthesia limitations, they are only able to perform 3 cases per day in each room. The theaters were fairly primitive but c-arm fluoroscopy and a reasonable selection of implants are available from companies based in India. Examples of cases included Tibial and Femoral Interlocking Rods, Bipolar Femur Hemiarthroplasties, Tibial Plateau treated with Locking Plates, Arthroscopic ACL reconstruction, PSIF with T8 corpectomy and cage stabilization, and Ilizarov External Fixation.

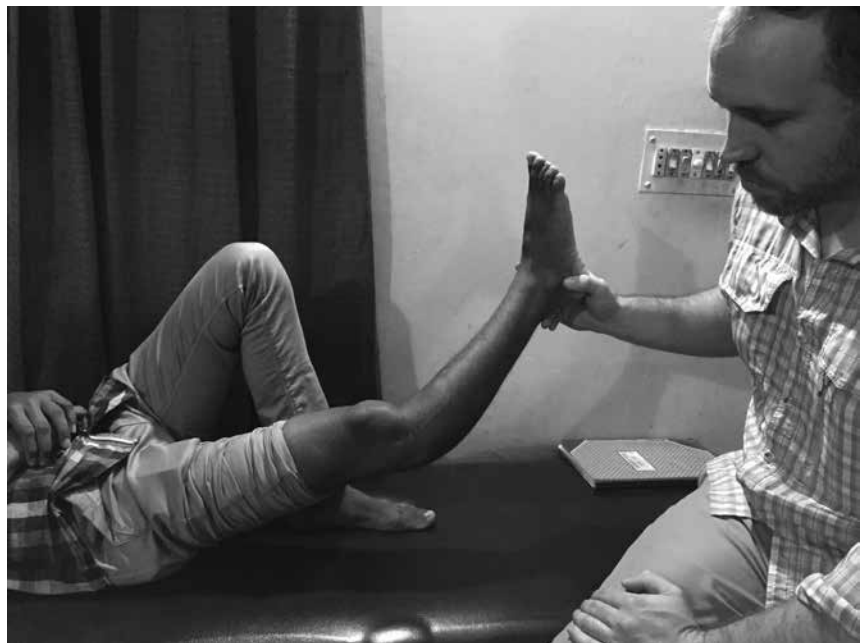Of particular interest to us was the use of Ilizarov small wire external fixators. The Ilizarov is their preferred method for management of open periarticular fractures, infected

nonunions, and deformity corrections. We attended two separate Ilizarov clinics, one at NITOR and one at a small private hospital, and were quite impressed with the capability for limb salvage and deformity correction. The complexity and volume of trauma was incredible, mostly from motor vehicle associated injuries. Contributing to the complexity was a common theme of delayed presentation to the centers that can adequately treat these injuries.

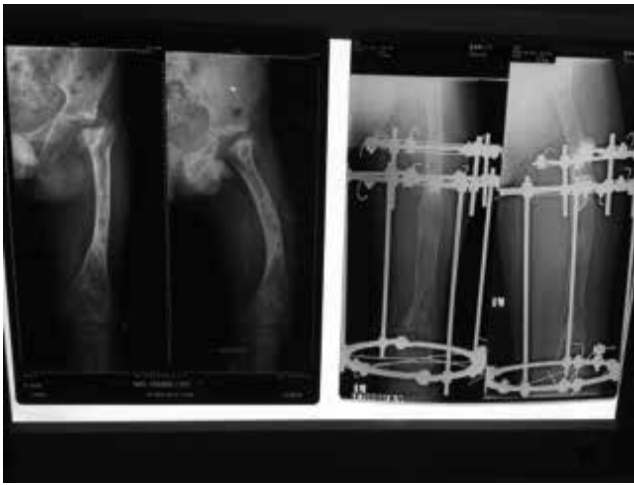Despite this seemingly broad and diverse ability to manage orthopaedic disease, the continued need for improving education and better training was very apparent. Without trying to be overly critical, we observed failures in the application and execution of orthopaedic surgery. Sterility was questionable, techniques and approaches were often rushed and insensitive to proper soft tissue management, and implants were not used as they were designed. Some



examples included fracture fixation with reductions that we would consider completely unacceptable, placement of hemiarthroplasty components designed to be cemented that were impacted into canals without broaching and



Old untreated knee injury examined by Dr. Calvin Schlepp (right).



Ilizarov external fixation for open tibial fracture.



Dr. Wagner, Dr. Atiar Rahman, and Dr. Schlepp in Nalta Hospital in front of a picture of Dr. George Bagby, who funded and built the hospital.

without cement (once resulting in a calcar fracture that was cabled in an unreduced position), and a pediatric elbow fracture stabilized using 3 medial pins, and Dr. Wagner was able to convince the spine team during a corpectomy that cages would be a better option for the anterior column, if the costs could be absorbed. For certain cases it seems that the basic fundamentals and execution during surgery have not developed although they are aware of the technology.

We spent two days traveling to a small rural hospital in the town of Nalta, just a few kilometers from the Indian border in the far southwest portion of the country. This included a short domestic flight and a 2-hour "high drama" van ride through the rural portions of the country. The two-lane poorly paved road through rice fields, fish farms, and brickmaking facilities was shared by trucks, vans, homemade motorized rickshaws, bicyclists, and pedestrians, all traveling at different rates of speed. Besides sharing the road, drivers share the intent of travelling as fast as possible and by communicating through the liberal use of horns. Traffic lights and signs are considered mere suggestions. The etiology of trauma was clear!

We arrived with a ceremony at the Nalta community health center built with the support of Dr. George Bagby from Spokane. We toured the hospital, prosthetics international clinic, and the radio station where Dr. Wagner recorded a public service announcement to educate the population on basics of back pain management. Dr. Schlepp spoke on injury prevention and motor

vehicle safety, the latter being fresh on our minds from our trip.

Within an hour of our arrival being announced, lines of patient came to the health center and we held an impromptu clinic. We estimate 30-40 patients showed up with hard copies of their imaging studies and various histories of acute and chronic musculoskeletal disorders. Pathology included routine cases of back pain in young laborers and seasoned matriarchs, chronic rotator cuff tear in the chief of police, untreated traumatic retrolisthesis of L5/S1 in the assistant clinic manager, and a computer engineering student from a local university with severe recurvatum and varus deformity from the late sequela of septic arthritis as a child. In this area, treatment options were limited to NSAIDs, PT, referral to an urban medical center and reassurance, with most patients looking for the latter.

We stayed in the childhood home of the former Minister of the Department of Health and Human Welfare for Bangladesh, Dr. Hoque, who proved to be a revered political figure to the people and gracious and hospitable host throughout our trip.

We completed our trip by attending and presenting at the International Scientific Study Conference in Dhaka, Bangladesh. Dr. Wagner presented talks on the History and Limitations of Scoliosis Classification and Selection of Fusion Levels in AIS. Dr. Schlepp presented on Radiation Exposure and Safety considerations for patients and surgeons during spine surgery. The conference was well attended by spine surgeons from Bangladesh,

Iran, Pakistan, Malaysia, Singapore, Indonesia, and South Korea. We were impressed by the diversity and complexity of cases and topics presented. A very special visit was made to the small machine shop where Ilizarov apparatuses are produced by bending, drilling, and welding straps of steel. Dr. Schlepp practiced some metalwork and we bought an entire fixation set for fifty dollars.

We left with a better understanding of the bustling city of Dhaka and the hospitable nature and culture of the 150 million people of Bangladesh. They will face many challenges in the future, including the prospects of losing 50% of their landmass in the next 50 years due to climate change and rising sea level. A key role for the World Health Organization and United Nations will be predicting and preventing the health issues for millions of people forcing mass migration upon a delicate economy and marginal health care systems. From an orthopaedic perspective, understanding the volume of musculoskeletal cases requiring surgery and the limited resources forces one to realize that poverty is the common denominator of poor health statistics. Surgeons from the developed world need to extend their teaching of general principles while learning to appreciate the effectiveness of the ingenious low cost methods of treatment. A careful observer and good listener is the best guest and becomes the most effective teacher.

Lessons From Complex Scoliosis Surgery In Sri Lanka

Vijay Yanamadala, MD and Rajiv Sethi, MD

As we walked into the sprawling 3,000 bed National Hospital of Sri Lanka on that first sweltering night of our mission, I could not fathom what a transformative experience my four days of operating there with our international team would be. Not only was I pushed to new reaches as a surgeon, I also came to immensely appreciate the incredible positive attitude and perseverance of the Sri Lankan surgeons and staff.

We walked in that first day to a ward full of young girls with severe scoliosis, accompanied by their parents, eagerly awaiting our team, hopeful that they would be selected to have surgery. Also present were patients with a wide variety of spinal disorders, from severe degenerative disorders of the cervical and lumbar spine to spinal infections leading to paraplegia. We could only accommodate a handful of patients from the more than 20 that had come from far reaches of the country at their own expense – in some cases, a month’s salary for their parents. We were led through the group by Dr. Rajiv Sethi, Director of the Virginia Mason Neuroscience Institute, Clinical

Associate Professor of Health Services at the University of Washington, and senior scoliosis surgeon, and Dr. Arvind Jayaswal, Professor Emeritus of Orthopaedic Surgery, All India Institute of Medical Sciences (AIIMS), and a senior complex spine surgeon. We examined each of the patients and perused their films, gleaning every detail of their deformities. We knew coming in that we could not help everyone – our time and our resources were limited. We picked three girls who had complex scoliosis who would both benefit from surgery and also allow us to demonstrate the surgery by live video to the Sri Lankan orthopaedic and neurosurgical community, to hopefully inspire some among them to continue this work after we left. We also selected a patient with a grade II degenerative spondylolisthesis, cervical spondylotic myelopathy, and tuberculous osteomyelitis to illustrate the breadth and depth of spine surgery.

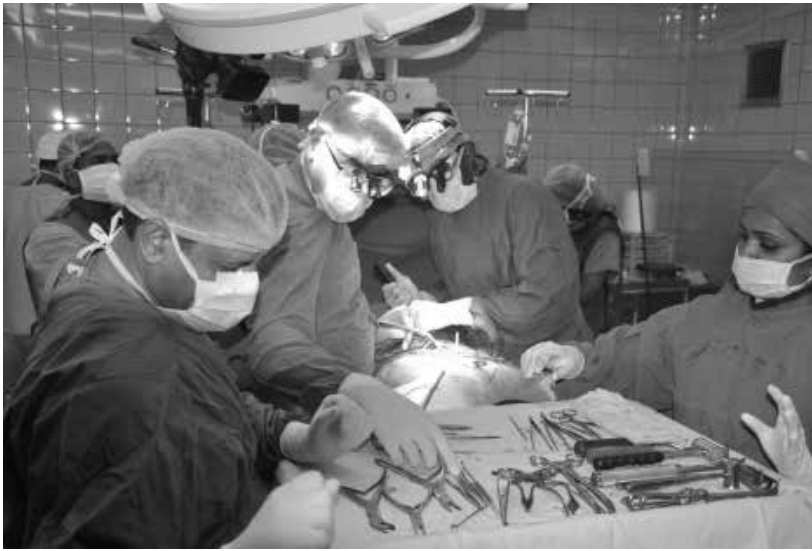The next day, the entire community of neurosurgeons and orthopaedic surgeons in Sri Lanka gathered for the conference. We learned that the island hosts 50 orthopaedic surgeons and 10

neurosurgeons for a total population that exceeds 20 million people, and nearly all of them were in attendance. After a half day of presentations on spine surgery, we began the live operative demonstration. Dr. Sethi and I performed a lumbar posterolateral decompression and fusion for degenerative spondylolisthesis while Dr. Jayaswal and his team operated on a patient with tuberculous osteomyelitis. Everyone in those operating rooms was excited to be there – from the scrub nurses to the anesthesiologists. Whereas in the U.S., we would probably open four or five trays worth of equipment for a lumbar fusion, we had everything – truly everything – we needed in a single tray in that Sri Lankan operating room. This was probably my most striking observation – how we could accomplish everything we wanted with 10-20% of the resources we use in the U.S. and still achieve the same results.

That first day was a challenge for me – trying to pick up and operate in a completely new environment. The instruments had different names (the Leksell rongeur became the “nibbler”), though the scrub nurses spoke English, they were more accustomed to speaking in Sinhala, and most importantly we were new to everyone. By the third day, though, the hospital truly started feeling like home. Our final case was a 15 year old girl with severe adolescent idiopathic scoliosis with pulmonary compromise. Dr. Swarnakumar, one of the senior Sri Lankan surgeons, and I started the case, and Dr. Sethi and I performed the instrumentation and correction of the spinal deformity. All throughout, there were two cameramen videotaping the surgery with live feed to the conference room. The observing surgeons asked us questions throughout the case. As I reflect back on my own transformation over those three days, being able to pick up and operate in a completely new environment was an excellent challenge that boosted my confidence as a surgeon. The cases were amazing, some more complex than we would ever experience in the U.S., and



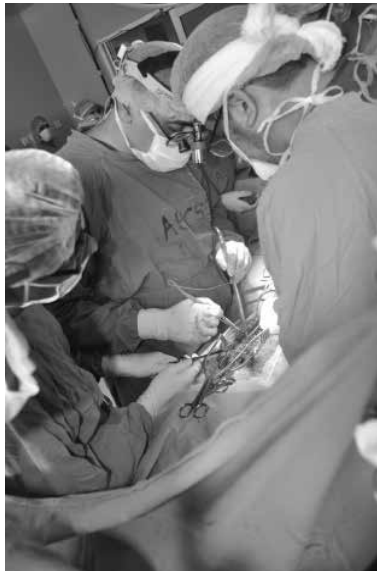Dr. Rajiv Sethi and Dr. Arvind Jayaswal lead rounds on our first day.



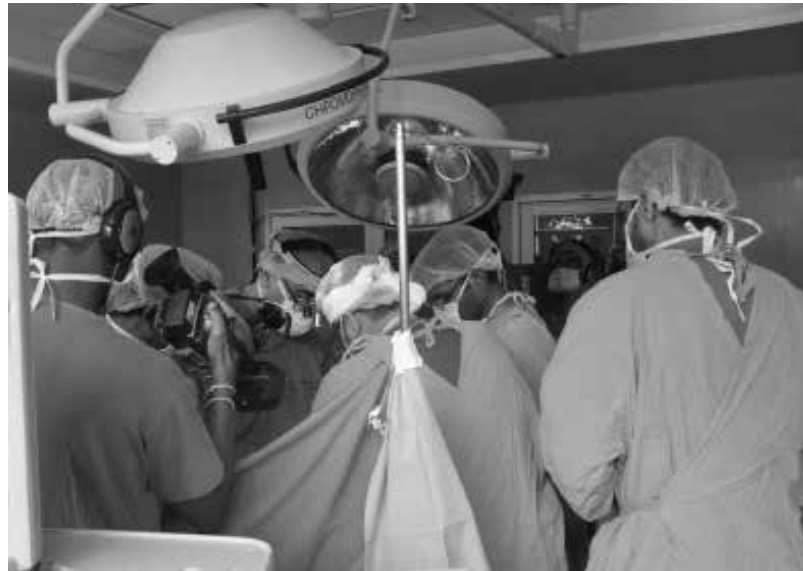Dr. Rajiv Sethi and I perform a lumbar decompression and posterolateral fusion.

incredibly generous it was for him to drive his patient home, he noted that it was a small service compared to Dr. Sethi bringing a whole team from the U.S. to perform free surgery. This really struck me because so often in the U.S. healthcare system, we find ourselves complaining – about uncompensated patient phone calls, wasted time in the operating room. Here was a man who took the call to service as a doctor, as a humanitarian, to the supreme.

Truly, my time in Sri Lanka was transformative. I grew as a surgeon, gaining new confidence in my own abilities, while reconnecting to my roots and reminding myself of the true humanitarian side of medicine, why many of us decided to become physicians in the first place. I have a new appreciation for what we have in the US – and many thoughts on what



Dr. Rajiv Sethi and Dr. Arvind Jayaswal demonstrate the Seattle Spine Team Approach to complex spine surgery with two attending surgeons in this 16 year old patient in Sri Lanka with adolescent idiopathic scoliosis.



Dr. Rajiv Sethi, Dr. Arvind Jayaswal, and I operate together on a 15 year old girl with idiopathic scoliosis, assisted by an extensive team of Sri Lankan surgeons and staff. Live transmission of the surgery via two cameras allowed the Sri Lankan orthopaedic and neurosurgical community to engage with us during the surgery.

the patients and their parents were enormously grateful for the treatment they received.

Perhaps most importantly, however, this trip gave me the opportunity to meet some amazing people – people who reminded me why I decided to become a physician in the first place. On the final day, as we were rounding through the 3000 bed hospital, Dr. Udai De Silva, one of the other senior Sri Lankan surgeons, brought us to the patient for whom we had performed an

anterior cervical discectomy and fusion for severe spinal cord compression the previous day. The gentleman was incredibly grateful and told us how he had come from the other side of the island – a multiday journey – just to have the surgery done. Dr. Udai told me he would personally drive the patient home after his hospital stay as it was on his way to his parents' house and the ambulance service only picks patients up from the hospital once every three weeks. When I commented how

the Sri Lankans do better (including smiling more!). This experience will undeniably shape my own career as a spine surgeon.

Note

Vijay Yanamadala, MD is a complex spine surgery fellow at Virginia Mason Medical Center and neurosurgery resident at Massachusetts General Hospital. Rajiv Sethi, MD is Clinical Associate Professor of Health Sciences at the University of Washington.

Orthopaedics In Bhutan

Samuel R. Baker, MD

Since 2005 I have had the privilege of being a frequent volunteer orthopaedic surgeon in Bhutan through Health Volunteers Overseas (HVO). My assignments have been four weeks to four months.

Bhutan is a small Himalayan country north of India with a population of approximately 900,000 people, mostly subsistence farmers. Previously a kingdom, it is now a constitutional monarchy. Buddhism is the main religion and Dzongkha is the official language, although English is the workplace language. Its main sources of income are hydroelectric power exported to India and international tourism promoted in-country.

Bhutan's health care system is one payer, the government, so everyone has free health care. If one's medical problem is too complicated for Bhutan's system, the patient may or may not be transferred out of country to India or Thailand at governmental expense. The main referral hospital is in Thimphu, the capital city, and is multi-disciplinary with approximately 300 beds. Orthopaedics has a forty bed ward of five rooms with eight beds in each room. Often septic and non-septic patients are in the same room as dictated by bed availability.

Briefly, the thrust of HVO's programs

is to improve health care in developing countries through education and training of in-country health care professionals. Orthopaedically in Bhutan, our primary mission is to teach technicians in a three-year structured orthopaedic program. The purpose is to improve the orthopaedic care throughout the country. Typically there are two students per year. These students, male and female, have at most a high school education and usually come from small farming villages throughout Bhutan. We educate them in the basics of orthopaedics in the class room, at bedside rounds, in clinics, and in surgery. For example, they learn to examine/assess patients, do injections, suture simple wounds, set simple fractures, put on casts, and both circulate and scrub in surgery. At the end of their formal training they will spend a year or two at the main referral hospital in Thimphu. Then they will be posted to either a small city hospital or a rural health clinic where they manage the simpler orthopaedic problems and refer the more complicated problems to a main hospital. This is a lot of responsibility for these young orthopaedic technicians.

There are now five in-country Bhutanese orthopaedic surgeons, whereas ten years ago there was only

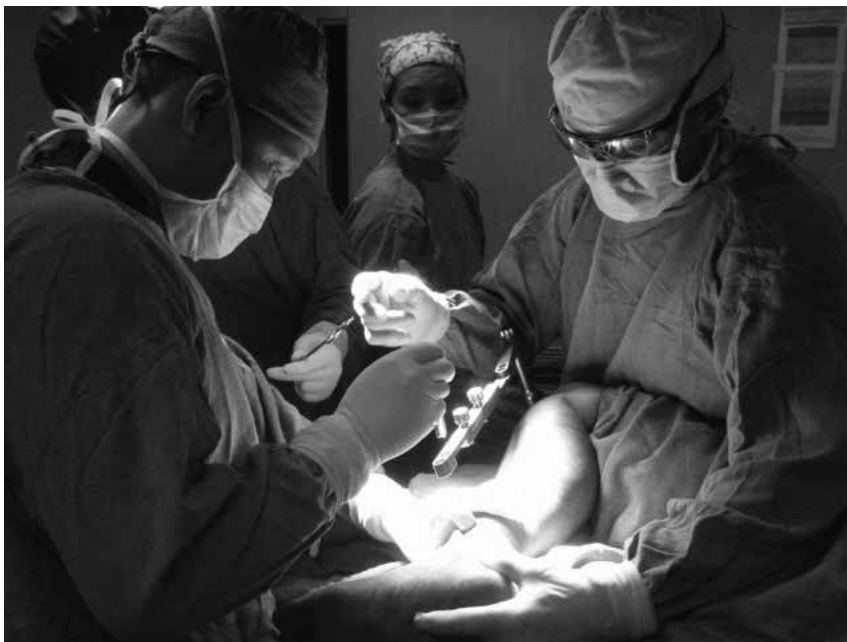one. They attended medical school in Sri Lanka, India, or Thailand and took their residency in Thailand. Some have had specialty training beyond residency, for example a six-month spine fellowship in Japan. I have worked extensively with them on the wards, in the clinics, and in surgery. We have a fine exchange of ideas and learn a lot from each other.

The typical orthopaedic workweek is Monday through noon Saturday with several clinical days and surgical days, sometimes the same day. The scheduled workday is from 9am to 3pm as health care workers are government employees and theoretically have the same workhours. However, emergencies negate that concept and orthopaedists are not paid for any over-time patient care, such as fixing an open femoral fracture in the middle of the night.

Often all the day's surgical trauma cases cannot be finished in the 9am-3pm time frame and so get delayed to another day unless an open fracture.

Patient record keeping is quite different than in the USA in that patients keep their charts and x-rays, both out-patient and in-patient. The patient brings these records when he/she comes for treatment, at least that is the protocol, which is not always the reality. The records are hand written by the hospital staff, doctors included, and are brief. This includes operative notes. Basically the system allows for an orthopaedist's time to be spent in approximately 85% direct patient care and 15% associated paper work. This is certainly a delight compared to our USA system where we have to document ad nauseum.

Trauma and infections comprise the bulk of the orthopaedic problems in Bhutan. Long bone fractures of all kinds, open and closed, are typical along with peri-articular and intra-articular fractures. Delay of treatment occurs due mainly to transportation issues. For example, an injured farmer may need to be transported by horse or stretcher on a trail from his village to the nearest road where a vehicle is available. This might take several





days. Or he may choose to have his fracture treated by the local healer, bone setter, but later require more sophisticated orthopaedic care. Thus, open fractures often become infected. In general, appropriate antibiotics are available, but not always. Delayed unions, nonunions, and malunions are not unusual. As more rough roads are built closer to villages, treatment delays are fortunately diminishing.

Surgically, there is usually enough basic orthopaedic equipment, such as drill bits, screws, non-locking plates, and external fixation sets. However, more sophisticated orthopaedic surgical equipment is lacking, such as locking plates. DHS and DCS sets are available. The SIGN system of intramedullary nailing with interlocking screws is used preferentially for the appropriate fractures of the femur and tibia. Hemi-arthroplasty for a femoral neck fracture can be a challenge for lack of appropriate head size. Improvisation is frequently the orthopaedic surgical norm. As operating room sterility is not optimum, total joint arthroplasties are not done. Nurse anesthetists and anesthesiologists perform both regional and general anesthetics. There is an intermittently functioning C-Arm in the operating theater of the two main hospitals. Thanks to India, there are now both a MRI and a CT scanner in Bhutan's main referral hospital. Laboratory and Pathology services are good.

Pediatric hematogenous

osteomyelitis and septic arthritis are common. The children often present with untreated late complications such as 1) a dislocated septic hip with associated femoral head destruction or 2) pathologic fracture of a tibia from chronic osteomyelitis with draining sinus, involucrum, and sequestrum.

Spinal fractures and spinal fracture-dislocations with or without paralysis at all levels are unfortunately all too common. These are mostly from road traffic accidents and construction accidents. Many of these problems are now being treated by surgical stabilization but casting is also being done. Spinal tuberculosis is typically treated with a standard antibiotic regimen with drainage of cold abscesses as needed. Acute and chronic tuberculous cases are a reality with increasing cases of multi-drug resistance.

Although acute cases of leprosy are rare now in Bhutan, there are many chronic cases with chronic sequelae, such as deformities of the hands and feet. Sometimes amputations are required, for example a below knee amputation. These patients have access to good prosthetics in-country.

This is a short overview of my orthopaedic experience in Bhutan with Health Volunteers Overseas. It has been a privilege to help treat the orthopaedic patients and be involved in teaching orthopaedics there. I hope I have made some small contribution to improving the orthopaedic care of Bhutanese

people. We orthopaedists have a gift which can help others in developing countries. I would encourage you to do some volunteer orthopaedics overseas. In my opinion, your orthopaedic career will not be complete unless you do so. I also would encourage the Orthopaedic Department of the University of Washington to include an overseas rotation as a regular part of the orthopaedic residency. My thanks to my long-time friend and co-resident colleague, Dr. Ted Wagner, for asking me to contribute this essay.

Note

Dr. Samuel Baker is a retired orthopaedic surgeon previously in private practice in Port Angeles, WA. He is an alumnus of our department graduating in 1974.

Overseas Experiences in Nicaragua

Gregory A. Schmale, MD

In the late 1990s as a senior resident at the University of North Carolina, I joined a group of academic and private practice orthopaedists traveling to Nicaragua to explore the possibility of establishing a connection with a hospital and residency training program in the city of Leon. The objective was to develop a partnership in which resident education could be reinforced, a pipeline for basic supplies and tools established, and dialogue of treatment techniques and approaches for the common musculoskeletal challenges seen in pediatric and adult populations begun. Out of this exploratory trip grew COAN: Cooperación Ortopédica Americano Nicaragüense, a Raleigh NC-based 501-3c that now supports three to four weeklong missions per year. Surgeons, nurses, therapists, anesthesiologists, residents, and community volunteers from across the United States come together to support COAN's overarching goal: "Helping Nicaraguans help themselves."

I began regular annual trips back to Nicaragua with COAN eight years after that first visit, and the experiences continue to be some of the most positive and rewarding of my professional career. Because my first trip--offered to me almost expense-free as a resident--was so positive, I've tried to match that opportunity for our UW

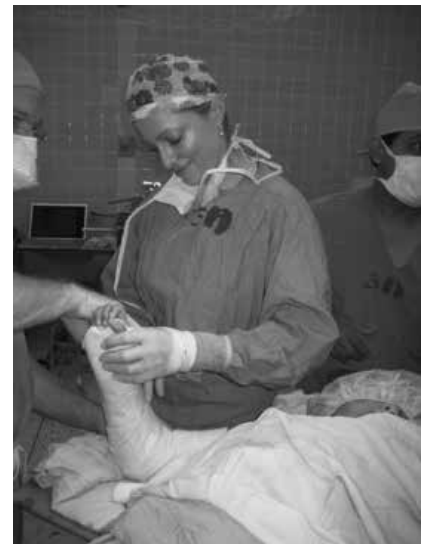orthopaedic residents. To date, Annie Links, Brian Daines, Emily Squyer, Brian Gilmer and Amanda Roof Larson have each sacrificed a week of vacation to accompany me on one of these adventures. Together we have totes full of donated equipment, held clinics using Spanish with a wide variety of proficiency, operated with and alongside our Nicaraguan colleagues, and enjoyed evenings of Nicaraguan rum and cerveza in Leon, Managua, and on the Pacific beach of Poneloya.

Brian Gilmer had traveled to Nicaragua during medical school so was eager to return as a resident. On our joint venture, Brian and I found ourselves planning, templating, and performing a valgus producing osteotomy for a complex nonunion using plain films and by sorting through the available implants. Brian reflected, "The opportunity increased my awareness and stimulated a resourcefulness which continues to serve me well. I also learned the humility that comes with not having a solution for every problem. I saw rare problems and pathology that for me would otherwise only have existed in a textbook. But perhaps most importantly, I developed a camaraderie and a deep respect for my international colleagues and a better sense of the global family of orthopedic surgeons."

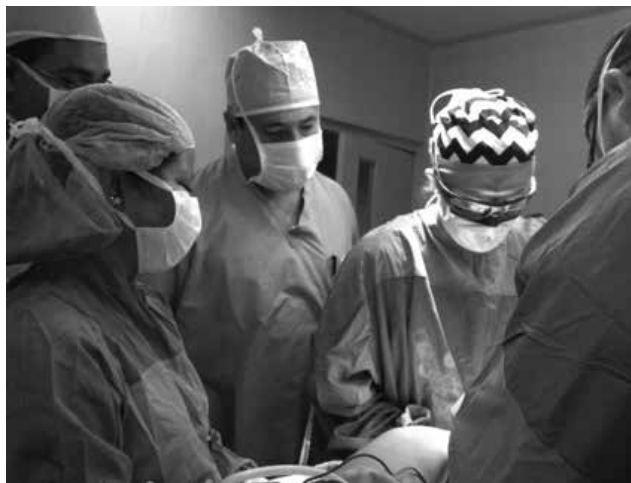For Amanda Roof Larson, time

spent in Nicaragua made her that much more appreciative of the resources available to her at the University of Washington. She enjoyed most talking and working with Nicaraguans at the same stage in their orthopaedic training. In her trip reflections, she wrote, "Dr. Schmale, COAN and their colleagues in Nicaragua have a great working relationship that involves learning and teaching on both sides."

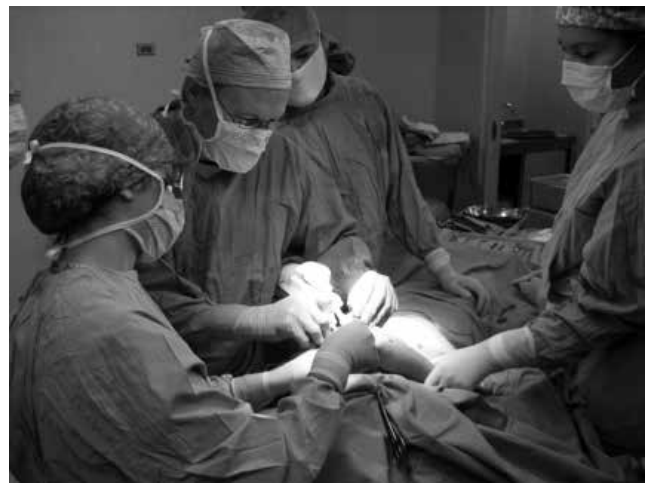Brian Daines traveled to Nicaragua during his 4th year of residency and



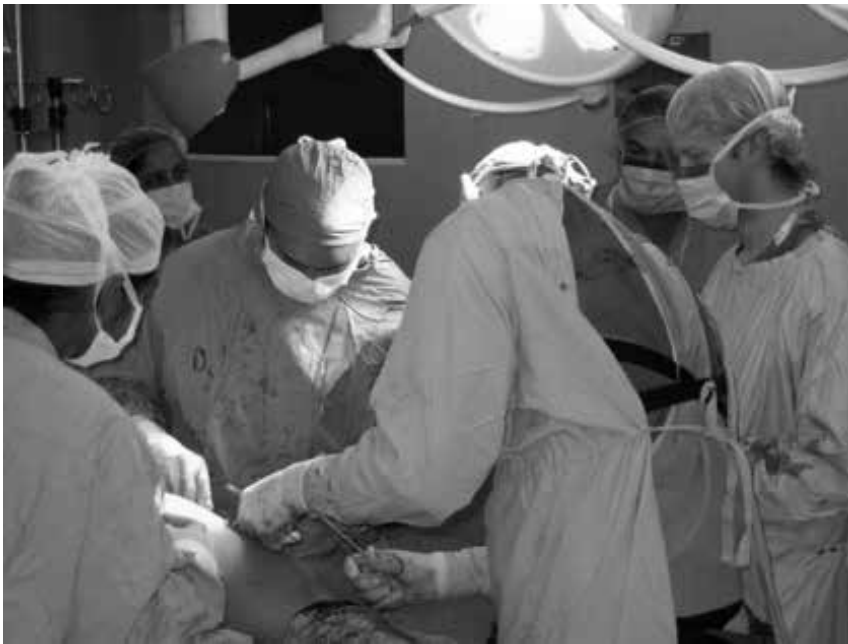Dr. Links applying a post-operative splint after distal humeral osteotomy.



Dr. Amanda Roof Larson leading the residents through bilateral gastrocnemius recessions.



Drs. Squyer, Campion and Pastorius working on an elbow malunion.



Dr. Gilmer and residents performing a proximal femoral osteotomy.



Drs. Rios, Schmale and Daines out on the town after a challenging day in the OR.

described the trip as a pivotal moment in his training. "It helped me step outside of myself and see a world in need. It gave me perspective and allowed me to see things as they truly are. We are so blessed to live in America. . . I have continued to participate in international medicine through an organization called Operation Walk, doing joint replacements in Panama, Honduras, and Guatemala. This service is easily the most important, the most rewarding, and the most fulfilling aspect of my career. . . In an era of physician burnout, I would argue that early participation in international medicine can re-invigorate

the flames of charity that brought many of us to medicine in the first place. "

UW Medicine And Intercollegiate Athletics: Partnering To Help Husky Athletes Compete At The Highest Level

Christopher Y. Kweon, MD and Albert O. Gee, MD

The University of Washington has long been one of the country's premier academic institutions and a destination providing student athletes the opportunity to perform on the grandest stage in college athletics. UW Medicine and the Department of Orthopaedics & Sports Medicine has partnered with the Department of Intercollegiate Athletics for many years to keep student athletes healthy and competing at the highest level.

During the renovation of Husky Stadium in 2013, the University of Washington Sports Medicine Clinic, formerly located inside Hec Edmundson Pavillion, was moved and transformed into a brand new 30,000 square foot state of the art Sports Medicine Center inside of Husky Stadium. In conjunction with the departments of Family Medicine and Rehabilitation Medicine, the Department of Orthopaedics & Sports Medicine began seeing patients at the opening of the new stadium and offering comprehensive care for athletes of all ages and levels in the community. With the Sports Medicine

Center having the capability to provide a vast array of diagnostic and therapeutic interventions ranging from radiology, physical therapy, bracing and orthoses, injections and surgery; patients looking for all-inclusive Sports Medicine options and treatment now have a single location to obtain the help they need to return to sports and an active lifestyle.

The creation of the Sports Medicine Center at Husky Stadium has further strengthened the relationship between UW Medicine and the student athletes at the University of Washington. Fourteen certified athletic trainers (ATC) help oversee the medical care of 625 student athletes on 22 varsity sports teams and are responsible for injury prevention, evaluation and management of acute injuries, coordinating medical and surgical services, and guiding rehabilitation protocols for Husky athletes. At any given time, up to 30 undergraduate student volunteers, three graduate interns, two dieticians, and two sports psychologists provide additional support while five primary care physicians all play an important

role in managing the non-operative injuries that are sustained during practice or competition.

When surgery is needed for a Husky athlete, Albert Gee, MD and Chris Kweon, MD help provide the next level of care. As many as 75 procedures are performed each year on Husky athletes and the Department of Orthopaedics & Sports Medicine strives to provide the highest quality surgical care to this elite subset of athletes at the UW Sports Medicine Center. "We depend on many of our partners in the orthopaedic department to help care for our Husky athletes", says Dr. Gee. "While the majority of sporting injuries that require surgery are performed by sports surgeons using minimally invasive or arthroscopic techniques, the subspecialty strengths in other divisions such as hand or trauma at the UW allow us to totally optimize the surgical care of the athlete and ensure they are receiving the best care possible. That is one of the major advantages of partnering with and receiving surgical care from an orthopaedic department like ours."

John Ross and Kevin King, two members of the University of Washington football team, demonstrate how Intercollegiate Athletics and the Department of Orthopaedic Surgery & Sports Medicine partner together to help Husky athletes recover from surgery. Kevin had surgery during his freshman year and after making a full recovery to become an impact player on the Huskies top ranked defense last season, is ready to perform at an even higher level going into his final season. "I feel good," said King. "I feel the best I've ever been. Heading into the season they got me right. Playing football is going to lead to some times of being injured and back in the training room but I know they'll get me right again."

"The relationship we have with UW Medicine and the relationship that all of our team doctors have with the athletic trainers is critical to providing the best



Figure 1: Pictured from left to right in the University of Washington Athletic Training Room are John Ross III, Head Football Athletic Trainer Rob Scheidigger, and Kevin King.




Figure 2: The University of Washington Sports Medicine Center located inside Husky Stadium off the shores of Lake Washington.

care possible to our athletes,” says Patrick Jenkins, head athletic trainer for the University of Washington. “There is so much that goes into helping an athlete through an injury from start to finish and it requires the coordination of multiple members of the medical team and healthcare systems.” The work being done by ATCs behind the scenes is often overlooked but the positive impact on the injured athletes is not. Dr. Kweon, who spent time as an intern athletic trainer prior to going to medical school understands the commitment required to care for elite athletes and the amount of time that all of the athletic trainers put in. “What many people might not appreciate is that caring for athletes is one of the only times that allows for this type of continuity of care,” says Dr. Kweon. “The person who provides preventative care to the athlete is the same person who is right there evaluating them when they sustain an acute injury, and is the same person who guides them through an ever increasingly convoluted medical system if they need tests, treatments or surgeries. They are the same person who works with them through their rehabilitation program and the same person that gets to see them back on the field when fully recovered. Being a part of that when it happens like it’s supposed to is pretty cool.”

After missing the entire 2015 season recovering from surgery, John Ross is excited to compete again this year to complete that circle. “Honestly, I feel stronger and faster now than I did before surgery,” Ross said. He has proven it during the most recent spring Husky combine running the 40 yard dash at a blistering 4.25 seconds. He credits the care he received from the athletic training room staff and medical staff in helping him work his way back. When asked his thoughts about his surgeon Dr. Gee he said, “Man, I think Dr. Gee is amazing. I’ve never had a guy care about me as much as Dr. Gee has. Him and all the trainers are great at what they do, but they’re even better people.”

Working together is a critical part of having success as a team whether it be on the field of athletic competition or in the field of medicine. The University of Washington Department of Orthopaedics & Sports Medicine is committed to working together with UW Medicine and Intercollegiate Athletics to keep Husky athletes competing at the highest level for years to come.

Harborview Medical Center Orthopaedics

Departmental Changes

The 2015-16 academic year brought continued evolution and growth of Harborview's Department of Orthopaedics, which included the successful recruitment of new trauma and spine faculty, continued increases in our clinical volumes and completion of the new resident and fellow workspaces within the hospital, which represented the final phase in the move of our departmental offices.

The most exciting upcoming change will be the introduction of several new faculty members during the next academic year. Jonah Davies, MD, will be returning to Harborview after having completed a fellowship in orthopaedic traumatology here in 2014. After graduating from the prestigious shoulder and elbow fellowship at Washington University in St. Louis the following year, he joined the faculty at the University of Montreal, in his native city, where he had also obtained his medical degree and graduated from the orthopaedic surgery residency. He will not only be a valuable asset to the orthopaedic trauma community in general, but will enhance our clinical and research expertise in the reconstruction of upper extremity injuries. We are also fortunate that Michael Githens, MD will be bringing his enthusiasm and skills to our orthopaedic trauma faculty on a permanent basis once he has

finished his current fellowship here in orthopaedic traumatology. Dr. Githens is originally from California and comes to us with outstanding credentials, having obtained a Bachelor of Science degree from Pepperdine University, followed by first a Masters in Biophysics and Physiology followed by a Medical degree at Georgetown University, before completing his orthopaedic residency at Stanford University. Dr. Githens plans to concentrate on orthopaedic trauma in general, with a dedicated focus on foot and ankle trauma. We are also excited that Haitao Zhou, MD will be staying on as part of our spine faculty after finishing his spine fellowship here at the University of Washington. Dr. Zhou is already a seasoned clinician and researcher, having originally completed his orthopaedic and spine surgery training in China, where he subsequently started his practice as a spine surgeon in Beijing, with a focus on cervical spine pathology. Once he moved to the United States over a decade ago, he initially concentrated on research for several years, amassing over thirty publications, before completing his second orthopaedic residency at Augusta University's Medical College of Georgia. Dr. Zhou will focus his clinical and research skills on both degenerative and traumatic spine conditions. These new faculty members will undoubtedly be valuable assets to our training programs, the local orthopaedic community and most importantly, to the population we serve over the 5-state WWAMI region. Also, I would be remiss to not express my gratitude to Joshua Shatsky, MD for his dedicated and exceptional service to our department and to spine patients in our community as he prepares to pursue a private practice opportunity in Silverdale, WA, where I have no doubt he will elevate the quality of spine care for patients on the Olympic Peninsula.

Medical Center

In addition to the continued emphasis on patient safety and infection control, and the expanding role of pre-determined pathways in improving both the efficiency and effectiveness with which our patient care is delivered, Harborview has begun to dedicate considerable resources to refining our

patient reported outcomes process, in order to better determine the clinical impact of the various treatment options available for orthopaedic conditions. This program is currently being piloted in spine fusion patients, with the goal of eventually expanding it to all orthopaedic patients. Because of the extensive investment in infrastructure required for a program of this magnitude, the support of the medical center has been vital to the project's implementation. As always, our goal is to provide high-quality, cost-effective care to our patients, and access to better information about patient outcomes is a key component of this process.

Clinical Care


Harborview's Department of Orthopaedics has continued to experience yearly growth in clinical volumes, which account for approximately two-thirds of the adult orthopaedic care provided by the University of Washington system. All four of our subspecialty divisions (Foot & Ankle, Hand, Spine, Trauma) increased their clinical volume by between 5 and 15 percent, resulting in an overall increase of about 10 percent. The Trauma Division remains among the best and most influential globally, maintaining Harborview's widely regarded status as one of the world's premier trauma centers. The Foot and Ankle Division provides care for musculoskeletal disorders



Jonah Davies, MD



Michael Githens, MD



Haitao Zhou, MD

of the foot and ankle and podiatric services for diabetic foot care and limbs at risk. The Orthopaedic Hand surgeons collaborate closely with the Plastic Surgery and General Surgery Hand surgeons to provide complex reconstructive treatment of elective as well as traumatic conditions. The Spine Division, which collaborates closely with the Department of Neurological Surgery and the Department of Rehabilitation Medicine, treats the entire spectrum of spine injuries among all patient demographics. The Spine Division has continued to experience the highest growth of the sub-specialties over the past academic year. All four sub-specialties continue to be a key resource for patients and clinicians alike in the WWAMI region.

Leadership

Our faculty have continued to hold key leadership and committee positions within national orthopaedic specialty societies, with Bruce Sangeorzan, MD completing his term as President of the Foot and Ankle Society and Brad Henley, MD beginning his tenure as Treasurer of the AAOS. Reza Firoozabadi, MD has been appointed to the Orthopaedic Trauma Association's Research Committee.

Awards

Doug Hanel, MD, our Director of Resident Education for almost twenty years, received the Washington State

Orthopaedic Association's Lifetime Achievement Award for the manner in which his teaching and clinical care has exemplified the WSOA mission of advancing the highest quality of musculoskeletal healthcare.

Research

The Harborview orthopaedic faculty have contributed over sixty peer-reviewed publications in their respective areas of expertise to the orthopaedic literature over the course of the past academic year. There continue to be approximately 70 retrospective research studies and a dozen prospective studies in progress within the Orthopaedics Department at Harborview Medical Center. As mentioned above, emphasis is increasingly being placed on evaluating patient outcomes in the context of cost and resource expenditure. Harborview's participation in the Major Extremity Trauma Research Consortium (METRC), a combined civilian and military clinical trial network funded by the Department of Defense, which focuses on severe extremity injury, infection, limb impairment and loss continues to evolve. Under the direction of the Harborview site Primary Investigator, Reza Firoozabadi MD, our department's Director of Clinical Research, we have become one of the major contributing centers to this ambitious multicenter project. We have been recruited to participate in several prospective spinal cord injury multicenter clinical trials, one or more of which we anticipate will begin in the near future.

Teaching

Harborview remains the busiest teaching hospital in the University of Washington's Department of Orthopaedics. 14 orthopaedic residents, including residents doing their trauma rotation from Madigan Army Medical Center, and fourteen fellows are distributed among Harborview's four orthopaedic subspecialty divisions, in addition to additional visiting residents and fellows. Teaching opportunities abound, as our trainees are able to choose from approximately a dozen different didactic conferences per week and exposure to practical cadaver-based workshops in Harborview's Institute for Simulation in Healthcare lab, in addition to the high volume of hands-on teaching that occurs in the

operating rooms, inpatient wards and outpatient clinics.

Our faculty members have remained instrumental in Continuing Medical Education projects world-wide, having managed to participate in a combined total of over 100 national and international courses and countless hours of local didactic teaching to students, paramedics, allied health professions, residents, fellows and other practicing surgeons over the past year, as well as having published over thirty textbook chapters, despite maintaining busy clinical practices. Harborview continues to host visitors from throughout the globe year-round. In the past academic year, over 50 visitors have traveled to Harborview to observe our approach to the treatment of orthopaedic conditions. Harborview's role as a worldwide leader in the treatment of orthopaedic conditions continues to be a source of motivation and pride for the faculty.

Carlo Bellabarba, MDCM
Professor & Chief of Orthopaedics
Harborview Medical Center

Seattle Children's Hospital Orthopaedics

The Department of Pediatric Orthopedics and Sports Medicine is one of the largest surgical departments at Seattle Children's Hospital.

- Our faculty are staffed by the Division of Pediatric Orthopedics and Sports Medicine from the University of Washington. This is a diverse group of 14 pediatric orthopedic surgeons, many of whom have expanded fellowship training in spine, foot and ankle, tumor, sports medicine, skeletal dysplasia and upper extremity issues.
- A team of 5 pediatricians complement the department with subspecialty training in pediatric musculoskeletal health and sports medicine, including concussion treatment and pain disorders.
- Our 7 certified physician assistants and 4 nurse practitioners have in-depth experience in children's musculoskeletal health, improving the speed of access to care.
- The Sports Medicine Program includes 27 certified athletic trainers who provide coverage for 27 area high schools and over 100 community athletics events. This combined coverage results in over 57,000 treatments of injuries in our schools and communities.

At the hospital, there are specialty clinics for skeletal dysplasia and metabolic bone disorders as well as complex spine, clubfoot, arthrogryposis, concussion, neuromuscular disease, hand and upper extremity and sports medicine.

Pediatric musculoskeletal trauma continues to grow, and the emergency room is staffed 365 days/year, 24 hours/day to provide both trauma coverage and evaluation for musculoskeletal infections in children.

With over 38,000 outpatient visits per year, the Pediatric Orthopedics and Sports Medicine Clinic is the busiest outpatient clinic at Seattle Children's. Additionally, our surgeons completed 2,212 cases last year.

Seattle Children's Hospital is currently recruiting both a pediatric spine surgeon and a sports medicine surgeon.

Below we highlight several exciting programs within Orthopedics and Sports Medicine.

Suzanne M. Yandow, MD
Chief Medical Director
Orthopedics and Sports Medicine

Seattle Children's Sports Medicine Program

The Seattle Children's Sports Medicine program includes a pediatric sports orthopedic surgeon, four sports medicine pediatricians, one physiatrist certified in sports medicine, an adolescent medicine physician, two physician assistants, 27 certified athletic trainers and over 20 sports

physical therapists.

Our vision is to:

- Provide excellent care to the whole athlete as a collaborative team, serving all children and adolescents in play and sport. We include diverse populations and all levels of ability.
- Perpetuate a scope of care that embodies a dedication to injury prevention, treatment, rehabilitation and performance development.
- Serve the Pacific Northwest through cutting-edge research and advocacy in education and outreach.

Our providers are located at multiple sites including Seattle, Bellevue, Mill Creek and South Sound campuses. We are part of the collaborative Seattle Sports Concussion Program and see over 1,200 concussion-related patients annually. Our pediatric sports orthopedic surgeon performs over 200 sports related surgeries annually, including 80 ACL reconstructions. Our athletic trainers are located at 27 greater-Seattle area high schools, providing excellent care for our student-athletes. They are also involved in numerous outreach activities and events, including Girls on the Run, Special Olympics and UW sports camps. We are engaged in collaborative research and provide sports medicine coverage at local high schools as well as at international events including USA Track and Field and USA Swimming.

Our program may be more



appropriately called the activity, play and sports medicine program. Although we currently provide primarily musculoskeletal care, we look forward to expanding our program to include other aspects of being a young, physically active person. This includes sports-related issues involving fatigue, performance, Female Athlete Triad, pulmonary, cardiac and dermatologic symptoms. In addition, we would like to expand upon our sports nutrition services, build our athletes with disabilities program and continue growth in pediatric sports medicine research.

A child's "job" is to learn and play. Our care involves creating an individualized detailed plan to not only return our patients back to physical activity but also to address factors that may have predisposed them to injury and help prevent them in the future. We work collaboratively to get our patients back to what they enjoy most—play.

Monique Burton, MD
Director, Sports Medicine

Hand and Upper Extremity

The Hand and Upper Extremity Service at Seattle Children's continues to grow. In the last year, the 4 providers of our team saw over 2,900 patients with hand and upper extremity conditions ranging from congenital differences and neuromuscular disorders to brachial plexus injuries and trauma. Patients from across the region are able to get outstanding care from a multidisciplinary approach that includes members from pediatric orthopedics, plastics, rehab medicine and occupational therapy. Not only do we provide clinical and surgical care for our patients, we are also able to offer social support through our Limb Difference Social Group. This group gets together twice yearly so that our patients and families can meet each other outside of the clinical setting. Our summertime event at the Mountaineers Club has proven to be a huge success. The children and their families are taught to rock climb by Outdoors for All. There is nothing more satisfying than seeing the smile on one of our children when they reach the top of the wall or sit in the harness for the first time.

Our program also received national recognition this past year. Based on our work with our local upper limb difference registry that was started

2 years ago, our program has been asked to participate in the CoULD (Congenital Upper Limb Difference) National Registry. This important research is aimed to help us better understand some of the rare conditions that we treat as well as enable us to examine patient-reported outcomes. Through research, social support and medical treatment, we continue to strive to improve our patients' lives.

Suzanne E. Steinman, MD
Pediatric Orthopedic Surgeon

Skeletal Health Program

The skeletal health program has experienced tremendous growth over the last 10 years. The program provides comprehensive care for children with skeletal dysplasias, metabolic bone disease, syndromic conditions with significant orthopedic manifestations and early-onset scoliosis. Our mission is to provide comprehensive medical and surgical care for patients with skeletal dysplasias and metabolic bone disease via: 1) Clinical Care Home: comprehensive care including diagnosis, management and care coordination; 2) Consultative Services: opinions regarding bone fragility and non-accidental trauma, prenatal diagnosis and out-of-state consultations; and 3) Research: to promote skeletal health clinical care.

Our staff includes two geneticists (Ian Glass and Stephanie Wallace), three orthopedic surgeons (Michael Goldberg, Klane White and Maryse Bouchard), an endocrinologist (Kathryn Ness), three radiologists (Shawn Parnell, Stephen Done and Theresa Chapman) and two nurse practitioners (Dawn Earl and Susan Hale). The clinic is further supported by Seattle Children's Hospital specialists in neurosurgery, pulmonary medicine and upper extremity surgery. Care is coordinated by a dedicated family services coordinator, making the often complex scheduling for these patients and their families much easier.

Our IRB-approved Skeletal Dysplasia Registry, which focuses on the functional health of affected individuals, now has 566 enrolled patients. We are actively collaborating with our colleagues in the Division of Medical Genetics in the identification of novel genes via exome sequencing. In clinical research, we are pursuing participation

in a multi-center registry and are leaders in the Skeletal Dysplasia Management Consortium (www.skeletaldysplasia.org), an international think tank devoted to the optimization of clinical care for patients with skeletal dysplasias.

Klane White, MD
Pediatric Orthopedic Surgeon

Certified Athletic Trainers

The Seattle Children's Hospital Athletic Training Program began in 2008. Since that time, the program has expanded into 13 school districts covering 27 high schools and over 100 different community organizations in the Puget Sound area. The athletic trainers work with athletes, coaches and parents to encourage youth to take part in sports and remain safe when they do. They encourage young athletes to engage in an active lifestyle and strive to keep them in the game by making sure they are well prepared for activity and properly treated when injuries occur.

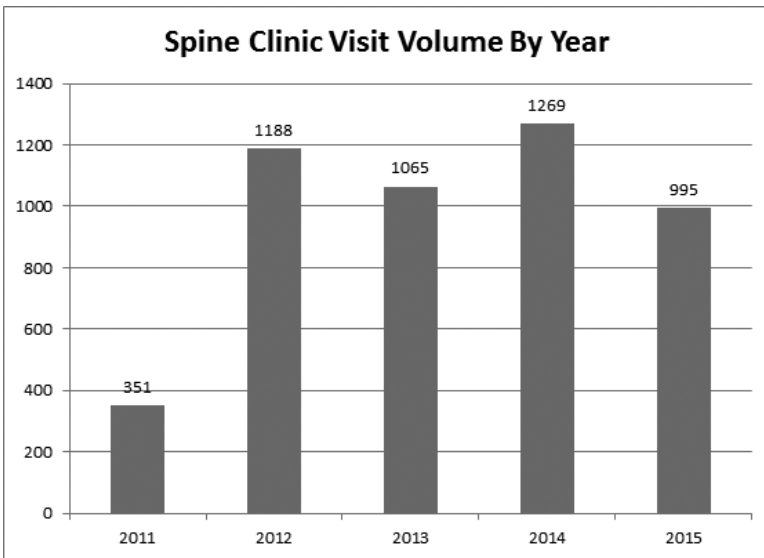
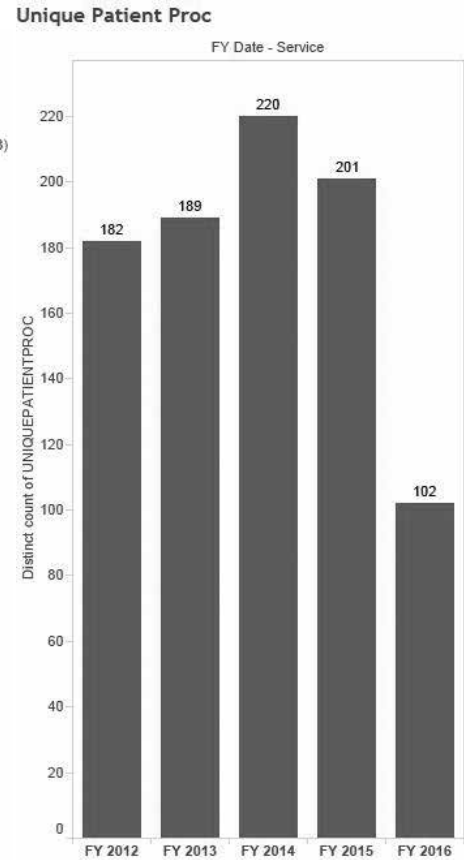
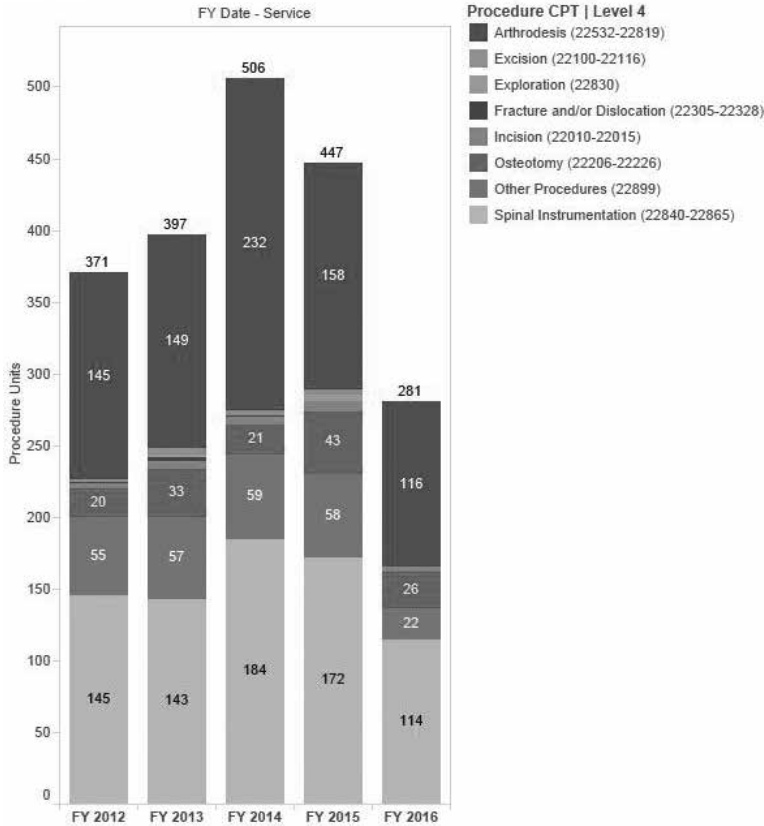
Athletic trainers are experts at recognizing, treating and preventing musculoskeletal injuries, especially during play. They provide immediate treatment and refer teens and parents for additional care when needed. The SCH Athletic Training Program is also part of the Seattle Sports Concussion Program. Athletic trainers are qualified to recognize and manage concussion and can be a valuable resource on the field of play by determining when an athlete can safely return to play.

While working in the local high schools, the SCH athletic trainers provide on-site medical coverage for practices and most home events at each school. Working with the school's athletic directors, the athletic trainers establish appropriate care and coverage needs. Over the past year, the SCH athletic trainers have assessed over 15,000 injuries in the high schools and provided over 57,000 treatments.

Andrew Little, MA, LAT, ATC
Athletic Training Supervisor

The Spine Program at Seattle Children's

Our early onset scoliosis program is emerging as a national leader in the care of these complex patients. Dr. Klane White from Orthopedics and Dr. Gregory Redding from Pulmonary Medicine are members of the Children's



Spine Study Group. They are leading the study of pulmonary disease in thoracic insufficiency disorders. We received a \$30,000 grant to study the role of pulmonary disease in surgical outcomes in the treatment of early onset scoliosis. This program has been merged with our study of spinal deformities affecting patients with skeletal dysplasias, a program for

which we have gained international recognition.

In the last year, we have placed our first 10 magnetic growing rods for treatment of early onset scoliosis. Previous growing rod techniques required repeat operations every 6-9 months to surgically lengthen the rods to promote continued spinal growth and maintain correction of spinal deformities

in young children. The magnetic growing rods allow lengthening to be performed without anesthesia, in the clinic, thus avoiding a large number of planned and unplanned surgical interventions.

The Mehta Casting program was established in 2015 for treatment of early onset scoliosis. For infants with scoliosis, this unique technique involves a combination of traction and manual derotational molding of a body cast, allowing for correction of significant deformities. This requires specialized training and a special casting table. Dr. Mark Dales is leading this important program, improving outcomes for very young children with scoliosis to avoid open surgical treatments.

We also participated in a national multicenter study on the culture of safety for institutions performing pediatric spinal deformity surgery: "Safer Outcomes for Pediatric Spinal Surgery (SOPSS): A National Spine Center Collaborative Agency for Healthcare Research and Quality." We were identified as a leading institution in our culture of safety for children having spinal deformity surgery. This was made possible by the hard work of all our surgeons, nursing and

administrative staff as well as the hospital's commitment to a clinical standard work (CSW) pathway. This includes preoperative and postoperative standardized ordersets, checklists and monitoring of outcomes on a dashboard updated quarterly. The process has led to lowered instrumentation costs, surgical site infection rates and average length of stay. Ongoing efforts to improve cost and outcomes are enabled through this program.

Through the generosity and technical foresight of leadership at SCH, we received a large grant from PACCAR to establish a state-of-the-art orthotics and prosthetics lab. This lab will enable us to make cutting-edge scoliosis braces and prosthetics using the most modern and technically advanced methods available. This lab will include 3-dimensional surface imaging and a robotic sculpting machine to enable rapid and perfectly fit custom devices for our children.

Clinical Volumes

The Spine Program has experienced rapid growth over the past 7 years. On the previous page is a graph of the surgical volumes of procedures performed related to the spine over the past 5 years. Note that volumes since 2014 have been significantly affected by the loss of 1 of our spine surgeons, a temporary leave of absence by another surgeon as well as staffing and access issues within the SCH Operating Room. 2016 volumes shown are year-to-date and should approximately double by fiscal year end.

Walter F. Krengel III, MD
Chief, Pediatric Spine

Research Program

With almost 30 publications and 5 abstracts accepted at the Pediatric Orthopedics Society of North America annual meeting alone, the faculty of the Department of Orthopedics and Sports Medicine at SCH continues to demonstrate its commitment to research.

We continue to receive recognition in multi-center clinical trials and registries such as the FAB 24 clubfoot study (Dr. Mosca), the Children's Spine Foundation study (Dr. White) and the BraIST II study (Dr. Krengel). Dr. Steinman has been invited to participate as the site PI in a national hand registry (CoULD). She runs a robust clinical

registry at SCH in collaboration with the hand team, which gained her national recognition. Additionally, Dr. Lindberg will serve as a site PI for the Regional Variation in Pediatric Musculoskeletal Infection Multi-Center Study; and Dr. Schmale will be the site PI for the ABOS PRISM Pediatric Knee Registry.

Our registries continue to grow. With more than 500 patients, Dr. Conrad's Sarcobase Registry collects functional data in children with bone and soft tissue tumors, yielding several publications this year. The Skeletal Dysplasia Registry has more than 600 entries. This year Dr. Goldberg and Dr. White convened an international panel to determine the best peri-operative practices for children with skeletal dysplasia.

Our efforts in implementing clinical pathways and commitment to quality improvement have produced new research studies. Dr. Conrad's Intraoperative Sarcoma Navigation study and Dr. Krengel's Spine at Risk study were presented at the NSQIP national meeting last summer.

This year, Dr. Mark Dales was the recipient of a Seattle Children's Academic Enrichment Fund grant for his randomized, controlled trial on the treatment of toddler's fractures. The study compares the use of cast vs. a removable boot in this fairly common childhood trauma.

We continue our efforts to secure external funding. The Sports Medicine team has recently applied for an OREF grant in youth injury prevention. With Dr. Schmale as the PI, the study will look at the efficacy of an injury prevention program in high school cross-country runners. Finally, Dr. Yandow collaborated with the Cerebral Palsy Research Network in a PCORI application for children with cerebral palsy.

It is our goal to strengthen our involvement in outcomes research and continue to increase the national recognition of our research program.

Viviana Bompadre, PhD
Research Manager

Pediatric Oncology

The division of pediatric orthopedic oncology continues several clinical projects evaluating limb-sparing surgical outcomes and the evaluation of surgical tumor margins utilizing

navigation in limb-sparing surgery.

Current efforts are underway to establish a multidisciplinary collaboration for intraoperative navigation (SCH Hanson Innovation Project) of tumor margins at Seattle Children's with the Department of Radiology and the Research Institute. Recent publications regarding the intraoperative navigation program and navigation accuracy have established a new registration system for the current Stryker navigation system. We have hopes to collaborate on 3-D fabrication models for extremity and pelvic implants in the future. Clinical assessment of limb salvage activity using Fit Bit monitors also continues, showing good correlation with patient-reported outcome assessments.

In another collaboration with the Intervention Radiology Department and the Vascular Anomalies Group, we are collecting data for results of a new method of treating vascular malformations. This involves using a combined procedure of percutaneous glue embolization and immediate surgical excision.

Abstracts presented at recent national and international meetings include the following topics: Radiographic assessment of uncemented oncologic stems (MSTS/ISOLS Oct. 2015); Standardizing surgical bony margins with intraoperative navigation (MSTS/ISOLS Oct. 2015); Challenges of physis fixation in pediatric limb salvage (MSTS/ISOLS Oct. 2015); Success and function with pelvic resections (MSTS/AAOS March 2015); Joint-sparing resections in pediatric limb salvage (AAOS/MSTS March 2016).

Ernest U. Conrad III, MD
Antoinette Lindberg, MD
Oncology

University of Washington Medical Center and Northwest Hospital Orthopaedics

The University of Washington Medical Center and Northwest Hospital are grouped together in this report due to their geographic proximity and the flow of faculty back and forth between the two medical centers. In addition, faculty at both hospitals care for a similar population of patients and problems.

At the UWMC we have robust programs in upper extremity, sports, tumor, general orthopaedics and we still have a small adult reconstruction program. In each of these programs the focus is on complex cases that are best handled in an academic center. In fact, our orthopaedic case mix index, a national measure of complexity of care, has continued to increase. We have one of the highest measures of complexity in the University Health Systems Consortium, a group consisting of the nation's premier academic medical centers. Despite this high case mix index our infection and mortality rates remain lower than expected.

At NWH we have focused on adult reconstruction, geriatric fractures and hand surgery. Dr. Robert Clawson continues to lead our efforts to develop an evidence-based and pathway directed surgical fragility, "Strong Bones" fracture program. Dr. Clawson will retire from surgery this year but fortunately has agreed to stay on as a non-operative consultant who will assist in surgery, ED consults and inpatient care. Steve Kennedy, MD, uniquely dual-trained with Hand and Shoulder & Elbow fellowships, continues to care for patients with a broad spectrum of upper extremity conditions. Sarah Beshlian, MD continues to partner with Dr. Kennedy in handling NWH hand call and taking care of general hand cases. The combined Hand team is led by the indefatigable Dr. Jerry Huang. Jerry covers both UWMC and HMC and has become a highly sought after national figure in hand and upper extremity surgery.

Adam Sassoon, MD and Navin Fernando, MD are both becoming increasingly busy and taking care of challenging total joint cases from around the region. I want to acknowledge the expert help of Dr. Akbar Ziaei. Akbar is

an orthopaedic surgeon trained in Iran. While his wife is pursuing her radiology fellowship at the UW, Dr. Ziaei has been assisting us during joint replacement surgery at NWH. We are fortunate to have such a talented "assistant" and are grateful for his steady support through complex cases both short and long. Dr. Fernando is leading our efforts to adapt to the new era of "alternative payment models" such as bundled pricing. In the past year Dr. Sassoon was chosen to participate in the AAHKS Health Policy Fellowship. The goal of this program is to provide the Fellow the requisite exposure, training and skills to prepare for the advocacy of health policy efforts of AAHKS. As at the UWMC, our NWH practices encompass difficult cases that often belie the community-like feel of Northwest Hospital. Rounding out adult reconstructive service at NWH are Seth Leopold, MD and Paul Manner, MD. Dr. Leopold also serves as the editor in chief of Clinical Orthopaedics and Related Research, a prestigious leading orthopaedic journal. He is assisted in this endeavor by Dr. Manner. More information about Northwest Hospital can be found in the separate site report dedicated to NWH in this publication.

Our SCCA and UWMC orthopaedic tumor service is led by Chappie Conrad and Darin Davidson. The tumor service also encompasses Seattle Childrens Hospital where Dr. Antoinette Lindberg and Dr. Conrad manage the pediatric patients. Due to continued large volumes, the service recently added a second "ACE" (fellow) to the service. Despite fierce national competition for orthopaedic tumor fellows, the service has been able to fill both of their fellowship positions with highly qualified candidates.

Dr. Winston Warme is Chief of the Shoulder and Elbow Service which is rounded out by the founder of the service, Dr. Rick Matsen, and Dr. Jason Hsu, one of our more recent recruits. Dr. Matsen has taken on a new challenge in developing a research program to study the biology of periprosthetic infections in the shoulder. Dr. Hsu has partnered on this project with Dr. Matsen and recently received extramural research funding to help move this important study forward. In April 2016, Dr. Hsu participated in the U.S. Bone and Joint Initiative, Young Investigators Initiative (YII) Grant Mentoring and Career Development program. This career development and grant mentoring program is open



University of Washington Medical Center

to promising junior faculty, senior fellows or post-doctoral researchers nominated by their department or division chairs. Dr. Warme leads a very successful program to teach our residents arthroscopy skills. This program has become a favorite of our residents and is no doubt a major appeal to medical students choosing our residency over other programs across the country.

Our sports service is anchored by Drs. Green, Gee and Kweon. Dr. Green and his wife Catherine will be moving to San Antonio this fall where Trey will become a member of the Department of Orthopaedic Surgery at UT San Antonio. His colleagues and I are very sorry to see him leave our program but we wish him and Catherine the best on their new adventure. Through hard work and skillful care, Albert Gee has established himself as the main surgeon caring for the Husky athletes. Dr. Gee has also seen his research program grow and has received extramural funding for his work on tissue engineering to treat traumatic soft tissue injuries. Albert has been joined by Dr. Chris Kweon. Chris grew up in Seattle and worked in our previous sports medicine clinic prior to becoming a physician. Chris spent the past 18 months in private practice and brings new energy and a focus on efficient high-quality care. He has also renewed old friendships and helped build bridges between the different departments involved in caring for the athletes as well as with the athletic trainers. I looking forward to seeing Dr. Kweon's academic and clinical programs develop over the next several years.

I would be remiss in not mentioning that we are all supported in important ways by our advanced practice providers. Janice Olivo, PA and Katie Moore, ARNP have been incredible additions to our team and help with the care of our orthopaedic inpatients at UWMC and NWH, respectively.

Finally, I would like to acknowledge Dr. Ted Wagner. Dr. Wagner retired from his surgical spine practice but continues to see outpatients with complex spine problems. Ted also leads several trips abroad each year to volunteer his services as a physician to the underserved in some very challenging parts of the planet. This has also given many of our residents a chance to experience the challenges faced by

patients and health care systems in third-world countries. Dr. Wagner has been recognized for his efforts with an appointment in the UW Department of Global Health, our only faculty member with such a title.

Howard A. Chansky, MD
Professor and Chair

Northwest Hospital Orthopaedics

Northwest Hospital and Medical Center has been a site of great growth and development during the past year. The campus continues to transition from its role as a community hospital to an academic hub and tertiary referral center for adult reconstruction and hand/elbow related orthopaedics. This transformation is occurring in the arenas of patient care, research, and education.

Notable advancements in clinical practice include completion of a comprehensive care pathway for primary hip and knee replacements. This has streamlined care delivery and allowed for synchronization of clinical efforts between multiple high volume providers. We have also developed a new preoperative patient education curriculum, thereby managing patient expectations, improving patient satisfaction, and decreasing inpatient length of stay. The addition of Katie Moore, ARNP, to the Adult Reconstruction service has been instrumental in implementing these tools and improving patient safety. Paralleling these developments, the hand/elbow service has added Laura DesEnfants, PA-C, who had made contributions to the flow of patient care. The distal radius fracture clinical care pathway continues to evolve with hopes of completion in the near future. Finally collaboration with the UW infectious disease service, to create an orthopaedic infectious disease presence on campus (Dr. Santiago Neme and Dr. William Ehni) has been a huge boon in dealing with challenging cases.

With respect to advancements in research and academic endeavors, Northwest Hospital is now contributing to the American Joint Replacement Registry (AJRR), and, as a contributor will be able to utilize this database for comparative studies. Furthermore, multiple prospective studies are underway. Currently, we are investigating patient expectations for hip and knee arthroplasty within the context of validated orthopaedic outcomes measures. Additional collaboration is underway to determine the effects of hip arthroplasty and carpal tunnel release on sleep.



Resident and fellow education continues at Northwest Hospital and has been effectual in providing an ample surgical volume in the areas of elective hand, wrist, and elbow surgery including arthroscopy and arthroplasty. Moreover, the volume of primary and complex revision hip and knee arthroplasty has grown substantially during the past year. Finally, a steady volume of general and geriatric trauma continues to be a “fan favorite” for residents on service. In addition to clinical education, didactic efforts have also been increased in the form of department-supported, arthroplasty seminars featuring rotating topics which have included: upper and lower extremity arthroplasty in the setting of trauma, bearing surface controversies, partial knee replacement, and periprosthetic fractures.

Current goals for the upcoming year include developing a hip and distal radius fracture registry to augment the foundation of the “Strong Bones” program, which has been developed by Robert Clawson. This tool will allow us to improve patient outcomes and track them for prospective research. Additionally, developing methods to collect patient reported outcomes electronically for integration into the medical record will be a priority for innovation on campus.

Stephen Kennedy, MD
Adam Sassoon, MD

VA Puget Sound Orthopaedics

The VA Puget Sound remains a busy orthopaedic center and stands as a cornerstone of our residency training program. Drawing from the large catchment area of the Pacific Northwest, it continues to be a high-volume tertiary care center where we provide first-class care of a vast array of musculoskeletal conditions from simple to complex.

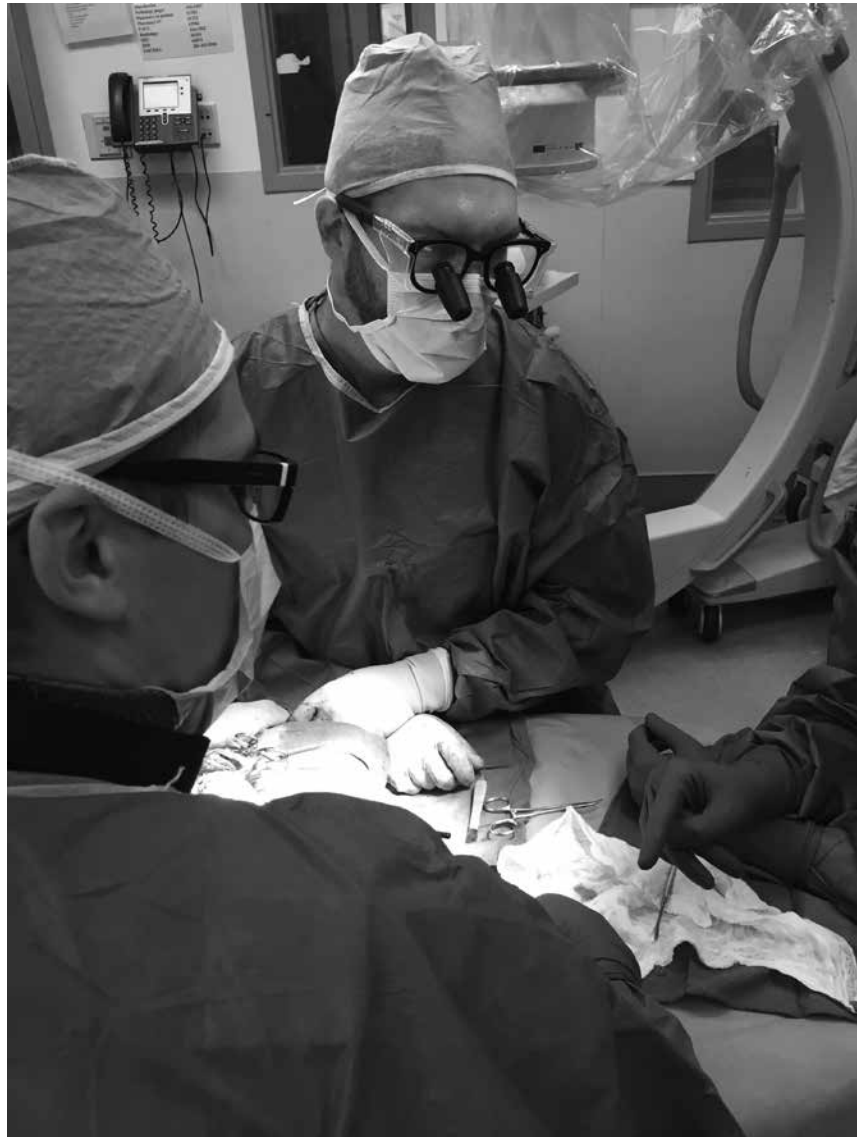Our newest addition to the orthopaedic surgery team is Dr. Nicholas Iannuzzi. He joins us this year after completing his fellowship in hand and upper extremity surgery at the Curtis National Hand Center in Baltimore. Dr. Iannuzzi is one of our former spectacular residents and he returns as faculty to provide both general orthopaedic and sub-specialty upper extremity surgery for our Veterans. We are so excited to welcome him back and anticipate a great career for Nick in clinical care, research and teaching.

The stalwart Dr. Howard Chansky remains busy with general orthopaedics and hip and knee arthroplasty. His volume of surgeries at the VA has seen little decrease despite taking on the full-time role as leader of the UW Department of Orthopaedic Surgery. We congratulate him on his rise to the Chair and will do our best to support him so that he can focus more on caring for our Department.

Dr. Chansky reached another major milestone this past March, which represented 20 years at the Puget Sound VA. We commend him on his enduring career throughout which he has cared for thousands of Veterans, mentored and trained countless residents, and advanced the field of orthopaedic science with his research. The best part is that he's not done yet nor has he given any indication that he will be anytime soon.

In other big news...

Coming off his term as President of the American Orthopaedic Foot and Ankle Society, Dr. Bruce Sangeorzan continues to provide high level foot and ankle care to our Vets while simultaneously running the Seattle Center of Excellence in Limb Loss Prevention and Prosthetic Engineering. The Center remains an institution of impactful research in the field of



Dr. Iannuzzi hard at work in the Operating Room at the Puget Sound VA.

Limb Preservation and one of its lead researchers, Dr. William Ledoux, was recently awarded the 2016 Jack Michaels Award for Research Excellence by the Northwest Paralyzed Veterans of America.

In other research news, Dr. Liu Yang has bid farewell to the Puget Sound VA and has moved his lab to the University of Washington Medical Center where he continues to explore the molecular mechanisms of orthopaedic diseases. He spent 17 years at the VA, during which time he held multiple VA and NIH awards and had numerous publications in conjunction with our clinical faculty. We are sad to see him go, but comforted

by the fact that he has not gone far. I'm especially grateful for this, as his close proximity will allow me to continue my research collaboration with him.

In other parting news, we said good-bye to Dr. Jerry Huang, who has relinquished his monthly hand and upper extremity practice at the VA, and dedicated himself to his UW practice which keeps him extremely busy.

We said good-bye to Leo Cruz and Amy Arce, two of our most dedicated, talented and well-liked surgical technicians. Leo moved to Denver and continues to work in the OR at the Denver VA. Amy also continues her work at Valley Hospital which is closer

to her home town of Puyallup.

Later this year, Anne Dinsmore, our orthopaedic nurse coordinator will be leaving our OR team as well. Anne has been our service's anchor in the OR and has worked with us for over 20 years. Her role in keeping the OR running smoothly for orthopaedic surgery cases was of immeasurable importance and we will miss her tremendously. Our sadness is lessened slightly by the fact that she will continue to work at our VA and so we will still see her from time to time. She has decided to take a promotion as nursing manager for the inpatient medical and surgical services. Anne is one of the unsung heroes of our VA and we feel fortunate to have worked with somebody who is so selfless, kind and talented.

Joel Perez, RN, Robert "Clay" Ramsey, RN and Randy Dupuy, RN who are three of our orthopaedic OR nurses will step up and take on the role left behind by Anne. They have very big shoes to fill, but we know them to be hard-working and fast-learners so I am confident they will be up to the task.

Drs. Fred Huang and Jason Hsu continue to provide orthopaedic care to our Veterans on a per-diem basis and remain engaged with our residency despite their part-time status at the VA.

I continue my role as Chief of the Orthopaedic Surgery division and enjoy my clinical work at the VA, providing knee and shoulder specialty surgical care and working with our resident trainees.

The level of dedication and care provided to our Veterans by our physician extenders and our clinical support staff never ceases to amaze me. Dustin Higbee, PA-C, Steve Casowitz, PA-C, Amy Katzenmeyer, and Renato Rafi, PA-C and Annette Testa, LPN continue to be the cornerstone of our patient care team. They remain a vital part of outpatient care and assist tremendously in the operating rooms, seamlessly synergistic with the care provided by our rotating resident teams.

The unpredictable nature of our surgical schedule at the VA can be a formidable challenge to manage. Despite this, our service is never at a loss, because of our two fabulous surgical coordinators, Monette Manio, RN and Katherine German, RN who can handle any situation, however complex or arising at the last-minute. Our day-to-day lives at the VA would not



be possible without the administrative help of Cindy Lostoski and Lyra Bryant. They are great to work with and have shown true dedication to our team and to the care of our Vets.

We've had some big changes this year, but the Puget Sound VA Medical Center continues to serve as a bastion of orthopaedic surgical care for Veterans of the Northwest region of the United States. We continue our record of excellence in clinical care, research and teaching. I am happy to report that the State of our Union at the VA remains strong and we are honored to continue our vital mission of improving the health of those who have served.

Albert O. Gee, MD
Chief
Division of Orthopaedic Surgery
VA Puget Sound Health Care
System

Graduating Residents



Todd Blumberg, MD

Following residency, Todd will complete a fellowship in pediatric orthopaedics at Children's Hospital of Philadelphia (CHOP). He plans to join an academic practice either on the coasts or back home in Texas.



Sean Haloman, MD

After residency, Sean will move with his family to Los Angeles to complete a sports medicine fellowship at the Southern California Orthopaedic Institute (SCOI). Upon completion, he and his wife, Elsa, plan to stay and practice in Southern California.



Akash Gupta, MD

After residency, Akash will be completing a fellowship in Foot and Ankle at the Hospital for Special Surgery in New York, while his wife, Kelsey, finishes her Pediatric Nephrology fellowship at Seattle Children's Hospital. After fellowship, they plan to settle in the Pacific Northwest.



Emily Harnden, MD

After residency, Emily and her husband, Graham, will move to Taos, New Mexico, where she will complete a fellowship in Sports Medicine at the Taos Orthopedic Institute. Upon completion, Emily plans to practice General Orthopaedics and Sports Medicine somewhere in the Mountain West.

Graduating Residents



Clifford Hou, MD

After residency, Cliff and his wife, Jenny, will move to the Bay Area where he will complete a fellowship in sports medicine at the SOAR Medical Associates. Upon completion of fellowship, Cliff and Jenny hope to settle down on the West Coast.



Jessica Telleria, MD

Following residency, Jess and her boyfriend, Carlton, are moving to Boston where she will complete a Foot & Ankle fellowship at the Brigham and Women's Hospital. Thereafter they will return home to the greater northwest to establish their respective careers and enjoy the outdoors.



Dayne Mickelson, MD

Following residency, Dayne and his family (wife Kelly, along with sons Bryce, 3, and Ayden, 1) will be moving to North Carolina where he will complete a fellowship in Sports Medicine at Duke University. Upon completion of fellowship, they are planning to return to the Pacific Northwest.

Incoming Residents



Prashoban Bremjit, MD

From Yakima, Washington, Dr. Bremjit attended Duke University and medical school here at the University of Washington. In orthopaedics, he is interested in pediatrics as well as spine. Away from work, he enjoys watching the Seahawks, Duke Basketball, trying new restaurants, playing golf, drinking craft beer, and spending quality time with friends.



Matthew Folchert, MD

Matthew Folchert is from Sioux City, Iowa. He attended Creighton University. For medical school, he attended the University of Iowa College of Medicine. His areas of interest in orthopaedics are joints, hand & upper extremity. His interests away from work include rugby, skiing, hiking, camping, travel, food and craft beer, and lifting and running.



Thomas Byrnes, MD

From Mukilteo, Washington, Thomas graduated with his undergraduate degree from the University of Pennsylvania and medical school at Tufts University School of Medicine. Outside of work, he enjoys backpacking/camping in the Pacific Northwest, traveling, and spending time with friends and family.



Boris Kovalenko, MD

Boris joins us from Kennesaw, Georgia. He went to Georgia Tech for his undergraduate degree and the Medical College of Georgia for medical school. In orthopaedics, he is interested in pediatrics, hand, and total joint. When not at work, he enjoys playing the guitar, lifting, and breweries.

Incoming Residents



Eli Sayegh, MD

Dr. Sayegh joins us from Los Angeles, California. Pepperdine University and Columbia University College of Physicians and Surgeons are where he attended college and medical school. His areas of interest in orthopaedics are translational and clinical research. His hobbies include running, sports, piano, concerts, cooking, writing, traveling, and exploring Seattle.



Cody Tipton, MD

From Bothell, Washington, Dr. Tipton attended Missouri Western State University and, for medical school, Howard University College of Medicine. Sports Medicine and Upper Extremity are his main areas of interest. Outside of work, he enjoys baseball, golf, and most of all spending time outdoors with "my beautiful wife Ashley, newborn son Cohen, and golden doodle Emmitt."



Brett Schiffman, MD

Brett Schiffman is from Oak Park, Illinois. He attended Washington University in St. Louis and Loyola University Chicago School of Medicine. For orthopaedics he is considering specializing in Hand/Upper Extremity or Trauma. Away from work, he spends his time barbecuing, watching Chicago sports teams, hiking, and traveling.



Anthony Yi, MD

Anthony is from Tacoma, Washington. He received his undergraduate education from the University of Southern California and also attended the Keck School of Medicine. His orthopaedic areas of interest are trauma, shoulder & elbow, as well as sports medicine. Outside of work he enjoys tennis, basketball, hiking, and scuba diving.

ACEs and Fellows



Timothy Alton, MD
Trauma



Justin Haller, MD
Trauma



Cameron Pathanacharoenphon, MD
Foot & Ankle



Matthew Garner, MD
Trauma



Brandon King, MD
Foot & Ankle



Joseph Pirolo, MD
Hand



Michael Githens, MD
Trauma



Mary Claire Manske, MD
Hand



Jason Pittman, MD, PhD
Spine



David Glassman, MD
Spine



Garrett Pangrazzi, MD
Foot & Ankle



Michael Pouliot, MD
Hand

ACEs and Fellows



Rodolfo Zamora Rendich, MD
Oncology



Kevin Vogeli, MD
Hand



Ben Service, MD
Shoulder & Elbow



Amy Williams, MD
Oncology



Jeremy Somerson, MD
Shoulder & Elbow



Haitao Zhou, MD
Spine



Matthew Sullivan, MD
Trauma

Research Grants

National Institutes of Health

Collagen Cross-Linking in Skeletal Aging and Diseases
David R. Eyre, PhD
Jiann-Jiu Wu, PhD

Collagen Diversity and Pathobiology in Skeletal Tissues
David R. Eyre, PhD
Jiann-Jiu Wu, PhD

Comparing Ankle Arthrodesis to Ankle Arthroplasty
Bruce J. Sangeorzan, MD

Muscle Atrophy and Bone Anabolism
Ted S. Gross, PhD
Steven D. Bain, PhD
Ronald Y. Kwon, PhD
Edith M. Gardiner, PhD

Neuronal Modulation of Focal Bone Homeostasis
Ted S. Gross, PhD
Steven D. Bain, PhD
Edith M. Gardiner, PhD
Ronald Y. Kwon, PhD

Neuroskeletal Systems Biology in Zebrafish
Ronald Y. Kwon, PhD

Suppression of Bone Mechanotransduction by the Beta 2 Adrenergic Receptor
Edith M. Gardiner, PhD
Sundar Srinivasan, PhD
Steven D. Bain, PhD
Leah E. Worton, PhD
Ronald Y. Kwon, PhD

Veterans Affairs Rehabilitation Research and Development Service

Dynamic Foot Bone Motion: Evaluation of Reconstructive Procedures
Bruce J. Sangeorzan, MD

EWS-Fli1 Fusion Protein and Ewing's Sarcoma
Howard A. Chansky, MD

VA Center of Excellence in Amputation Prevention and Prosthetic Engineering
Bruce J. Sangeorzan, MD

AO Foundation

Quality of Fracture Reduction and Its Influence on Functional Outcome in Patients With Pilon Fractures
Sean E. Nork, MD

AO North America

AO North America Orthopaedic Trauma Fellowship
David P. Barei, MD

AO Spine North America Fellowship
Richard Bransford, MD

Acumed

Acumed Educational Grant 2014
Jerry I. Huang, MD

Arthrex, Inc.

Arthrex Education Grant
Jerry I. Huang, MD

Arthrex Fellowship Education Grant
Winston J. Warme, MD

Baylor College of Medicine

Pathogenesis of Novel Forms of Osteogenesis Imperfecta
David R. Eyre, PhD

Boston Medical Center

Intramedullary Nails versus Plate Fixation Re-Evaluation Study in Proximal Tibia Fractures: A Multi-Center Randomized Trial Comparing Nails and Plate Fixation
Robert P. Dunbar, MD

Glasgow Caledonian University

Design of Novel Insoles for Foot Ulceration in Persons with Diabetes
Peter R. Cavanagh, PhD, DSc

D-FOOTPRINT— Personalised Insoles via Additive Manufacture for the Prevention of Plantar Ulceration in Diabetes
Peter R. Cavanagh, PhD, DSc

Johns Hopkins University

A Prospective Randomized Trial to Assess PO versus IV Antibiotics for the Treatment of Early Post-Op Wound Infection after Extremity Fractures
Reza Firoozabadi, MD

Streamlining Trauma Research Evaluation with Advanced Measurement: STREAM Study
Conor P. Kleweno, MD

The Major Extremity Trauma Research Consortium
Reza Firoozabadi, MD

Research Grants

JointMetrix Medical, LLC

Remote Monitoring During Rehabilitation
Peter R. Cavanagh, PhD, DSc

OMeGA Medical Grants Association, LLC

Implementing the Fundamentals of Arthroscopic Surgery
Training Program at the University of Washington
Douglas P. Hanel, MD

OMeGA Shoulder and Elbow Fellowship
Program Grant
Winston J. Warme, MD

OMeGA Spine Fellowship
Richard Bransford, MD

OMeGA Trauma Fellowship
David P. Barei, MD

Orthopaedic Research and Education Foundation

Nano-engineered Hybrid Scaffolds for Cartilage
Tissue Regeneration
Albert O. Gee, MD
Paul A. Manner, MD

Orthopaedic Trauma Association

A Multi-Center Prospective Cohort Study of Sacral
Fractures Using Patient Based and Objective
Outcomes
Carlo Bellabarba, MD

COTA Trauma Fellowship
David P. Barei, MD

Fluoroscopic Assessment of Rotation in Tibial Shaft
Fractures
David P. Barei, MD

Synthes USA

PRODISC-C Versus Anterior Cervical Discectomy
and Fusion (ACDF)
Richard Bransford, MD

Spine End-Results Research Fund
Howard A. Chansky, MD

Synthes Request for Basic AO Course R2s
Douglas P. Hanel, MD

The Boeing Company

Randomized Clinical Trial of Open versus Endoscopic
Carpal Tunnel Release and Hand Therapy Comparing
Patient Satisfaction, Functional Outcome and
Cost Effectiveness
Jerry I. Huang, MD

US Army Research Office

Patient Enrollment
Reza Firoozabadi, MD

UW Department of Bioengineering

Allan Coulter REHEAL Glove
Christopher H. Allan, MD

Coulter Cavanagh 2015
Peter R. Cavanagh, PhD, DSc
Paul A. Manner, MD

US Department of Defense

Engineered Osteoclasts for the Treatment and
Prevention of Heterotopic Ossification
Bruce J. Sangeorzan, MD
Steven D. Bain, PhD

Department Publications 2015-2016

A list of publications authored by our faculty from January 2015 through April 2016. Our faculty members names are in **bold type**.

1. Agnew SP, Ljungquist KL, **Huang JI**. Danger zones for flexor tendons in volar plating of distal radius fractures. *J Hand Surg Am*. 2015 Jun;40(6):1102-5.
2. Ahsan ZS, **Hsu JE**, **Gee AO**. The Snyder Classification of Superior Labrum Anterior and Posterior (SLAP) Lesions. *Clin Orthop Relat Res*. 2016 Apr 13.
3. Alton T, Patton DJ, **Gee AO**. Classifications in Brief: The Hawkins Classification for Talus Fractures. *Clin Orthop Relat Res*. 2015 Sep;473(9):3046-9.
4. Alton TB, Harnden E, Hagen J, **Firoozabadi R**. Single Provider Reduction and Splinting of Displaced Ankle Fractures: A Modification of Quigley's Classic Technique. *J Orthop Trauma*. 2015 Apr;29(4):e166-71.
5. Alton TB, Patel AR, **Bransford RJ**, **Bellabarba C**, Lee MJ, Chapman JR. Is there a difference in neurologic outcome in medical versus early operative management of cervical epidural abscesses? *Spine J*. 2015 Jan 1;15(1):10-7.
6. Alton TB, Werner SE, **Gee AO**. Classifications in brief: the Gartland classification of supracondylar humerus fractures. *Clin Orthop Relat Res*. 2015 Feb;473(2):738-41.
7. Ausk BJ, **Gross TS**, **Bain SD**. Botulinum Toxin-induced Muscle Paralysis Inhibits Heterotopic Bone Formation. *Clin Orthop Relat Res*. 2015 Sep;473(9):2825-30.
8. Avin KG, Bloomfield SA, **Gross TS**, Warden SJ. Biomechanical aspects of the muscle-bone interaction. *Current osteoporosis reports*. 2015 Feb;13(1):1-8.
9. Barr JS, White JK, Punt SE, **Conrad EU, 3rd**, Ching RP. Effect of simulated early weight bearing on micromotion and pullout strength of uncemented distal femoral stems. *Orthopedics*. 2015 May;38(5):e417-22.
10. Bauer K, **Mosca VS**, Zions LE. What's New in Pediatric Flatfoot? *J Pediatr Orthop*. 2015 Aug 20.
11. Beadling L, **Leopold SS**. Editorial: Why some authors make bad choices—Peer review for hire and other sad stories. *Clin Orthop Relat Res*. 2015;473:2441-3.
12. Beadling L, **Leopold SS**. A New Way to Read, Write, and Review for CORR®. *Clinical Orthopaedics and Related Research®*. 2016:1-2.
13. **Benirschke SK**, Kramer PA. Joint-Preserving Osteotomies for Malaligned Intraarticular Calcaneal Fractures. *Foot and ankle clinics*. 2016 Mar;21(1):111-22.
14. Blair JA, Stoops TK, Doarn MC, Kemper D, Erdogan M, Griffing R, **Sagi HC**. Infection and Non-union Following Fasciotomy for Compartment Syndrome Associated with Tibia Fractures: A Matched Cohort Comparison. *J Orthop Trauma*. 2016 Mar 5.
15. Blumberg T, Bompadre V, **Steinman S**. Operative management of pediatric floating elbow: is forearm fixation necessary? . *J Pediatr Orthop*. 2016 Accepted for publication in April 2016.
16. Bogdan Y, Tornetta P, 3rd, Jones C, Gilde AK, Schemitsch E, Vicente M, Horwitz D, Sanders D, **Firoozabadi R**, Leighton R, de Dios Robinson J, Marcantonio A, Hamilton B. Neurologic Injury in Operatively Treated Acetabular Fractures. *J Orthop Trauma*. 2015 Oct;29(10):475-8.
17. **Bransford RJ**. Commentary on: "Fatal Isolated Cervical Spine Injury in a Patient with Ankylosing Spondylitis: A Case Report". *Global Spine J*. 2015 Jun;5(3):257-8.
18. Bus SA, Armstrong DG, van Deursen RW, Lewis JE, Caravaggi CF, **Cavanagh PR**, International Working Group on the Diabetic F. IWGDF guidance on footwear and offloading interventions to prevent and heal foot ulcers in patients with diabetes. *Diabetes/metabolism research and reviews*. 2016 Jan;32 Suppl 1:25-36.
19. Bus SA, van Deursen RW, Armstrong DG, Lewis JE, Caravaggi CF, **Cavanagh PR**, International Working Group on the Diabetic F. Footwear and offloading interventions to prevent and heal foot ulcers and reduce plantar pressure in patients with diabetes: a systematic review. *Diabetes/metabolism research and reviews*. 2016 Jan;32 Suppl 1:99-118.
20. Carter GT, Weiss MD, Friedman AS, **Allan CH**, Robinson L. Diagnosis and Treatment of Work-Related Ulnar Neuropathy at the Elbow. *Phys Med Rehabil Clin N Am*. 2015 Aug;26(3):513-22.
21. Coulter JM, **Warne WJ**. Complete Spinal Accessory Nerve Palsy From Carrying Climbing Gear. *Wilderness & environmental medicine*. 2015 Sep;26(3):384-6.
22. Dahl JW, **Huang JI**. Chronic Scapholunate Ligament Injuries: Treatment with Supplemental Fixation. *Hand clinics*. 2015 Aug;31(3):457-65.
23. Dietz MJ, Springer BD, Barnes PD, Falciglia MM, Friedrich AD, Berendt AR, Calhoun JH, **Manner PA**. Best practices for centers of excellence in addressing periprosthetic joint infection. *J Am Acad Orthop Surg*. 2015 Apr;23 Suppl:S12-7.
24. Dobbs MB, Gebhardt MC, Gioe TJ, **Leopold SS**, **Manner PA**. Editorial: Estimating survivorship in the face of competing risks. *Clin Orthop Relat Res*. 2015;473:1173-6.

25. Duran I, Nevarez L, Sarukhanov A, Wu S, Lee K, Krejci P, Weis M, **Eyre D**, Krakow D, Cohn DH. HSP47 and FKBP65 cooperate in the synthesis of type I procollagen. *Hum Mol Genet.* 2015 Apr 1;24(7):1918-28.
26. Eastman JG, **Firoozabadi R**, Cook LE, Barei DP. Incarcerated Cortical Fragments in Intramedullary Nailing. *Orthopedics.* 2016 Apr 18:1-5.
27. Favinger JL, Ha AS, **Brage ME**, Chew FS. Osteoarticular transplantation: recognizing expected postsurgical appearances and complications. *Radiographics : a review publication of the Radiological Society of North America, Inc.* 2015 May-Jun;35(3):780-92.
28. Favinger JL, Porrino JA, Richardson ML, Mulcahy H, Chew FS, **Brage ME**. Epidemiology and imaging appearance of the normal Bi-/multipartite hallux sesamoid bone. *Foot Ankle Int.* 2015 Feb;36(2):197-202.
29. **Firoozabadi R**, Alton T, Wenke J. Advances in Diagnosing Orthopaedic Trauma Infections. *Journal of the American Academy of Orthopaedic Surgeons* 2015(6).
30. **Firoozabadi R**, Alton T, Wenke J. Novel Strategies for the Diagnosis of Posttraumatic Infections in Orthopaedic Trauma Patients. *J Am Acad Orthop Surg.* 2015 Jul;23(7):443-51.
31. **Firoozabadi R**, Gregg RE, Babaeizadeh S. Identification of exercise-induced ischemia using QRS slopes. *Journal of electrocardiology.* 2016 Jan-Feb;49(1):55-9.
32. **Firoozabadi R**, Harnden E, Krieg JC. Immediate weight-bearing after ankle fracture fixation. *Advances in orthopedics.* 2015;2015:491976.
33. **Firoozabadi R**, Oldenburg F, Krieg J, Routt C. Prevention of Iliosacral Intrusion. *Techniques of Orthopaedics.* 2015;30:56-9.
34. **Firoozabadi R**, Schneidkraut J, **Beingessner D**, **Dunbar R**, **Barei D**. Hyperextension Varus Bicondylar Tibial Plateau Fracture Pattern: Diagnosis and Treatment Strategies. *J Orthop Trauma.* 2016 May;30(5):e152-7.
35. **Firoozabadi R**, Spittler C, Schlepp C, Hamilton B, Agel J, Routt MC, Tornetta P. Determining Stability in Posterior Wall Acetabular Fractures. *J Orthop Trauma.* 2015 Oct;29(10):465-9.
36. **Firoozabadi R**, Stafford P, Routt M. Inguinal Abnormalities in Male Patients with Acetabular Fractures Treated Using an Ilioinguinal Exposure. *The archives of bone and joint surgery.* 2015 Oct;3(4):274-9.
37. **Firoozabadi R**, Stafford P, Routt M. Risk of Spermatic Cord Injury During Anterior Pelvic Ring and Acetabular Surgery: An Anatomical Study. *The archives of bone and joint surgery.* 2015 Oct;3(4):269-73.
38. **Firoozabadi R**, Swenson A, **Kleweno C**, Routt MC. Cell Saver Use in Acetabular Surgery: Does Approach Matter? *J Orthop Trauma.* 2015 Aug;29(8):349-53.
39. Gage MJ, Yoon RS, Gaines RJ, **Dunbar RP**, Egol KA, Liporace FA. Dead Space Management After Orthopaedic Trauma: Tips, Tricks, and Pitfalls. *J Orthop Trauma.* 2016 Feb;30(2):64-70.
40. Gilmer BB, Guerrero DM, Coleman NW, Chamberlain AM, **Warne WJ**. Orthopaedic Residents Improve Confidence and Knot-Tying Speed With a Skills Course. *Arthroscopy : the journal of arthroscopic & related surgery : official publication of the Arthroscopy Association of North America and the International Arthroscopy Association.* 2015 Jul;31(7):1343-8 e2.
41. Githens M, Alton TB, **Firoozabadi R**, Bishop JA. Intraoperative Distal Femoral Fine Wire Traction to Facilitate Intramedullary Nailing of the Femur. *Orthopedics.* 2016 Mar 1;39(2):e380-5.
42. **Goldberg MJ**. POSNA PreCourse Quality, Safety, Value: From Theory to Practice Management Session 3 AAOS and ABOS Initiatives: "Historical Perspective". *J Pediatr Orthop.* 2015 Jul-Aug;35(5 Suppl 1):S41-2.
43. **Goldberg MJ**. POSNA PreCourse Quality, Safety, Value: From Theory to Practice Management Session 4 Deliverables Supracondylar Clinical Pathway. *J Pediatr Orthop.* 2015 Jul-Aug;35(5 Suppl 1):S39-40.
44. Gorbaty JD, Lucas RM, **Matsen FA, 3rd**. Detritic synovitis can mimic a Propionibacterium periprosthetic infection. *Int Orthop.* 2016 Jan;40(1):95-8.
45. Grauer JN, **Leopold SS**. Editorial: Large Database Studies—What They Can Do, What They Cannot Do, and Which Ones We Will Publish. *Clin Orthop Relat Res.* 2015;473(5):1537-9.
46. Gundle KR, Cizik AM, Jones RL, **Davidson DJ**. Quality of life measures in soft tissue sarcoma. *Expert Rev Anticancer Ther.* 2015 Jan;15(1):95-100.
47. Gundle KR, Mickelson DT, **Hanel DP**. Reflections in a time of transition: orthopaedic faculty and resident understanding of accreditation schemes and opinions on surgical skills feedback. *Medical education online.* 2016;21:30584.
48. Hackett DJ, Rothenberg AC, Chen AF, Gutowski C, Jaekel D, Tomek IM, Parsley BS, Ducheyne P, **Manner PA**. The economic significance of orthopaedic infections. *J Am Acad Orthop Surg.* 2015 Apr;23 Suppl:S1-7.
49. Haller JM, O'Toole R, Graves M, Barei D, Gardner M, Kubiak E, Nascone J, **Nork S**, Presson AP, Higgins TF. How much articular displacement can be detected using fluoroscopy for tibial plateau fractures? *Injury.* 2015 Nov;46(11):2243-7.
50. **Hansen ST**, **Brage ME**, Johnson MD. Revision Joint-Sparing Surgical Procedures for the Management of Hallux Valgus. In: Alexander IJ BE, Greisberg JK, editor. *Advanced Reconstruction Foot and Ankle 2: American Academy of Orthopaedic Surgeons*; 2015.
51. Haynes JA, Stambough JB, **Sassoon AA**, Johnson SR, Clohisy JC, Nunley RM. Contemporary Surgical Indications and Referral Trends in Revision Total Hip Arthroplasty: A 10-Year Review. *J Arthroplasty.* 2016 Mar;31(3):622-5.
52. Herchenhan A, Uhlenbrock F, Eliasson P, Weis M, **Eyre D**, Kadler KE, Magnusson SP, Kjaer M. Lysyl Oxidase Activity Is Required for Ordered Collagen Fibrillogenesis by Tendon Cells. *J Biol Chem.* 2015 Jun 26;290(26):16440-50.

53. Homayouni T, Underwood KN, Beyer KC, Martin ER, **Allan CH**, Balasubramanian R. Modeling Implantable Passive Mechanisms for Modifying the Transmission of Forces and Movements Between Muscle and Tendons. *IEEE transactions on bio-medical engineering*. 2015 Sep;62(9):2208-14.
54. Horneff JG, 3rd, **Hsu JE**, Voleti PB, O'Donnell J, Huffman GR. Propionibacterium acnes infection in shoulder arthroscopy patients with postoperative pain. *Journal of shoulder and elbow surgery / American Shoulder and Elbow Surgeons [et al]*. 2015 Jun;24(6):838-43.
55. Hosseininia S, Weis MA, Rai J, Kim L, Funk S, Dahlberg LE, **Eyre DR**. Evidence for enhanced collagen type III deposition focally in the territorial matrix of osteoarthritic hip articular cartilage. *Osteoarthritis Cartilage*. 2016 Jan 11.
56. Hou C, Gupta A, Chen M, **Matsen FA, 3rd**. How do revised shoulders that are culture positive for Propionibacterium differ from those that are not? *Journal of shoulder and elbow surgery / American Shoulder and Elbow Surgeons [et al]*. 2015 Sep;24(9):1427-32.
57. **Hsu J**, Keener JD. Natural History of Rotator Cuff Disease and Implications on Management. *Operative techniques in orthopaedics*. 2015 Mar 1;25(1):2-9.
58. **Hsu JE**, Bumgarner RE, **Matsen FA, 3rd**. Propionibacterium in Shoulder Arthroplasty: What We Think We Know Today. *J Bone Joint Surg Am*. 2016 Apr 6;98(7):597-606.
59. **Hsu JE**, **Gee AO**, Lucas RM, Somerson JS, **Warne WJ**, **Matsen FA, 3rd**. Management of intraoperative posterior decentring in shoulder arthroplasty using anteriorly eccentric humeral head components. *Journal of shoulder and elbow surgery / American Shoulder and Elbow Surgeons [et al]*. 2016 Apr 7.
60. **Hsu JE**, Horneff JG, **Gee AO**. Immobilization After Rotator Cuff Repair: What Evidence Do We Have Now? *Orthop Clin North Am*. 2016 Jan;47(1):169-77.
61. **Hudson DM**, Joeng KS, Werther R, Rajagopal A, Weis M, Lee BH, **Eyre DR**. Post-translationally abnormal collagens of prolyl 3-hydroxylase-2 null mice offer a pathobiological mechanism for the high myopia linked to human LEPREL1 mutations. *J Biol Chem*. 2015 Mar 27;290(13):8613-22.
62. Hug KT, Alton TB, **Gee AO**. Classifications in brief: Brooker classification of heterotopic ossification after total hip arthroplasty. *Clin Orthop Relat Res*. 2015 Jun;473(6):2154-7.
63. Iorio ML, Kennedy CD, **Huang JI**. Limited intercarpal fusion as a salvage procedure for advanced Kienbock disease. *Hand (N Y)*. 2015 Sep;10(3):472-6.
64. Jeong Y, Carleton SM, Gentry BA, Yao X, Ferreira JA, Salamango DJ, Weis M, Oestreich AK, Williams AM, McCray MG, **Eyre DR**, Brown M, Wang Y, Phillips CL. Hindlimb Skeletal Muscle Function and Skeletal Quality and Strength in +/G610C Mice With and Without Weight-Bearing Exercise. *J Bone Miner Res*. 2015 Oct;30(10):1874-86.
65. Johnson MD, **Brage ME**, Zickuhr KR. Total Ankle Allograft Reconstruction in Patients with Ankle Arthritis. In: Alexander IJ BE, Greisberg JK, editor. *Advanced Reconstruction Foot and Ankle 2: American Academy of Orthopaedic Surgeons*; 2015.
66. Kearney SP, **Mosca VS**. Selective hemiepiphyseodesis for patellar instability with associated genu valgum. *Journal of orthopaedics*. 2015 Mar;12(1):17-22.
67. Keener JD, **Hsu JE**, Steger-May K, Teefey SA, Chamberlain AM, Yamaguchi K. Patterns of tear progression for asymptomatic degenerative rotator cuff tears. *Journal of shoulder and elbow surgery / American Shoulder and Elbow Surgeons [et al]*. 2015 Dec;24(12):1845-51.
68. Kennedy CD, **Huang JI**. Prosthetic Design in Total Wrist Arthroplasty. *Orthop Clin North Am*. 2016 Jan;47(1):207-18.
69. Kennedy CD, **Huang JI**, **Hanel DP**. In Brief: Kanavel's Signs and Pyogenic Flexor Tenosynovitis. *Clin Orthop Relat Res*. 2016 Jan;474(1):280-4.
70. **Kennedy S**, Barske H, Wing K, Penner M, Daniels T, Glazebrook M, Dryden P, Wong H, Younger A. SF-36 Mental Component Summary (MCS) Score Does Not Predict Functional Outcome After Surgery for End-Stage Ankle Arthritis. *J Bone Joint Surg Am*. 2015 Oct 21;97(20):1702-7.
71. **Kennedy SA**. CORR Insights((R)): To What Degree Do Pain-coping Strategies Affect Joint Stiffness and Functional Outcomes in Patients With Hand Fractures? *Clin Orthop Relat Res*. 2015 Nov;473(11):3491-3.
72. **Kennedy SA**. CORR Insights((R)): A Randomized Trial Among Compression Plus Nonsteroidal Antiinflammatory Drugs, Aspiration, and Aspiration With Steroid Injection for Nonseptic Olecranon Bursitis. *Clin Orthop Relat Res*. 2016 Mar;474(3):784-6.
73. **Kennedy SA**, Stoll LE, Lauder AS. Human and Other Mammalian Bite Injuries of the Hand: Evaluation and Management. *J Am Acad Orthop Surg*. 2015 Jan;23(1):47-57.
74. Kepler CK, Vaccaro AR, Fleischman AN, Traynelis VC, Patel AA, Dekutoski MB, Harrop J, Wood KB, Schroeder GD, **Bransford R**, Aarabi B, Okonkwo DO, Arnold PM, Fehlings MG, Nassr A, Shaffrey C, Yoon ST, Kwon B. Treatment of Axis Body Fractures: A Systematic Review. *J Spinal Disord Tech*. 2015 Oct 14.
75. Kepler CK, Vaccaro AR, Koerner JD, Dvorak MF, Kandziora F, Rajasekaran S, Aarabi B, Vialle LR, Fehlings MG, Schroeder GD, Reinhold M, Schnake KJ, **Bellabarba C**, Cumhur Oner F. Reliability analysis of the AOSpine thoracolumbar spine injury classification system by a worldwide group of naive spinal surgeons. *Eur Spine J*. 2016 Apr;25(4):1082-6.
76. Khoshbin A, **Bouchard M**, Wasserstein D, Leroux T, Law PW, Kreder HJ, Daniels TR, Wright JG. Reoperations after tarsal coalition resection: a population-based study. *The Journal of foot and ankle surgery : official publication of the American College of Foot and Ankle Surgeons*. 2015 May-Jun;54(3):306-10.
77. Khwaja A, Parnell SE, Ness K, Bompadre V, **White KK**. Opsismodysplasia: Phosphate Wasting Osteodystrophy Responds to Bisphosphonate Therapy. *Frontiers in pediatrics*. 2015;3:48.
78. Kim SJ, **Gee AO**, Hwang JM, Kwon JY. Determination of steroid injection sites using lidocaine test in adhesive capsulitis: A prospective randomized clinical trial. *Journal of clinical ultrasound : JCU*. 2015 Jul-Aug;43(6):353-60.

79. Kohn MD, **Sassoon AA**, **Fernando ND**. Classifications in Brief: Kellgren-Lawrence Classification of Osteoarthritis. *Clin Orthop Relat Res*. 2016 Feb 12.
80. Kollitz KM, **Huang JI**, Hsu JW, **Cavanagh PR**. A novel computational method for evaluating osteochondral autografts in distal radius reconstruction. *Hand (N Y)*. 2015 Sep;10(3):492-6.
81. **Krengel WF, 3rd**, Kim PH, Wiater B. Spontaneous Ankylosis of Occiput to C2 following Closed Traction and Halo Treatment of Atlantoaxial Rotary Fixation. *Global Spine J*. 2015 Jun;5(3):233-8.
82. Langereis EJ, den Os MM, Breen C, Jones SA, Knaven OC, Mercer J, Miller WP, Kelly PM, Kennedy J, Ketterl TG, O'Meara A, Orchard PJ, Lund TC, van Rijn RR, Sakkers RJ, **White KK**, Wijburg FA. Progression of Hip Dysplasia in Mucopolysaccharidosis Type I Hurler After Successful Hematopoietic Stem Cell Transplantation. *J Bone Joint Surg Am*. 2016 Mar 2;98(5):386-95.
83. Large TM, Agel J, Holtzman DJ, **Benirschke SK**, Krieg JC. Interobserver Variability in the Measurement of Lower Leg Compartment Pressures. *J Orthop Trauma*. 2015 Jul;29(7):316-21.
84. Lauder A, Agnew S, Bakri K, **Allan CH**, **Hanel DP**, **Huang JI**. Functional Outcomes Following Bridge Plate Fixation for Distal Radius Fractures. *J Hand Surg Am*. 2015 Aug;40(8):1554-62.
85. **Leopold S**. Editor's Spotlight/Take 5: Is single-stage revision according to a strict protocol effective in treatment of chronic knee arthroplasty infections? *Clin Orthop Relat Res*. 2015;473(1):4-7.
86. **Leopold S**. Editor's Spotlight/Take 5: Do patient race and sex change surgeon recommendations for TKA? *Clin Orthop Relat Res*. 2015;473(2):406-9.
87. **Leopold SS**. Editor's Spotlight/Take 5: Most American Academy of Orthopaedic Surgeons' online patient education material exceeds average patient reading level. *Clin Orthop Relat Res*. 2015 Apr;473(4):1177-80.
88. **Leopold SS**. Editorial: peer review and the editorial process--a look behind the curtain. *Clin Orthop Relat Res*. 2015 Jan;473(1):1-3.
89. **Leopold SS**. Editor's Spotlight/Take 5: Is Single-stage Revision According to a Strict Protocol Effective in Treatment of Chronic Knee Arthroplasty Infections? *Clin Orthop Relat Res*. 2015;473(1):4.
90. **Leopold SS**. Editor's Spotlight/Take 5: Future Patient Demand for Shoulder Arthroplasty by Younger Patients: National Projections. *Clinical Orthopaedics and Related Research®*. 2015;473(6):1856-9.
91. **Leopold SS**. Editorial: Increased manuscript submissions prompt journals to make hard choices. *Clin Orthop Relat Res*. 2015;473(3):753-5.
92. **Leopold SS**. Editorial: "Pencil and paper" research? Network meta-analysis and other study designs that do not enroll patients. *Clinical Orthopaedics and Related Research®*. 2015;473(7):2163-5.
93. **Leopold SS**. Editor's Spotlight/Take 5: Disability after deployment injury: are women and men service members different? *Clin Orthop Relat Res*. 2015;473:2444-7.
94. **Leopold SS**. Editorial: What makes young surgeons tick (or cut). *Clin Orthop Relat Res*. 2015;473:1853-5.
95. **Leopold SS**. Editorial-Going Global: CORR (®) Best-paper Awards for China and Latin America in 2015. *Clin Orthop Relat Res*. 2015;474:1-2.
96. **Leopold SS**. Editorial: Case Closed—Discontinuing Case Reports in Clinical Orthopaedics and Related Research®. *Clinical Orthopaedics and Related Research®*. 2015;10(473):3074-5.
97. **Leopold SS**. Editor's Spotlight/Take 5: Do Patient Race and Sex Change Surgeon Recommendations for TKA? *Clinical Orthopaedics and Related Research®*. 2015;473(2):406-9.
98. **Leopold SS**. Editorial: Peer Reviewers Make it All Possible at Clinical Orthopaedics and Related Research®. *Clinical Orthopaedics and Related Research®*. 2015;473(12):3693-4.
99. **Leopold SS**. Editorial: Peer Review and the Editorial Process—A Look Behind the Curtain. *Clin Orthop Relat Res*. 2015;473(1):1-3.
100. **Leopold SS**. Editor's Spotlight/Take 5: Surgeons' Attitudes Are Associated With Reoperation and Readmission Rates. *Clinical Orthopaedics and Related Research®*. 2015;473(5):1540-3.
101. **Leopold SS**. Editor's Spotlight/Take 5: Natural Polyphenols Enhance Stability of Crosslinked UHMWPE for Joint Implants. *Clin Orthop Relat Res*. 2015;473(3):756-9.
102. **Leopold SS**. Editorial: No-difference Studies Make a Big Difference. *Clinical Orthopaedics and Related Research®*. 2015;473(11):3329-31.
103. **Leopold SS**. Editor's Spotlight/Take 5: Sex-specific Analysis of Data in High-impact Orthopaedic Journals: How Are We Doing? *Clinical Orthopaedics and Related Research®*. 2015;473(12):3695-9.
104. **Leopold SS**. Editorial: ORCID is a Wonderful (But Not Required) Tool for Authors. *Clinical Orthopaedics and Related Research®*. 2016;474(5):1083-5.
105. **Leopold SS**. Editor's Spotlight/Take 5: High Rates of Interest in Sex in Patients With Hip Arthritis. *Clinical Orthopaedics and Related Research®*. 2016;474(2):289-92.
106. **Leopold SS**. Editor's Spotlight/Take 5: What are the Risk Factors for Cerebrovascular Accidents After Elective Orthopaedic Surgery? *Clinical Orthopaedics and Related Research®*. 2016:1-4.
107. **Leopold SS**. Editorial: Do-Not-Resuscitate Orders and Advance Directives—Existential Issues for Orthopaedic Patients with Life-threatening Conditions. *Clinical Orthopaedics and Related Research®*. 2016:1-4.

108. **Leopold SS.** Editorial: Getting Evidence Into Practice—or Not: The Case of Viscosupplementation. *Clinical Orthopaedics and Related Research*. 2016;474(2):285-8.
109. Lietman CD, Marom R, Munivez E, Bertin TK, Jiang MM, Chen Y, Dawson B, Weis MA, **Eyre D**, Lee B. A transgenic mouse model of OI type V supports a neomorphic mechanism of the IFITM5 mutation. *J Bone Miner Res.* 2015 Mar;30(3):489-98.
110. Lindert U, Weis MA, Rai J, Seeliger F, Hausser I, Leeb T, **Eyre D**, Rohrbach M, Giunta C. Molecular Consequences of the SERPINH1/HSP47 Mutation in the Dachshund Natural Model of Osteogenesis Imperfecta. *J Biol Chem.* 2015 Jul 17;290(29):17679-89.
111. Lindtner RA, **Bellabarba C**, **Firoozabadi R**, Kurd MF, Shafi KA, Schroeder GD, Vaccaro AR. Should Displaced Sacral Fractures be Treated by an Orthopedic Traumatologist or a Spine Surgeon? *Clinical spine surgery.* 2016 Apr 29.
112. Litrenta J, Tornetta P, 3rd, Vallier H, **Firoozabadi R**, Leighton R, Egol K, Kruppa C, Jones CB, Collinge C, Bhandari M, Schemitsch E, Sanders D, Mullis B. Dynamizations and Exchanges: Success Rates and Indications. *J Orthop Trauma.* 2015 Dec;29(12):569-73.
113. Littman AJ, Thompson ML, Arterburn DE, Bouldin E, Haselkorn JK, **Sangeorzan BJ**, Boyko EJ. Lower-limb amputation and body weight changes in men. *Journal of rehabilitation research and development.* 2015;52(2):159-70.
114. Ljungquist KL, Agnew SP, **Huang JI**. Predicting a safe screw length for volar plate fixation of distal radius fractures: lunate depth as a marker for distal radius depth. *J Hand Surg Am.* 2015 May;40(5):940-4.
115. Ljungquist KL, Martineau P, **Allan C**. Radial nerve injuries. *J Hand Surg Am.* 2015 Jan;40(1):166-72.
116. Lucas RM, **Hsu JE**, Whitney IJ, Wasserburger J, **Matsen FA, 3rd**. Loose glenoid components in revision shoulder arthroplasty: is there an association with positive cultures? *Journal of shoulder and elbow surgery / American Shoulder and Elbow Surgeons [et al].* 2016 Mar 3.
117. Manoso MW, Moore T, Agel J, **Bellabarba C**, **Bransford RJ**. Floating Lateral Mass Fractures of the Cervical Spine. *Spine (Phila Pa 1976).* 2016 Feb 26.
118. Mardula KL, Balasubramanian R, **Allan CH**. Implanted passive engineering mechanism improves hand function after tendon transfer surgery: a cadaver-based study. *Hand (N Y).* 2015 Mar;10(1):116-22.
119. **Matsen FA, 3rd**. The ream and run: not for every patient, every surgeon or every problem. *Int Orthop.* 2015 Feb;39(2):255-61.
120. **Matsen FA, 3rd**, Lauder A, Rector K, Keeling P, Cheronas AL. Measurement of active shoulder motion using the Kinect, a commercially available infrared position detection system. *Journal of shoulder and elbow surgery / American Shoulder and Elbow Surgeons [et al].* 2016 Feb;25(2):216-23.
121. **Matsen FA, 3rd**, Li N, Gao H, Yuan S, Russ SM, Sampson PD. Factors Affecting Length of Stay, Readmission, and Revision After Shoulder Arthroplasty: A Population-Based Study. *J Bone Joint Surg Am.* 2015 Aug 5;97(15):1255-63.
122. **Matsen FA, 3rd**, Russ SM, Bertelsen A, Butler-Wu S, Pottinger PS. Propionibacterium can be isolated from deep cultures obtained at primary arthroplasty despite intravenous antimicrobial prophylaxis. *Journal of shoulder and elbow surgery / American Shoulder and Elbow Surgeons [et al].* 2015 Jun;24(6):844-7.
123. **Matsen FA, 3rd**, **Warne WJ**, Jackins SE. Can the ream and run procedure improve glenohumeral relationships and function for shoulders with the arthritic triad? *Clin Orthop Relat Res.* 2015 Jun;473(6):2088-96.
124. McElvany MD, McGoldrick E, **Gee AO**, Neradilek MB, **Matsen FA, 3rd**. Rotator cuff repair: published evidence on factors associated with repair integrity and clinical outcome. *Am J Sports Med.* 2015 Feb;43(2):491-500.
125. McGoldrick E, McElvany MD, Butler-Wu S, Pottinger PS, **Matsen FA, 3rd**. Substantial cultures of Propionibacterium can be found in apparently aseptic shoulders revised three years or more after the index arthroplasty. *Journal of shoulder and elbow surgery / American Shoulder and Elbow Surgeons [et al].* 2015 Jan;24(1):31-5.
126. Montano AM, Lock-Hock N, Steiner RD, Graham BH, Szlago M, Greenstein R, Pineda M, Gonzalez-Meneses A, Coker M, Bartholomew D, Sands MS, Wang R, Giugliani R, Macaya A, Pastores G, Ketko AK, Ezgu F, Tanaka A, Arash L, Beck M, Falk RE, Bhattacharya K, Franco J, **White KK**, Mitchell GA, Cimbalistiene L, Holtz M, Sly WS. Clinical course of sly syndrome (mucopolysaccharidosis type VII). *Journal of medical genetics.* 2016 Feb 23.
127. **Mosca VS**. Subtalar coalition in pediatrics. *Foot and ankle clinics.* 2015 Jun;20(2):265-81.
128. **Mosca VS**. Calcaneal lengthening osteotomy for valgus deformity of the hindfoot. In: Skaggs DL, Kocher M, editors. *Master Techniques in Orthopaedic Surgery: Pediatrics.* 2nd ed ed. Philadelphia: Wolters Kluwer; 2016. p. 311-27.
129. Murdoch AD, Hardingham TE, **Eyre DR**, **Fernandes RJ**. The development of a mature collagen network in cartilage from human bone marrow stem cells in Transwell culture. *Matrix Biol.* 2016 Mar;50:16-26.
130. Ng VY, Jones R, Bompadre V, Louie P, Punt S, **Conrad EU, 3rd**. The effect of surgery with radiation on pelvic Ewing sarcoma survival. *Journal of surgical oncology.* 2015 Dec;112(8):861-5.
131. Parsons EM, **Gee AO**, Spiekerman C, **Cavanagh PR**. The biomechanical function of the anterolateral ligament of the knee. *Am J Sports Med.* 2015 Mar;43(3):669-74.
132. Pathy R, Scher DM, **Mosca VS**. Cavus foot reconstruction. In: Skaggs DL, Kocher M, editors. *Master Techniques in Orthopaedic Surgery: Pediatrics.* Philadelphia: Wolters Kluwer; 2016. p. 329-46.
133. Patton D, Kiewiet N, **Brage M**. Infected total ankle arthroplasty: risk factors and treatment options. *Foot Ankle Int.* 2015 Jun;36(6):626-34.
134. Peled E, Norman D, Kakiashvili D, **Henley MB**. Recurrent episodes of micturition with expulsion of symphyseal plate screws following pelvic ring fixation: case report. *BMC musculoskeletal disorders.* 2015;16:127.

135. Pet MA, Ko JH, Friedly JL, **Smith DG**. Traction Neurectomy for Treatment of Painful Residual Limb Neuroma in Lower Extremity Amputees. *J Orthop Trauma*. 2015 Sep;29(9):e321-5.
136. Probasco W, Haleem AM, Yu J, **Sangeorzan BJ**, Deland JT, Ellis SJ. Assessment of coronal plane subtalar joint alignment in peritalar subluxation via weight-bearing multiplanar imaging. *Foot Ankle Int*. 2015 Mar;36(3):302-9.
137. Pruszczynski B, Mackenzie WG, Rogers K, **White KK**. Spinal Cord Injury After Extremity Surgery in Children With Thoracic Kyphosis. *Clin Orthop Relat Res*. 2015 Oct;473(10):3315-20.
138. Quijano LM, Lynch KM, **Allan CH**, Badylak SF, Ahsan T. Looking Ahead to Engineering Epimorphic Regeneration of a Human Digit or Limb. *Tissue engineering Part B, Reviews*. 2016 Jan 29.
139. Raichle KA, Osborne TL, Jensen MP, Ehde DM, **Smith DG**, Robinson LR. Preoperative state anxiety, acute postoperative pain, and analgesic use in persons undergoing lower limb amputation. *The Clinical journal of pain*. 2015 Aug;31(8):699-706.
140. Reed EB, Hanson AM, **Cavanagh PR**. Optimising muscle parameters in musculoskeletal models using Monte Carlo simulation. *Computer methods in biomechanics and biomedical engineering*. 2015;18(6):607-17.
141. Sandstrom CK, **Kennedy SA**, Gross JA. Acute shoulder trauma: what the surgeon wants to know. *Radiographics : a review publication of the Radiological Society of North America, Inc*. 2015 Mar-Apr;35(2):475-92.
142. **Sassoon A**, Nam D, Jackups R, Johnson SR, Nunley RM, Barrack RL. Tranexamic acid: optimal blood loss management in surface replacement arthroplasty. *Bone Joint J*. 2016 Feb;98-B(2):173-8.
143. **Sassoon A**, Nam D, Nunley R, Barrack R. Systematic review of patient-specific instrumentation in total knee arthroplasty: new but not improved. *Clin Orthop Relat Res*. 2015 Jan;473(1):151-8.
144. **Sassoon AA**, Adigweme OO, Langford J, Koval KJ, Haidukewych GJ. Manipulation Under Anesthesia: A Safe and Effective Treatment for Posttraumatic Arthrofibrosis of the Knee. *J Orthop Trauma*. 2015 Dec;29(12):e464-8.
145. **Schmale GA**, Bompadre V. Aspirations of the ilium and proximal femur increase the likelihood of culturing an organism in patients with presumed septic arthritis of the hip. *Journal of children's orthopaedics*. 2015 Aug;9(4):313-8.
146. Schneider K, Oh JK, Zderic I, Stoffel K, Richards RG, Wolf S, Gueorguiev B, **Nork SE**. What is the underlying mechanism for the failure mode observed in the proximal femoral locking compression plate? A biomechanical study. *Injury*. 2015 Aug;46(8):1483-90.
147. Schroeder GD, Kepler CK, Koerner JD, Chapman JR, **Bellabarba C**, Oner FC, Reinhold M, Dvorak MF, Aarabi B, Vialle L, Fehlings MG, Rajasekaran S, Kandziora F, Schnake KJ, Vaccaro AR. Is there a regional difference in morphology interpretation of A3 and A4 fractures among different cultures? *Journal of neurosurgery Spine*. 2015 Oct 9:1-8.
148. Schroeder GD, Kepler CK, Koerner JD, Oner FC, Fehlings MG, Aarabi B, Dvorak MF, Reinhold M, Kandziora F, **Bellabarba C**, Chapman JR, Vialle LR, Vaccaro AR. A Worldwide Analysis of the Reliability and Perceived Importance of an Injury to the Posterior Ligamentous Complex in AO Type A Fractures. *Global Spine J*. 2015 Oct;5(5):378-82.
149. Schroeder GD, Vaccaro AR, Kepler CK, Koerner JD, Oner FC, Dvorak MF, Vialle LR, Aarabi B, **Bellabarba C**, Fehlings MG, Schnake KJ, Kandziora F. Establishing the Injury Severity of Thoracolumbar Trauma: Confirmation of the Hierarchical Structure of the AOSpine Thoracolumbar Spine Injury Classification System. *Spine (Phila Pa 1976)*. 2015 Apr 15;40(8):E498-503.
150. Scolaro JA, Roberts ZV, **Benirschke SK**, **Bareil DP**. Open surgical management of high energy ipsilateral fractures of the fibula and calcaneus. *Foot and ankle surgery : official journal of the European Society of Foot and Ankle Surgeons*. 2015 Sep;21(3):182-6.
151. Scolaro JA, Wilson DJ, Routt ML, **Firoozabadi R**. Use of the initial trauma CT scan to aid in diagnosis of open pelvic fractures. *Injury*. 2015 Oct;46(10):1999-2002.
152. Scully WF, **White KK**, Song KM, **Mosca VS**. Injection-induced gluteus muscle contractures: diagnosis with the "reverse Ober test" and surgical management. *J Pediatr Orthop*. 2015 Mar;35(2):192-8.
153. Shah SH, Porrino JA, **Green JR, 3rd**, Chew FS. Bilateral pigmented villonodular synovitis of the knee. *Radiology case reports*. 2015 Dec;10(4):56-60.
154. Shatsky J, **Bellabarba C**, Nguyen Q, **Bransford RJ**. A retrospective review of fixation of C1 ring fractures-does the transverse atlantal ligament (TAL) really matter? *Spine J*. 2016 Mar;16(3):372-9.
155. Somerson JS, **Hsu JE**, Gorbaty JD, **Gee AO**. Classifications in Brief: Goutallier Classification of Fatty Infiltration of the Rotator Cuff Musculature. *Clin Orthop Relat Res*. 2016 May;474(5):1328-32.
156. **Srinivasan S**, Ausk BJ, **Bain SD**, **Gardiner EM**, **Kwon RY**, **Gross TS**. Rest intervals reduce the number of loading bouts required to enhance bone formation. *Medicine and science in sports and exercise*. 2015 May;47(5):1095-103.
157. Stokke J, Sung L, Gupta A, **Lindberg A**, Rosenberg AR. Systematic review and meta-analysis of objective and subjective quality of life among pediatric, adolescent, and young adult bone tumor survivors. *Pediatric blood & cancer*. 2015 Sep;62(9):1616-29.
158. Stoll KE, Miles JD, White JK, Punt SE, **Conrad EU, 3rd**, Ching RP. Assessment of registration accuracy during computer-aided oncologic limb-salvage surgery. *International journal of computer assisted radiology and surgery*. 2015 Sep;10(9):1469-75.
159. Stoll LE, **Huang JI**. Surgical Treatment of Distal Biceps Ruptures. *Orthop Clin North Am*. 2016 Jan;47(1):189-205.
160. Swanson JO, Alessio AM, **White KK**, **Krengel WF**, Friedman SD, Vining NC, Song KM. Spine Computed Tomography Radiation Dose Reduction: Protocol Refinement Based on Measurement Variation at Simulated Lower Radiation Acquisitions. *Spine (Phila Pa 1976)*. 2015 Oct 15;40(20):1613-9.
161. Tatman PD, Gerull W, Sweeney-Easter S, Davis JI, **Gee AO**, Kim DH. Multiscale Biofabrication of Articular Cartilage: Bioinspired and Biomimetic Approaches. *Tissue engineering Part B, Reviews*. 2015 Dec;21(6):543-59.

162. Tatman PD, Muhonen EG, Wickers ST, **Gee AO**, Kim ES, Kim DH. Correction: Self-assembling peptides for stem cell and tissue engineering. *Biomaterials science*. 2016 Apr 22;4(4):724.
163. Tatman PD, Muhonen EG, Wickers ST, **Gee AO**, Kim ES, Kim DH. Self-assembling peptides for stem cell and tissue engineering. *Biomaterials science*. 2016 Apr 22;4(4):543-54.
164. Telfer S, Erdemir A, Woodburn J, **Cavanagh PR**. Simplified versus geometrically accurate models of forefoot anatomy to predict plantar pressures: A finite element study. *Journal of biomechanics*. 2016 Jan 25;49(2):289-94.
165. Telleria J, Cotter R, Bompadre V, **Steinman S**. Laboratory Predictors for Risk of Revision Surgery in Pediatric Septic Arthritis. *Journal of Children's Orthopedics*. 2016 Accepted for publication in April 2016.
166. Telleria JJ, **Barei DP**, **Nork SE**. Coronal Plane Small-Fragment Fixation in Supracondylar Intercondylar Femur Fractures. *Orthopedics*. 2016 Jan 1;39(1):e134-9.
167. Vilela MD, Kim LJ, **Bellabarba C**, **Bransford RJ**. Blunt cerebrovascular injuries in association with craniocervical distraction injuries: a retrospective review of consecutive cases. *Spine J*. 2015 Mar 1;15(3):499-505.
168. Walker BJ, **Schmale GA**, McCreary F, McFadyen JG, Bompadre V, Flack SH, Bosenberg AT. Regional anesthesia for anterior cruciate ligament reconstruction in adolescents. *Paediatric anaesthesia*. 2016 Jun;26(6):668-9.
169. Wang H, Chen T, **Gee AO**, Hutchinson ID, Stoner K, Warren RF, Rodeo SA, Maher SA. Altered regional loading patterns on articular cartilage following meniscectomy are not fully restored by autograft meniscal transplantation. *Osteoarthritis Cartilage*. 2015 Mar;23(3):462-8.
170. **Warne WJ**. CORR Insights(R): Open Surgical Treatment for Snapping Scapula Provides Durable Pain Relief, but so Does Nonsurgical Treatment. *Clin Orthop Relat Res*. 2016 Mar;474(3):806-7.
171. **Warne WJ**, **Hsu JE**. Definition of a "True" Periprosthetic Shoulder Infection Still Eludes Us. *J Bone Joint Surg Am*. 2015 Jul 15;97(14):e56.
172. Watson CJ, **Kwon RY**. Osteogenic programs during zebrafish fin regeneration. *BoneKEY reports*. 2015;4:745.
173. Watt AJ, Ching RP, **Huang JI**. Biomechanical evaluation of metacarpal fracture fixation: application of a 90 degrees internal fixation model. *Hand (N Y)*. 2015 Mar;10(1):94-9.
174. Westrick E, Hamilton B, Toogood P, Henley B, **Firoozabadi R**. Humeral shaft fractures: results of operative and non-operative treatment. *Int Orthop*. 2016 May 6.
175. **White KK**, Bompadre V, **Goldberg MJ**, Bober MB, Campbell JW, Cho TJ, Hoover-Fong J, Mackenzie W, Parnell SE, Raggio C, Rapoport DM, Spencer SA, Savarirayan R. Best practices in the evaluation and treatment of foramen magnum stenosis in achondroplasia during infancy. *American journal of medical genetics Part A*. 2016 Jan;170(1):42-51.
176. **White KK**, Parnell SE, Kifle Y, Blackledge M, Bompadre V. Is there a correlation between sleep disordered breathing and foramen magnum stenosis in children with achondroplasia? *American journal of medical genetics Part A*. 2016 Jan;170(1):32-41.
177. **White KK**, Savarirayan R, Goldberg MJ, MacKenzie W, Bompadre V, Bober MB, Cho TJ, Hoover-Fong J, Parnell SE, Raggio C, Spencer SA, Campbell JW, Rapoport DM, Kifle Y, Blackledge M. Response: "Best practices in the evaluation and treatment of foramen magnum stenosis in achondroplasia during infancy" and "is there a correlation between sleep disordered breathing and foramen magnum stenosis in children with achondroplasia?". *American journal of medical genetics Part A*. 2016 Apr;170(4):1101-3.
178. Williams ED, Stebbins MJ, **Cavanagh PR**, Haynor DR, Chu B, Fassbind MJ, Isvilanonda V, Ledoux WR. The design and validation of a magnetic resonance imaging-compatible device for obtaining mechanical properties of plantar soft tissue via gated acquisition. *Proceedings of the Institution of Mechanical Engineers Part H, Journal of engineering in medicine*. 2015 Oct;229(10):732-42.
179. Williams JR, Little MT, Kramer PA, **Benirschke SK**. Incidence of Preoperative Deep Venous Thrombosis in Isolated Calcaneal Fractures. *J Orthop Trauma*. 2016 Feb 24.
180. Williams JR, Wegner NJ, **Sangeorzan BJ**, **Brage ME**. Intraoperative and perioperative complications during revision arthroplasty for salvage of a failed total ankle arthroplasty. *Foot Ankle Int*. 2015 Feb;36(2):135-42.
181. Wongworawat MD, Dobbs MB, Gebhardt MC, Gioe TJ, **Leopold SS**, **Manner PA**, Rimnac CM, Porcher R. Editorial: Estimating survivorship in the face of competing risks. *Clin Orthop Relat Res*. 2015 Apr;473(4):1173-6.
182. Wyatt AR, 2nd, Porrino J, Shah S, **Hsu JE**. Irreducible superolateral dislocation of the glenohumeral joint. *Skeletal Radiol*. 2015 Sep;44(9):1387-91.

Alumni

In appreciation of the generous support over the years from the University of Washington Orthopaedic Alumni to fund Orthopaedic Resident Research and Education

1952

Park W. Gloyd, MD ★

1954

Trygve Forland, MD ★

1955

Robert W. Florence, MD

1956

J. Michael Eggin, MD ★
John E. Goeckler, MD
Robert L. Romano, MD ★

1957

John H. Aberle, MD ★★
John R. Beebe, MD

1958

Harry H. Kretzler, Jr., MD ★
James R. Friend, MD ★
Kenneth L. Martin, MD ★
Samuel L. Clifford, MD

1959

James W. Tupper, MD

1960

Irving Tobin, MD ★
William V. Smith, MD ★

1961

Robert C. Colburn, MD ★

1962

Arthur Ratcliffe, MD
Marr P. Mullen, MD ★★★★★

1963

Alfred I. Blue, MD
Robert A. Kraft, MD

1964

David E. Karges, MD ★★★★★
Harold J. Forney, MD ★★
Theodore K. Greenlee II, MD
★★★★★★
Thomas E. Soderberg, MD

1966

F. Richard Convery, MD ★
Joseph S. Mezistrano, MD ★
William A. Reilly, Jr., MD

1967

Ivar W. Birkeland, MD ★★
J. Conrad Clifford, MD ★
Robert F. Smith, MD ★★★★★

1968

Lynn T. Staheli, MD ★
Stewart M. Scham, MD ★★
William T. Thieme, MD ★★

1969

Edward E. Almquist, MD ★★★★★
Edward L. Lester, MD ★
Hugh E. Toomey, MD ★★
Sigvard T. Hansen, Jr., MD
★★★★★★

1970

John C. Brown, MD ★★
John M. Coletti, Jr., MD ★
Malcolm B. Madenwald, MD ★★
Michael T. Phillips, MD ★
Robert D. Schrock, Jr., MD

1971

Bruce E. Bradley, Jr., MD ★
Franklin G. Alvine, MD ★★★★★
Jerome H. Zechmann, MD
Louis A. Roser, MD ★
Nils Fauchald, Jr., MD

1972

David J. LaGasse, MD ★
David R. Nank, MD ★★
Donald D. Hubbard, MD ★
John A. Neufeld, MD ★★
Thomas L. Gritzka, MD ★

1973

Frederick J. Davis, MD ★★
Larry D. Hull, MD ★
Robert P. Watkins, Jr., MD ★
Theodore A. Wagner, MD ★★★★★

1974

Richard A. Dimond, MD ★★★★★★
Ronald B.H. Sandler, MD ★★★★★
Samuel R. Baker, MD ★★★★★
Robert A. Winquist, MD ★★★★★★

1975

Donald L. Plowman, MD ★★★★★
Frederick A. Matsen III, MD
★★★★★★
Gunter Knittel, MD
Larry R. Pedegana, MD ★★
Thomas M. Green, MD ★★★★★★
William M. Backlund, MD, PS ★

1976

Douglas K. Kehl, MD
Douglas T. Davidson III, MD ★
John F. Burns, MD ★
Peter Melcher, MD
Richard A. Zorn, MD ★

1977

Carl A. Andrews, MD ★
Geoffrey W. Sheridan, MD ★★
Larry D. Iversen, MD ★
Mark C. Olson, MD ★★
Steven T. Bramwell, MD

1978

Arnold G. Peterson, MD ★★★★★
Gary J. Clancey, MD ★★★★★
John W. Brantigan, MD
Richard S. Westbrook, MD ★★
Robert J. Strukel, MD
William Oppenheim, MD ★★

1979

Allan W. Bach, MD ★★★★★★
Gregory M. Engel, MD ★★
Jonathan L. Knight, MD ★★
Richard L. Semon, MD ★★★★★

1980

Carol C. Teitz, MD ★★★★★
Douglas G. Norquist, MD ★
John M. Hendrickson, MD ★★
Michael A. Sousa, MD ★★★★★★
Stuart R. Hutchinson, MD ★

1981

Dennis J. Kvidera, MD ★
 John M. Clark, Jr., MD, PhD ★★ ★★
 Martin S. Tullus, MD ★★ ★★ ★★
 Robert G. Veith, MD ★★ ★★ ★★

1982

John L. Thayer, MD ★★ ★★ ★★
 Richard M. Kirby, MD ★★ ★★ ★★ ★★
 Steven S. Ratcliffe, MD ★★ ★★ ★★
 William D. Burman, MD

1983

Elizabeth Anne Ouellette, MD ★★ ★★
 Edward L. Farrar III, MD ★★ ★★ ★★ ★★
 Henry K. Yee, MD ★
 Joseph D. Zuckerman, MD
 ★★ ★★ ★★ ★★
 Keith A. Mayo, MD ★★ ★★ ★★ ★★ ★★
 Robert M. Berry, MD ★★ ★★ ★★

1984

Jeffrey C. Parker, MD ★
 Jeffrey W. Akeson, MD ★★ ★★ ★★
 Kevin P. Schoenfelder, MD ★
 Marc F. Swiontkowski, MD
 ★★ ★★ ★★ ★★
 Thomas J. Fischer, MD ★★ ★★ ★★ ★★

1985

Daniel L. Flugstad, MD ★★ ★★ ★★
 Jeffrey N. Hansen, MD ★★ ★★ ★★
 Paul J. Abbott, MD ★★ ★★ ★★
 Richard J. Barry, MD ★★ ★★
 William P. Barrett, MD ★★ ★★ ★★ ★★

1986

Carleton A. Keck, Jr., MD ★★ ★★ ★★
 Gary Bergman, MD ★★ ★★ ★★ ★★
 Lawrence E. Holland, MD ★★ ★★
 Michael E. Morris, MD ★★ ★★ ★★

1987

Craig T. Arntz, MD ★★ ★★ ★★
 Herbert R. Clark, MD ★★ ★★ ★★
 Michael K. Gannon, MD ★★ ★★
 Steven L. Reed, MD ★

1988

Jonathan L. Franklin, MD ★★ ★★ ★★ ★★
 Michael A. Thorpe, MD ★★ ★★ ★★ ★★
 Richard V. Williamson, MD ★

1989

James P. Crutcher, MD ★★ ★★ ★★
 Lawrence V. Page, DO ★★ ★★ ★★
 Martin G. Mankey, MD ★★ ★★ ★★ ★★
 Nancy J. Ensley, MD
 Steve C. Thomas, MD ★★ ★★ ★★ ★★

1990

David M. Kieras, MD ★
 J. Roberto R. Carreon, MD
 Jay A. Winzenried, MD ★★ ★★ ★★
 Ken Fujii, MD ★
 Walter F. Krengel III, MD ★★ ★★ ★★

1991

David H. Bishop, MD ★★ ★★
 Kit M. Song, MD
 Mark Remington, MD ★★ ★★ ★★
 Mark E. Murphy, MD, PhD ★★ ★★ ★★
 Tim P. Lovell, MD ★★ ★★

1992

Curt Rodin, MD
 Don Striplin, MD ★★ ★★
 Eli Powell, MD ★
 Jeff Stickney, MD ★★ ★★ ★★
 John D. West, MD ★★ ★★
 Michael Sailer, MD ★★ ★★ ★★

1993

J. Eric Vanderhooft, MD ★★ ★★ ★★
 Lyle S. Sorensen, MD ★★ ★★ ★★ ★★
 Philip J. Kregor, MD ★★ ★★
 Susan R. Cero, MD ★★ ★★ ★★ ★★

1994

Brodie Wood, MD ★★ ★★ ★★ ★★
 Eric Bowton, MD ★★ ★★
 Jim Vahey, MD ★
 Sohail K. Mirza, MD ★★ ★★ ★★
 William Obrebskey, MD ★★ ★★ ★★ ★★

1995

Ron Kristensen, MD ★★ ★★ ★★
 Scott Hormel, MD ★★ ★★ ★★
 Timothy Beals, MD ★★ ★★ ★★
 Todd Clarke, MD ★★ ★★ ★★
 William J. Mills III, MD ★★ ★★ ★★

1996

David Deneka, MD ★★ ★★ ★★
 Peter Mitchell, MD ★★ ★★ ★★
 Peter T. Simonian, MD ★★ ★★ ★★ ★★
 Vernon Cooley, MD ★★ ★★ ★★
 William Wagner, MD ★★ ★★ ★★

1997

Daniel Stechschulte, Jr., MD, PhD
 ★★ ★★ ★★ ★★
 David Levinsohn, MD ★★ ★★
 L. Anthony Agtarap, MD ★★ ★★
 Mohammad Diab, MD
 Randall W. Viola, MD

1998

Colin Poole, MD ★★ ★★
 David Belfie, MD ★
 Don Ericksen, MD ★★ ★★ ★★ ★★
 Jay Crary, MD ★★ ★★ ★★ ★★
 Oriente DiTano, MD ★★ ★★

1999

Craig Boatright, MD
 Jeffrey Garr, MD ★
 John Michelotti, MD ★★ ★★
 Julie A. Switzer, MD ★
 Thomas D. Chi, MD ★★ ★★

2000

Brett Quigley, MD ★★ ★★
 Cara Beth Lee, MD ★★ ★★
 Daniel Jones, MD ★
 Joel Hoekema, MD ★★ ★★ ★★
 Patrick McNair, MD

2001

Eric Novack, MD
 Frederick Huang, MD ★★ ★★ ★★
 Matthew Camuso, MD
 Michael Metcalf, MD ★★ ★★ ★★
 Richard Bransford, MD ★

2002

Timothy DuMontier, MD ★★ ★★
 Scott Hacker, MD ★
 Timothy Rapp, MD ★
 William Sims, MD ★
 Carla Smith, MD ★★ ★★

2003

Ben DuBois, MD ★★ ★★ ★★
 Andy Howlett, MD ★
 Guy Schmidt, MD ★★ ★★
 Brian Shafer, MD ★
 Emma Woodhouse, MD ★

2004

Jon Braman, MD ★
 Alexis Falicov, MD ★
 Mike McAdam, MD ★★ ★★
 Jason H. Thompson, MD ★★ ★★
 Thea W. Khan-Farooqi, MD

2005

Anthony Buoncristiani, MD ★
 Waqqar Khan-Farooqi, MD
 Wren McCallister, MD
 Timothy O'Mara, MD ★★ ★★
 David W. Stevens, MD ★

2006

Heidi Shors, MD ★★
 Stacey Donion, MD
 Eric Klineberg, MD ★
 Bill Montgomery, MD ★
 Mel Wahl, MD ★
 Burt Yaszay, MD ★

2007

Jamie Antoine, MD ★★
 Jeremiah Clinton, MD ★
 Mary Cunningham, MD ★
 Evan Ellis, MD ★
 Joseph Lynch, MD ★
 Allison MacLennan, MD ★

2008

Drew Fehsenfeld, MD ★★
 Mark Freeborn, MD ★★★★★
 Christopher Howe, MD ★
 John Howlett, MD ★
 Michael Lee, MD ★
 Gregg Nicandri, MD ★★

2009

Rajshri Maheshwari Bolson, MD ★
 Jason King, MD ★
 Annie Links, MD ★
 Soren Olson, MD ★
 Karen Perser, MD ★★
 Scott Ruhlman, MD ★
 Addison Stone, MD ★
 Jason Wilcox, MD ★

2010

Sean Amann, MD ★
 Jeremy Bauer, MD ★
 Aric Christal, MD ★
 Wendy Emerson, MD ★
 Michael Hwang, MD ★
 Lee Pace, MD ★
 Christopher Wolf, MD ★
 Vinko Zlomislic, MD ★

2011

Aaron Chamberlain, MD ★
 Brian Daines, MD ★
 Cory Lamblin, MD ★
 Edward Moon, MD ★
 Derek Rains, MD ★
 Peter Scheffel, MD ★
 Christian Sybrowsky, MD ★
 Brett Wiater, MD ★

2012

Benjamin Amis, MD ★
 Adam Bakker, MD ★
 Gregory Blaisdell, MD ★
 Joshua Lindsey, MD ★
 Grant Lohse, MD ★
 Matthew Lyons, MD ★
 Andrew Merritt, MD ★
 Nels Sampatacos, MD ★

2013

Kyle Chun, MD ★
 Elizabeth Dailey, MD
 Andrew Ghatan, MD ★
 Brian Gilmer, MD ★
 Jennifer Hagen, MD
 Mark Miller, MD ★
 David Patterson, MD ★
 Emily Squyer, MD ★

2014

Sid Baucom, MD
 Nathan Coleman, MD
 Jacques Hacquebord, MD
 Nicholas Iannuzzi, MD ★
 Paul Kim, MD
 Ted Sousa, MD
 Nicholas Wegner, MD
 David Zeltser, MD ★

2015

Timothy Alton, MD
 Kenneth Gundle, MD
 Daniel Holtzman, MD ★
 Amanda Roof Larson, MD ★
 Paige Mallette, MD
 Courtney O'Donnell, MD
 Daniel Patton, MD ★
 Laura Stoll, MD ★

2016

Todd Blumberg, MD
 Akash Gupta, MD
 Sean Haloman, MD
 Emily Harnden, MD
 Clifford Hou, MD
 Dayne Mickelson, MD
 Jessica Telleria, MD

STARS INDICATE TOTAL DONATIONS IN SUPPORT OF THE RESIDENCY

★★★★★★ = \$20,000 and above
 ★★★★★ = \$15,000 - \$19,999
 ★★★★★ = \$10,000 - \$14,999
 ★★★★★ = \$7,500 - \$9,999
 ★★★ = \$5,000 - \$7,499
 ★★ = \$2,500 - \$4,999
 ★ = \$1 - \$2,499

Endowments

We express our appreciation to all who have contributed to the endowments of the Department of Orthopaedics and Sports Medicine. This assistance makes possible special research activities, educational programs, and other projects that we could not offer without this extra support from our alumni, faculty, and friends in the community. In this day and age of funding cutbacks and decreased returns on investment, an endowment in the University of Washington continues to provide above market returns and is a crucial way to support advancement of musculoskeletal medicine. If you have any questions, please contact our Chair, Howard A. Chansky, MD (chansky@uw.edu), or our Director, Ken Karbowski (kkarb@uw.edu). Thank You!

Ernest M. Burgess Endowed Chair for Orthopaedics Investigation - David R. Eyre, PhD

Sigvard T. Hansen Jr. Endowed Chair in Orthopaedic Traumatology - Ted S. Gross, PhD

Jerome H. Debs II Endowed Chair in Orthopaedic Traumatology -
Stephen K. Benirschke, MD

Bob and Sally Behnke Endowed Chair for the Health of the Student Athlete -
John W. O'Kane, MD

Endowed Chair for Women's Sports Medicine and Lifetime Fitness -
Peter R. Cavanagh, PhD, DSc

Hansjörg Wyss Endowed Chair

Surgical Dynamics Endowed Chair for Spine Research

Douglas T. Harryman II/DePuy Endowed Chair for Shoulder Research -
Frederick A. Matsen III, MD

Synthes Spinal Surgery Outcomes Research Endowed Fund

Fracture Fixation Biology Endowed Professorship

Ostex Bone and Joint Research Endowment

Orthopaedic Traumatology Endowed Lectureship

John F. LeCocq Lectureship in Orthopaedic Surgery

Don and Carol James Research Fund in Sports Medicine and Fitness

Victor H. Frankel Endowed Award

Endowments

Esther Whiting Award

Edwin L. Larnen, MD Award

Spine Research Endowment

James G. Garrick Endowed Lectureship in Sports Medicine

Allan Treuer - Ted Wagner, MD Endowed Chair in Regenerative Spine Surgery

Richard and Betsy Kirby Orthopaedic Resident Endowed Fund

Huang-Biu Orthopaedic Resident Endowed Support Fund

Orthopaedic Resident Endowed Support Fund

Josh and Max Myers Endowed Orthopaedic Fellowship Fund

Sarcoma Oncology Endowed Fund

Clawson Family Orthopaedic Library Endowed Fund

Kathryn E. Cramer Endowed Orthopaedics Research Fund

Evelyn E. Carman Endowed Research Fund in Women's Sports Medicine and Lifetime
Fitness

Alan J. Fraser Endowed Research Fund

Index

A

Agel, Julie
22,91,93,94
Ahsan, Zahab
18,20,90
Allan, Christopher
1,2,3,13,24,89,90,91,93,94,95
Alton, Timothy
86,90,91,92,99
Alvine, Franklin
7,97
Arce, Amy
80
Archer, Marilyn
29

B

Bagby, George
62
Bain, Steven
3,13,88,89,90,95
Baker, Samuel
65,66,97
Barei, David
13,88,89,91,95,96
Baron, Matthew
18,20
Bayomy, Ahmad
18
Behnke, Bob
100
Behnke, Sally
100
Beingessner, Daphne
13,19,91
Bellabarba, Carlo
1,13,22,60,72,89,90,92,94,95,
96
Bellevue, Kate
18,20
Benirschke, Stephen
13,90,93,95,96,100
Beshlian, Sarah
13,77
Blumberg, Todd
1,18,82,90,99
Bompadre, Viviana
76,90,92,94,95,96
Bouchard, Maryse
13,74,92
Brage, Michael
13,91,92,94,96
Bransford, Richard
13,88,89,90,92,94,95,96,98
Bremjit, Prashoban
18,84
Bringe, Kariline
18

Bryant, Lyra
81
Burgess, Ernest
100
Burton, Monique
18,74
Byrnes, Thomas
18,84

C

Carman, Evelyn
101
Casowitz, Steve
81
Cavanagh, Peter
11,13,88,89,90,93,94,95,96,
100
Chansky, Howard
1,3,13,19,22,35,53,56,78,80,
88,89,100
Chaplin, David
6
Chapman, Theresa
74
Christman-Skieller, Claudia
18,20
Clawson, D. Kay
4,5,7,101
Clawson, Robert
14,77,79,101
Conrad, Ernest
14,76,77,90,94,95
Cramer, Kathryn
101
Cruz, Leo
80

D

Daines, Brian
67,68,99
Dales, Mark
14,75,76
Davidson, Darin
14,22,77,91
Davies, Jonah
71
Debs, Jerome
100
DesEnfants, Laura
18,79
Dinsmore, Anne
81
Domes, Christopher
18,22
Done, Stephen
74
Dunbar, Robert
14,88,91
Dupuy, Randy
81

E

Earl, Dawn
74
Egermann, Marcus
22
Ehni, William
79
Eyre, David
8,14,27,29,88,91,92,94,100

F

Fall, Brent
24
Fernandes, Russell
14,27,94
Fernando, Navin
14,22,53,56,77,93
Firoozabadi, Reza
3,14,72,88,89,90,91,94,95,96
Folchert, Matthew
18,84
Frankel, Victor
100
Fraser, Alan
101
Funovics, Philipp
22

G

Gardiner, Edith
3,14,88,95
Garner, Matthew
86
Garrick, James
101
Gee, Albert
1,3,14,35,48,69,70,78,81,89,
90,92,94,95,96
German, Katherine
81
Gibly, Romie
18
Gilmer, Brian
67,68,91,99
Githens, Michael
71,86,91
Glass, Ian
74
Glassman, David
86
Goldberg, Michael
14,74,76,91,96
Gorbaty, Jacob
41,50,91,95
Green, John
15,78,95
Gross, Ted
3,15,88,90,95,100
Gupta, Akash
18,22,82,92,95,99

H

Hale, Susan
74
Haller, Justin
86,91
Haloman, Sean
18,82,99
Hanel, Douglas
15,47,72,89,91,92,93
Hansen, Sigvard
4,5,15,91,97,100
Harnden, Emily
18,82,90,91,99
Harris, Matthew
31,34
Harryman, Douglas
9,100
Henley, M. Bradford
15,72,94,96
Higbee, Dustin
81
Holder, Ursula
24
Hou, Clifford
18,83,92,99
Hsu, Jason
3,15,39,41,48,50,77,81,90,92,
94,95,96
Huang, Fred
81
Huang, Jerry
15,47,77,80,88,89,90,92,93,
94,95,96
Hudson, David
8,15,29,92
Hug, Kevin
18,92

I

Iannuzzi, Nicholas
8,15,80,99
Ibrahim, David
18
Iversen, Larry
4,97

J

Jaeger, Ashley
24
James, Carol
100
James, Don
100
Jayaswal, Arvind
63,64
Jenkins, Patrick
70

K

Karbowsky, Ken
100
Kark, Jonathan
18,20

Katzenmeyer, Amy
81
Kennedy, Colin
18,43,47
Kennedy, Stephen
1,2,3,15,43,77,79,92,95
King, Brandon
86
King, Graham
19,20
King, Kevin
69
Kirby, Betsy
101
Kirby, Richard
98,101
Klein, Mark
60
Kleweno, Conor
3,15,88,91
Kovalenko, Boris
18,84
Krengel, Walter
15,76,93,95,98
Kweon, Christopher
9,16,69,70,78
Kwon, Ronald
3,16,31,34,88,95,96

L

Larson, Amanda Roof
67,99
Lauder, Alexander
18,43,92,93,94
Laurien, Edwin
101
LeCocq, John
19,20,100
Ledoux, William
18,80,96
Leopold, Seth
16,77,90,91,93,94,96
Lindberg, Antoinette
16,76,77,95
Links, Annie
67,99
Little, Andrew
74
Lostoski, Cindy
81
Lucas, Robert
48,50,91,92,94

M

Magnusson, Erik
18,20
Manio, Monette
81
Manner, Paul
16,77,89,90,91,96
Manske, Mary Claire
43,86

Matsen, Frederick
16,39,41,48,50,77,91,92,94,
97,100
McAlinden, Audrey
27,28
McCornack, John
35
Meyer, Lauren
18,20
Michnick, Stuart
18
Mickelson, Dayne
18,83,91,99
Miozzari, Hermes Howard
22
Monstad-Rios, Adrian
34
Moon, Randall
24
Moore, Katie
18,78,79
Mosca, Vincent
16,76,90,92,94,95
Mowery, Carol
16
Myers, Josh
101
Myers, Max
101

N

Neme, Santiago
79
Neradilek, Moni Blazej
48,94
Ness, Kathryn
74,92
Nork, Sean
16,88,91,95,96

O

O'Brien, Adam
18,20
O'Kane, John
18,100
Olivo, Janice
18,78

P

Pangrazzi, Garrett
86
Parnell, Shawn
74,92,96
Patthanacharoenphon, Cameron
86
Perez, Joel
81
Petrie, Timothy
24
Pirolo, Joseph
86
Pittman, Jason
86

Pouliot, Michael
86
Pribaz, Jonathan
43

R

Rafi, Renato
81
Rai, Jyoti
29,92,94
Ramsey, Robert
81
Rendich, Rodolfo Zamora
87
Rosse, Cornelius
4
Ross, John
69,70
Russ, Stacy
50,94

S

Sagi, H. Claude
10,16,20,90
Sangeorzan, Adam
18
Sangeorzan, Bruce
3,16,72,80,88,89,94,95,96
Sassoon, Adam
1,2,3,16,22,53,56,77,79,91,93,
95
Sayegh, Eli
18,85
Scheidigger, Rob
69
Schiffman, Brett
18,85
Schlepp, Calvin
1,18,61,62,91
Schmale, Gregory
17,67,68,76,95,96
Seddon, H.J.
4
Service, Ben
87
Sethi, Rajiv
63,64
Smith, Douglas
17,94,95
Smith, Robert
4,97
Somerson, Jeremy
87,92,95
Spina, Nicholas
11,17
Squyer, Emily
67,99
Srinivasan, Sundar
3,17,88,95
Stancil, Ryan
53,56
Steinman, Suzanne
17,74,76,90,96

Stoick-Cooper, Cristi
24
Stolov, Walter
4
Sullivan, Matthew
87
Summers, Nathan
18,53,56
Swenson, Alan
18,91

T

Taitsman, Lisa
3,17
Tang, Anna
39
Tarabdkar, Neil
18,22
Teitz, Carol
5,17,97
Telfer, Scott
3,11,17,96
Telleria, Jessica
18,83,96,99
Testa, Annette
81
Teteak, Colin
24
Thayer, Mary Kate
18
Tipton, Cody
18,85
Treuer, Allan
101

V

Vogeli, Kevin
87

W

Wagner, Theodore
6,7,17,60,61,62,66,78,97,101
Wallace, Sara
18
Wallace, Stephanie
74
Warme, Winston
17,77,78,88,89,90,91,92,94,96
Weis, MaryAnn
29,30,91,92,94
White, Klane
17,74,76,92,93,94,95,96
Whiting, Esther
101
Whitney, Ian
41,94
Williams, Amy
87
Worton, Leah
18,88
Wu, Jiann-Jiu
17,27,29,88
Wyss, Hansjörg
100

Y

Yanamadala, Vijay
63,64
Yandow, Suzanne
1,18,73,76
Yang, Liu
12,18,35,37,80
Yi, Anthony
18,85

Z

Zhang, Fangyi
18,60
Zhou, Andy
24
Zhou, Haitao
71,72,87
Ziaei, Akbar
77
Zilkens, Christoph
22
Zura, Robert
21